



**Sero-Evidence of Infectious Bursal Disease  
Transmission between Quail  
(*Coturnix coturnix japonica*) and Chicken  
(*Gallus gallus domesticus*)**

SONFADA, M.L.<sup>1</sup>, EL-YUGUDA, A.A.<sup>2</sup>, GULANI, I.<sup>3</sup>, RABO, J.S.<sup>4</sup>, HENA, S.A.<sup>1</sup> and DANMAIGORO, A.<sup>1</sup>

<sup>1</sup>Department of Veterinary Anatomy, Faculty of Veterinary Medicine, Usmanu Danfodiyo University, Sokoto, Nigeria. <sup>2</sup>Department of Veterinary Microbiology, Faculty of Veterinary Medicine, University of Maiduguri, Maiduguri, Nigeria. <sup>3</sup>Department of Veterinary Medicine, Faculty of Veterinary Medicine, University of Maiduguri, Maiduguri, Nigeria. <sup>4</sup>Department of Veterinary Pathology, Faculty of Veterinary Medicine, University of Agriculture, Makurdi, Nigeria. \*Corresponding author: [sonfada@yahoo.com](mailto:sonfada@yahoo.com)  
Tel: +2348035073492

**ABSTRACT**

This study was carried out to determine possibility of infectious bursal disease transmission between quail and chicken. In the study, non vaccinated cockerel chicks were put together with infectious bursal disease viral inoculated quails sharing the same feeders and drinkers. The two bird groups were monitored and observed for symptoms and clinical signs of infectious bursal disease (IBD). There was no clinical sign observed however, a strong positive serological evidence of IBD infection from the test result. In this work the chickens mixed with unexposed quail did not show any clinical sign of the disease (IBD) or any sign of infection serologically. As shown in this study serological means of diagnosis is one of the simple and accurate diagnostic procedures which can not only yield quick result but may even detect a subclinical infection among birds, which may ultimately lead to timely intervention in curtailing the disease spread.

**Keywords:** Sero-evidence, infectious bursal disease, quail; chicken.

**INTRODUCTION**

Chicken have a high potential of becoming a significant sources of income and self sufficiency in meat production in many developing countries (Akoma and Baba, 1995; Adene, 1997; Okoye *et al.*, 1999). The Japanese quail is a small avian species kept for meat and egg production (Minvielle, 1998; Baumgartner, 1994). It is widely being used as a model in research in a variety of disciplines including physiology, nutrition, endocrinology, pathology, embryology, reproduction and immunology (Tilgar *et al.*, 2008; Vatsalya and Arora, 2011).

Infectious Bursal Disease (IBD) is a highly contagious immunosuppressive disease (Kasanga *et al.*, 2008). Chickens between 3 and 6 weeks of age are most susceptible to IBD virus (Kenton, 2008). The disease was first described in 1962 by Cosgrove (Cosgrove, 1962).

The economic losses resulting from infectious diseases such as IBD include not only the heavy mortalities but also the immunosuppression precipitated by damage to the bursa of Fabricius in survivors and sub-clinically infected birds which result in increased susceptibility to other diseases (Akoma and Baba, 1995; Kataria *et al.*, 1998; Oyeduntan and Durojaiye, 1999). Though, Japanese quails are fairly resistant to diseases and also show strong resistance to IBD viral infection (Haruna *et al.*, 1997; Whyte *et*

*al.*, 1999; Sonfada *et al.*, 2014), the bird could serve as a reservoir of some disease.

As one of the measures aiming at the control of infectious bursal disease, various methods have been developed for its diagnosis such as virus isolation in cell culture, embryonated chicken eggs, or young specific-pathogen-free (SPF) chickens and localization of the virus in infected tissues by electron microscopy, fluorescence assay, antigen-capture enzyme-linked immunosorbent assay (ELISA), or immunohistochemistry. All these methods may have disadvantages, such as being time consuming, labor intensive, expensive, or nonspecific (Barlic-Maganja *et al.*, 2002). It is thus of importance to establish serological evidence of the transmission or infectivity of the disease among chickens and quails as they are commonly raised either together or in close association with each other by some peasant farmers in Nigeria.

#### **MATERIALS and METHODS**

One hundred and fifty (150) day-old, non-vaccinated quail chicks were obtained from a hatchery at Maiduguri, Borno State. Chickens and quails were bought and managed on deep litter system. Two 100-watt electric bulbs and additional four bush lamps were used alternatively to provide warmth to the birds. The birds were fed *ad libitum*; they were fed with broiler starter from Sander's Company (ChickMash<sup>®</sup>, Sander's Company) for 5 weeks thereafter grower's mash from the same company was fed.

The quail chicks were raised for two weeks during which six (6) were lost due to management factors, the remaining birds were then divided into two groups (group A and B) with group A having 70 birds and B having 74 birds, these birds were kept separately in different pens, located farther apart.

The group B birds were inoculated per os using a Pasteur pipette, by giving them two drops (0.1ml) of infectious bursal disease viral antigen that was prepared by maceration of bursae from IBD diagnosed birds. The birds

were observed for 14 weeks; similarly those in group A were inoculated with two drops of phosphate buffered saline per os, and kept for 14 weeks. In order to test for contact infection, 20 four weeks old non vaccinated cockerel chicks were put together with IBD virus inoculated quails, sharing the same feeders and waterers. They were monitored and observed for symptoms and clinical signs for IBD.

At weekly interval, five birds were randomly sampled from each group (A and B) of the two species and weighed using a beam balance and sacrificed using halal method of slaughter (Anil *et al.*, 2004). The blood from each slaughtered bird was collected for serology.

Agar gel was prepared to carry out the Agar Gel Precipitin Test (AGPT). The central well was filled with the antigen (bursal homogenates) using pastuer pipette. One peripheral well was filled with drops of the test serum samples (one well to one test sample) using a single channel pipette. A similar procedure was adopted for the remaining group of wells. The plates were thereafter incubated in a tray for 24 – 48 hrs at room temperature under moist condition. A 60 watt light bulb was used to illuminate the petri dish in aiding the test to be read accurately. Positive samples showed precipitin lines and were seen between the samples and viral antigen wells. The intensity of reaction was recorded and interpreted following the standard technique outline by Hirai *et al.*, (1972) as:

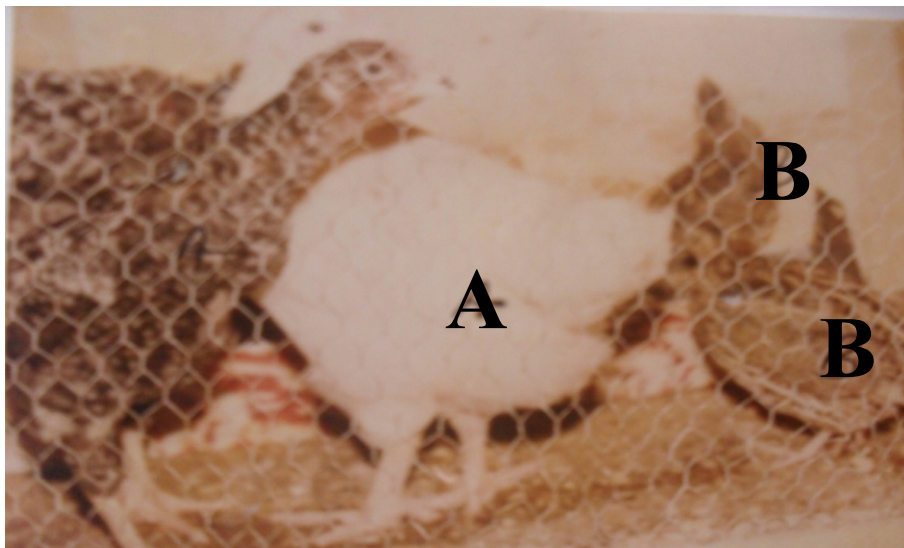
- 
- i. ve: no visible band or line of precipitin
- ii. +ve: faint, but recognizable diffused precipitin line
- iii. ++: distinct band of moderate opacity and varying width
- iv. +++: very opaque, of varying width.

## RESULTS

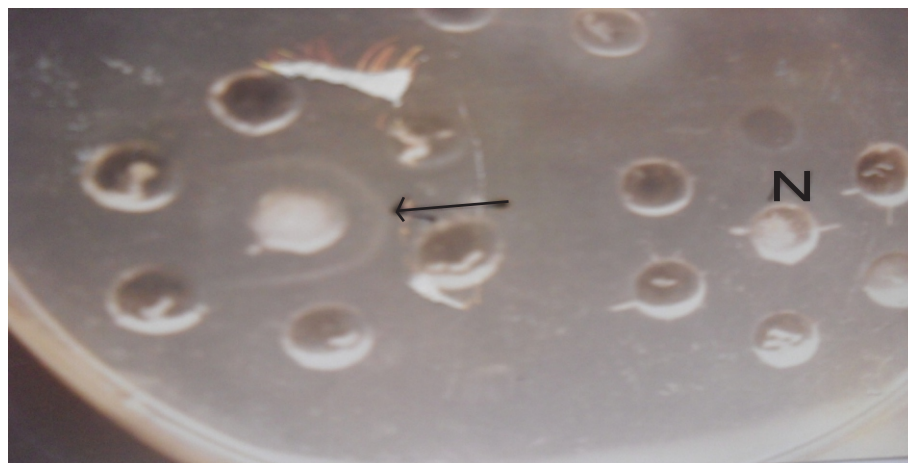
The results obtained in this work are as presented in the table and plates below.

**TABLE I: DISTRIBUTION OF PRECIPITIN ANTIBODIES AGAINST IBDV IN CHICKENS AND QUAILS**

Species	Number Tested	Number Positive (+ve)	Number Negative (ve)
Chickens	20	20	0
Quail	144	74	70

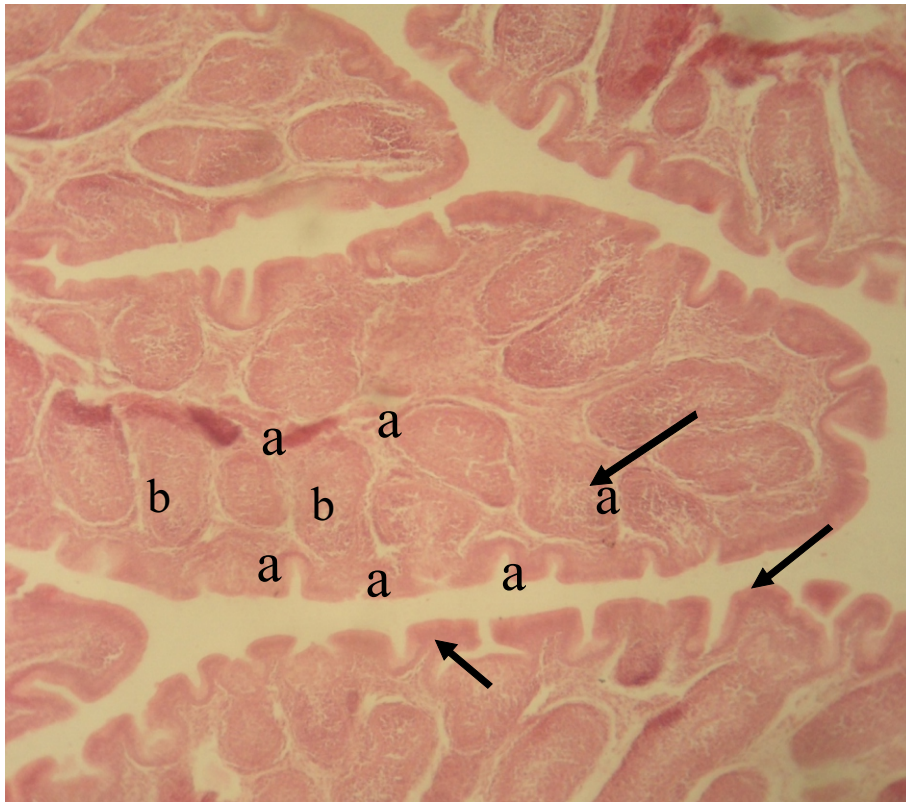


**Fig 1:** Infected quails (B) mixed with non-vaccinated, non infected chickens (A) x125.

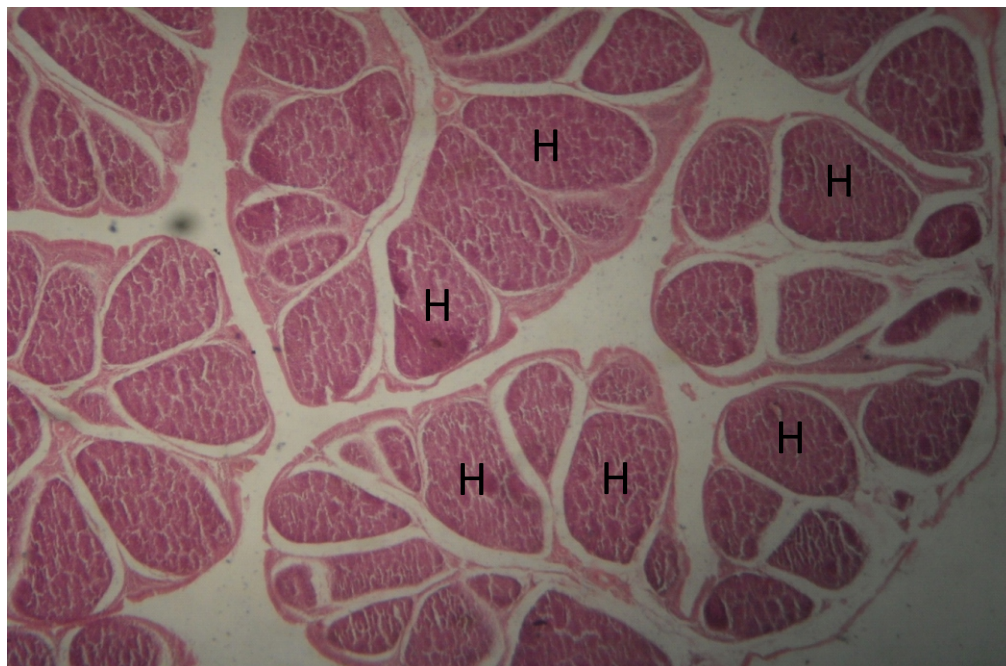


**Fig 2:** AGPT plate showing positive precipitin line (arrow) and negative wells (N) x125.

The chickens mixed with infected quail did not show any clinical sign of the disease (IBD) however, they were serologically positive for IBD. The precipitin line which indicates the positivity of the tested sera is shown in plate II, and in which the negative result is also shown. All the infected birds tested positive serologically. Histopathologically, the infected quail showed hyperplasia of the lymphocytes (Plate IV), while those of the infected chicken showed evidence of lymphocytolysis though slight (Plate III).



**Fig 3:** A chicken bursa of Fabricius showing increasing number and size of lymphoid follicles (a); less prominent connective tissue septae (b), and slight lymphocytolysis (arrow) H&E X 100.



**Fig 4:** Quail bursa showing: Follicular hyperplasia (H). H&E x100.

The infected quail did not show any clinical sign of the disease (IBD). Histologically, the bursa of Fabricius of the infected quail showed hyperplasia of the lymphoid follicles (Plate IV).

## DISCUSSION

The cross infection between the quails and the contact chicken showed a different disease pattern. There was no mortality experienced in the contact chickens through infected quails, because there are no clinical manifestation of the disease among the birds. However, they were all serologically strongly positive, as all the infected quails as well as cross-infected contact chickens reacted positively for the presence of infection as shown in the results. Haruna *et al.*, (1997) and Whyte *et al.*, (1999) observed that quails are fairly resistant to viral infection so there are less need for vaccination. The observation in this study is however in contrast.

Infectious bursal disease (IBD) is an acute contagious viral disease of young chickens (Kibenge *et al.*, 1988; Lasher and Shane, 1994). The aetiological agent, IBD virus (IBDV), has a predilection for the cells of the bursa of Fabricius where the virus infects actively dividing and differentiating lymphocytes of the B-cell lineage (Burkhardt and Muller, 1987). Increase in bursal size and weight as observed in this study coupled with lymphoid hyperplasia showed that the organ responded to the viral challenge. The IBD-virus destroys lymphocytes, primarily in the bursa of Fabricius, but also in other organs of the immune system, like the thymus, the spleen and the caecal tonsils. The result is a marked immune-suppressive effect, causing increased susceptibility to other diseases and impaired response to many vaccinations (Kataria *et al.*, 1998). Clinical and sub-clinical types of the disease may occur. However, in this study, none of these clinical signs were observed in both the infected quails and cross infected chicken.

Because vaccination is the principal method of viral disease control in commercial poultry

worldwide (Lasher and Shane, 1994), IBDV is being considered as one of the most important viral pathogens of the commercial poultry industry and hence appropriate means of diagnosis and control of the disease should continue to be put into place. It has been discovered in the course of this work that serological means of diagnosis is one of the simple and accurate diagnostic procedures which can not only yield quick result but may even detect a subclinical infection among birds, which may ultimately lead to timely intervention in curtailing the disease spread. Above all the technique does not need sophisticated materials. In this work the chickens mixed with unexposed quail did not show any clinical sign of the disease (IBD) or any sign of infection serologically. Farmers are therefore advised strongly to vaccinate quails as well, so as to avoid circumstance of playing a role of reservoirhost thereby shedding the viral loads to other susceptible animals.

## REFERENCES

- ADENE, D.F. (1997): Diseases of poultry in Nigeria: An overview of the Problems and solutions. *Trop. Vet.* **15**:103-110.
- ANIL, M.H., YESILDERE, T., AKSU, H., MATUR, E., MCKINSTRY, J.L., ERDOGAN, O., HUGHES, S. and MASON, C. (2004): Comparison of religious slaughter of sheep with methods that include preslaughter stunning and the lack of differences in exsanguination, packed cell volume and quality parameters. *Animal Welfare* **13** (4):387-392.
- AKOMA, M.B. and BABA, S.S. (1995): Survey of infectious bursal disease virus Antibody in free-range and commercial birds in Borno State, Nigeria. *Studies and Research in Vet. Med.* **3**:46-48.
- BARLIC-MAGANJA, D., ZORMAN-ROJS, O. and GROM, J. (2002): Detection of infectious bursal disease virus in different lymphoid organs by single-step reverse transcription polymerase chain reaction and microplate hybridization assay. *J Vet Diagn Invest* **14**:243-246.

- BAUMGARTNER, J. (1994): Japanese quail production, breeding and genetics. *World Poult.Sci. J.* **50**:227-235.
- BURKHARDT, E. and MULLER, H. (1987): Susceptibility of chicken blood lymphoblasts and monocytes to infectious bursal disease virus (IBDV). *Arch Virol* **94**:297-303.
- HIRAI, K., SHIMAKURA, S. and HIRESE, M. (1972): Immunodiffusion reaction to avian infectious bursal disease virus. *Avian Diseases* **16**(4):911-964.
- KASANGA, C.J., YAMAGUCHI, T., WAMBURA, P.N., MUNANGANDU, H.M., OHYA, K. and FUKUSHI, H. (2008): Detection of infectious bursal disease virus (IBDV) genome in free-living pigeon and guinea fowl in Africa Suggests involvement of wild birds in the epidemiology of IBDV. *J. Virus Genes* **36**: 521-529.
- KATARIA, R.S., TIWARI, A.K., BANDYOPADHYAY, S.K., KATARIA, J.M. and BUTCHIAH, G. (1998): Detection of infectious bursal disease virus of poultry in clinical samples by RT-PCR. *Biochemistry and Molecular Biology International* **42**(2):315-322.
- KENTON, K. (2008): Infectious bursal disease IBD or Gumboro. Hy-Line Int. Dallas Center, Iowa. Cosgrove, S.D., 1962. An apparently new disease of chickens-avian nephrosis. *Avian Dis.*, **6**:385-389.
- KIBENGE, F.S.B., DHILLON, A.S. and RUSSEL, R.G. (1988): Biochemistry and immunology of infectious bursal disease virus. *J Gen Virol.* **69**: 1757- 1775.
- HARUNA, E.S., MUSA, U., LOMBIN, L.H., TAT, P.B., SHAMAKI, D., OKEWOLE, P.A. and MOLOKWU, J.U. (1997): Introduction of quail production in Nigeria. *Nigeria Veterinary Journal* **18**:104-107.
- LASHER, H.N. and SHANE, S.M. (1994): Infectious bursal disease. *World's Poultry Sci J* **50**:133-166.
- MINVIELLE, F. (1998): Genetic and breeding of Japanese quail for production around the world. Proc 6th Asian Pacific Poultry Congress, Nogaya, Japan. June, 4-7.
- NAGARAJAN, M.M. and KIBENGE, F.S.B. (1997): Infectious Bursal Disease Virus: A Review of Molecular Basis for Variations in Antigenicity and Virulence. *Can J Vet Res* **61**: 81-88.
- OKOYE, J.O.A., ABA-ADULUGBA, E.P., EZEOKONKWO, R.C., UDEM, S.C. and ORAJAKA, L.J.E. (1999): Susceptibility of local Nigerian and Exotic chickens to infectious bursal disease by contact exposure. *Tropical Animal Health Production* **31**:75-81.
- OYEDUNTAN, A.A. and DUROJAIYE, O.A. (1999): Newcastle Disease, Infectious Bursal Disease and EDS '76 Antibodies in Indigenous Nigerian Local Chickens. *Trop. Vet.* **17**:47-52.
- SONFADA, M.L., KWARI, H.D., RABO, J.S., WIAM, I.M. and HENA, S.A. (2014): observations on the quail's bursa of fabricius under normal and experimental infectious bursal disease conditions. *African Journal of Cellular Pathology* **2**(1):29-34.
- TILGAR, V., KILGAS, P., VIITAK, A. and REYNOLDS, S.J. (2008): The rate of bone mineralization in birds is directly related to alkaline phosphatase activity. *Physiol. Biochem. Zool.* **81**:106-111.
- VATSALYA, V. and ARORA, K.L. (2011): Association between body weight growth and selected physiological parameters in male Japanese quail (*Coturnix japonica*). *Int. J. Poult. Sci.* **10**:680-684.
- WHYTE, E.P., AHMED, Y., USMAN, M. and MOMOH, O.M. (1999): Importance and management of quail birds to Nigerian Agriculture. *Bulletin of Science Association of Nigeria* **22**:141-144.