



## Morphometric Study of the Skull of the Greater Cane Rat (*Thryonomys swinderianus*, Temmnick)

OLUDE, M.A.<sup>1,2</sup>, MUSTAPHA, O.A.<sup>1,2</sup>, SONUBI, A.C.<sup>1</sup>, FALADE, T.E.<sup>2</sup>, OGUNBUNMI, T.K.<sup>3</sup>,  
ADEBAYO, A.O.<sup>1,2</sup> and AKINLOYE, A.K.<sup>1</sup>

<sup>1</sup>Department of Veterinary Anatomy, College of Veterinary Medicine, Federal University of Agriculture, Abeokuta, Ogun State, Nigeria, <sup>2</sup>Department of Veterinary Anatomy, Faculty of Veterinary Medicine, University of Ibadan, Ibadan, Oyo State, Nigeria, <sup>3</sup>Department of Veterinary Surgery and Theriogenology, Faculty of Veterinary Medicine, University of Ibadan, Ibadan, Oyo State, Nigeria. \*Corresponding author Email: [drmustyplato@yahoo.co.uk](mailto:drmustyplato@yahoo.co.uk), Tel: +2348035915275

### SUMMARY

This study was designed to investigate some morphometric characteristics of the skull of the Greater cane rat (GCR) involving 30 morphometric parameters. A total of 10 adult GCR were used for this study comprising of both sexes (5 males and 5 females). Student t-test was used to analyze the values obtained and to determine differences between the sexes. Morphological features were found in the zygomatic bone which occurred as a large and thick bone on both ends. From 30 parameters analyzed, 12 were statistically significant ( $p \leq 0.05$ ) between both sexes, confirming the presence of sexual dimorphism in the skull of this rodent. This study provided baseline research data on the typology of the skull of the GCR.

**KEYWORDS:** Greater cane rat, morphometry, skull, sexual dimorphism, craniometry.

### INTRODUCTION

The Greater cane rat (GCR) (*Thryonomys swinderianus*), popularly known as grasscutter, is one of the wild rodents that is currently undergoing domestication and captive rearing in parts of Africa and is regarded as the continent's number one "micro-rodents" (Ajayi, 1974; Asibey and Addo, 2000). It belongs to the sub-order Hystricomorpha because they have their medial masseter muscles spread through the infra-orbital foramen while the lateral masseter muscles are attached to the zygomatic arches as in primitive rodents (Allaby, 1999). The GCR is sturdy-looking, with a stocky body and short brown, bristly, scaly tail; it measures up to 60 cm in length and 7.2 kg in weight (Onadoko, 1996). The body is covered by coarse, thick and pointed hair that varies in colour and can be of any shade between grayish and yellowish brown (Dorst and Dandelot, 1969). The GCR has received increasing attention from researchers who have documented works on the reproductive system (Adjanohoun, 1993; Adu and Yeboah, 2000; Addo et al., 2002; Addo, 2002; Adebayo et al., 2009; Adebayo and Olurode, 2010), urinary system (Olukole, 2009), circulatory system (Opara et al., 2006) and nervous system (Dwarika et al., 2008; Spruston, 2008; Byanet et al., 2009; Elston and Manger, 2014). In the past, morphological studies were restricted to

qualitative description of tissue structures and therefore, they are essentially subjective. In recent years, the applications of morphometric and stereological techniques have increased in biomedical research and have been well recognized as a new approach in morphological study (Mukerjee and Rajan, 2006). Morphometric studies particularly of the skull are very important in arthrology (Bokonyi, 1974), regional anaesthesiology (Olopade and Onwuka, 2005), taxonomy and comparative anatomy within and between breeds (Van der Merwe, 2007). In rodent taxonomy, morphometric analysis especially of the skulls has long been one of the fundamental techniques for characterizing, defining and discerning the identity of individual specimens (Olayemi, 2007; Bezerra and de Oliveira, 2010; Olayemi et al., 2012; Reisser et al., 2012). Since the head contains the brain, major sensory organs and the feeding apparatus, skull morphometry can also reveal a lot of information on the ontogeny, phylogeny and adaptation of rodents. Several morphometric studies of the skull have been documented in many domestic animals and rodents such as the dog, cat (Kunzelet al., 2003), pig (Endo et al., 2002), West African dwarf goat (Olopade, 2006), African giant rat (Olude et al., 2009). Skull morphometry is scarce in rodents undergoing captive rearing and domestication. Webb et al., (1979) sparsely described the morphology of the GCR skull and Van der Merwe (2007) reported the distinguishing features for differentiating the skulls of *Thryonomys swinderianus* and *Thryonomys gregorianus*. Little information exists however, on the detailed morphometry of the skull of the GCR. The present study, therefore seeks to document the morphometric data of various skull bone measurements in the GCR (*Thryonomys swinderianus*). The information obtained will essentially add to the ongoing attempts to understand the

biology of the GCR. It will also be useful to breeders, clinicians and researchers.

#### MATERIALS and METHODS

Investigation was carried out on 10 adult GCR (5 males and 5 females). The animals were purchased from Pavemgo grasscutter Farm at Badagry, Lagos State, Nigeria. Their live weights were recorded and examined to exclude skeletal deformities, after which they were anaesthetized using chloroform. The animals were then slaughtered and decapitated at the occipitoatlantal joint, rapidly bled and the skulls were prepared using the skull maceration process (Olude et al., 2009). The form (shape, size and position) of the entire skull and individual bones of the skull were studied using information from Olude et al., (2009), Hebel and Stromberg (1976) as guides. The live weight of the animals and the decapitated heads were determined using an electronic weighing machine (Mettler Toledo®). Thirty craniometric parameters apart from weights were determined as adapted from Olude et al., (2009), Fernandes et al., (2008), and Wysocki (1985) (see Table 1). Measurements were taken using ruler, vernier calipers, measuring cylinder, pair of dividers, plasticine and twines. The parameters were recorded in centimetre (cm), millilitre (mL) and percentage (%). Data obtained were analyzed using the student t-test ( $p \leq 0.05$ ) and all analyses were done using the SPSS version 15.

Table 1: Parameters and the definitions of dimensions used in morphometric analysis

<b>FEATURES</b>	<b>DIMENSION TAKEN</b>
FRONTAL BONE LENGTH (FBL)	Total length of frontal bone from the fronto - nasal suture to the suture fronto -inter parietal suture
NASAL LENGTH (NSL)	Overall length of the nasal bone from the rostral end of the frontal bone to the rostral tip of the nasal bone.
FRONTOPARIETAL TO NUCHAL EMINENCE (FNE)	Length from the frontoparietal suture to the nuchal eminence
INTERPARIETAL TO NUCHAL CREST (INC)	Length from the interparietal bone to the tip of the nuchal crest.
RIGHT INFRAORBITAL LENGTH (RIOL)	Greatest length across the right infraorbital foramen.
LEFT INFRAORBITAL LENGTH (LIOL).	Greatest length across the left infraorbital foramen
INTERPARACONDYLAR WIDTH (IPCW)	The greatest breadth of the ventromedial ends of the jugular processes
INTERCONDYLAR WIDTH (ICW)	Width between the lateral ends of the occipital condyles
BASAL SPHENOID LENGTH (BSL)	Length of the basisphenoid
BASAL OCCIPITAL LENGTH (BOL)	Length of the basioccipital portion of the occipital bone from the tip of the foramen magnum to the suture formed between the basioccipital and the basisphenoid bones.
MAXIMUM MANDIBULAR HEIGHT (MMH)	From the base of the mandible to the highest level of the coronoid process
HEIGHT FROM CONDYLOID FOSSA TO MANDIBLE BASE (CFMB)	From the condyloid fossa to base of the mandible
CONDYLOID FOSSA TO HEIGHT OF MANDIBLE (CFMH)	From the maximum height of mandible to the condyloid fossa.
MANDIBULAR SYMPHYSEAL LENGTH (MSL)	Length from rostral to caudal limit of the mandibular symphysis.
DIASTEMAL GAP LENGTH (DGL)	Length of the lower diastemal gap from the lateral end of the alveolus of the lateral incisor (on the bony ridge to the cranial border of the alveolus of the 1 <sup>st</sup> molar).

DIASTEMAL CURVE LENGTH (DCL)	Length of the diastemal curve from the lateral end of the alveolus of the lateral incisor (on the bony ridge to the cranial border of the alveolus of the first molar)
UPPER DIASTEMAL GAP LENGTH (UDG)	Maximum length of the upper diastemal gap.
LEFT ORBITAL LENGTH (LOL)	Maximum circumference of the left orbit from rim to rim (includes maximum horizontal and maximum vertical diameters).
RIGHT ORBITAL LENGTH (ROL)	Maximum length of the right orbit from rim to rim (includes maximum horizontal and maximum vertical diameters).
LEFT ORBITAL CIRCUMFERENCE (LOC)	Maximum circumference of the left orbit from rim to rim.
RIGHT ORBITAL CIRCUMFERENCE (ROC)	Maximum circumference of the right orbit from rim to rim
LEFT ORBITAL HEIGHT (LOH)	Maximum height of the left orbit from the dorsal tip of the orbital rim to the ventral tip of the orbital rim
RIGHT ORBITAL HEIGHT (ROH)	Maximum height of the right orbit from the dorsal tip of the orbital rim to the ventral tip of the orbital rim
ZYGOMATIC WIDTH (ZGW)	Maximum width across the zygomatic arches
INTERCANTHI WIDTH DISTANCE (ICD)	Minimum distance between the medial margins of the orbits
RIGHT ORBITAL INDEX (ROI)	$ROH/ROL \times 100$
LEFT ORBITAL INDEX (LOI)	$LOH/LOL \times 100$
UPPER DIASTEMAL LENGTH (UDL)	Length of the gap diastemal gap from the lateral end of the alveolus of the lateral incisor on the bony ridge to the cranial border of the alveolus of the 1 <sup>st</sup> molar).
RIGHT INFRAORBITAL BREADTH (RIOB)	Maximum breadth of the right infraorbital foramen from the lateral to medial rim
LEFT INFRAORBITAL BREADTH (LIOB)	Maximum breadth of the left infraorbital foramen from the lateral to medial rim

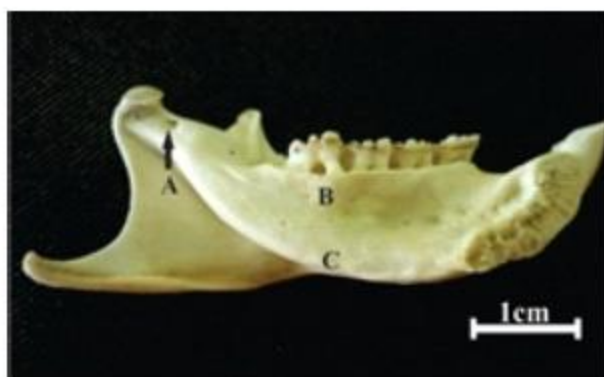Table 2: Morphometric measurements between both sexes in the skull of GCRs expressed as mean  $\pm$  SEM.

S/No.	PARAMETER	OVERALL MEAN(cm)	TOTAL FEMALE (MEAN)	TOTAL MALE (MEAN)
1	ICW	2.47 $\pm$ 0.14	2.50 $\pm$ 0.14	2.43 $\pm$ 0.13
2	IPCW	2.60 $\pm$ 0.14	2.57 $\pm$ 0.11	2.63 $\pm$ 0.16
3	BSL	1.30 $\pm$ 0.11	1.33 $\pm$ 0.08	1.27 $\pm$ 0.13
4	*BOL	1.30 $\pm$ 0.09	1.17 $\pm$ 0.08	1.43 $\pm$ 0.11
5	NSL	2.75 0.26	2.77 $\pm$ 0.29	2.73 $\pm$ 0.23
6	FBL	2.58 $\pm$ 0.21	2.70 $\pm$ 0.20	2.47 $\pm$ 0.22
7	FNE	3.12 $\pm$ 0.16	3.23 $\pm$ 0.16	3.00 $\pm$ 0.16
8	*INC	2.10 $\pm$ 0.15	1.50 $\pm$ 0.10	2.70 $\pm$ 0.20
9	ZGW	3.92 $\pm$ 0.13	3.90 $\pm$ 0.10	3.93 $\pm$ 0.16
10	ICD	2.75 0.18	2.67 $\pm$ 0.19	2.83 $\pm$ 0.16
11	*DCL	1.28 $\pm$ 0.24	1.83 $\pm$ 0.40	0.73 $\pm$ 0.08
12	*DGL	1.3 $\pm$ 0.08	2.03 $\pm$ 0.08	0.73 $\pm$ 0.08
13	*UDG	2.08 0.10	2.00 $\pm$ 0.07	2.17 $\pm$ 0.13
14	UDL	2.17 $\pm$ 0.11	2.23 $\pm$ 0.12	2.10 $\pm$ 0.10
15	RIOL	2.22 $\pm$ 0.12	2.17 $\pm$ 0.08	2.27 $\pm$ 0.16
16	LIOL	2.13 $\pm$ 0.15	2.10 $\pm$ 0.14	2.17 $\pm$ 0.16
17	RIOB	1.02 $\pm$ 0.08	1.00 $\pm$ 0.00	1.03 $\pm$ 0.15
18	LIOB	0.98 $\pm$ 0.11	0.97 $\pm$ 0.12	1.00 $\pm$ 0.10
19	MSL	7.85 $\pm$ 0.33	8.07 $\pm$ 0.08	7.63 $\pm$ 0.57
20	CFMB	2.22 $\pm$ 0.11	2.23 $\pm$ 0.08	2.20 $\pm$ 0.14
21	CFMH	0.47 $\pm$ 0.09	0.50 $\pm$ 0.07	0.43 $\pm$ 0.11
22	*MMH	2.78 $\pm$ 0.12	2.93 $\pm$ 0.08	2.63 $\pm$ 0.16
23	LOL	2.25 $\pm$ 0.11	2.23 $\pm$ 0.08	2.27 $\pm$ 0.13
24	ROL	2.25 $\pm$ 0.11	2.23 $\pm$ 0.08	2.27 $\pm$ 0.13
25	*LOH	1.85 $\pm$ 0.10	2.00 $\pm$ 0.10	1.70 $\pm$ 0.10
26	*ROH	1.88 $\pm$ 0.10	2.07 $\pm$ 0.11	1.70 $\pm$ 0.10
27	*ROC	6.98 $\pm$ 0.26	6.73 $\pm$ 0.30	7.23 $\pm$ 0.22
28	*LOC	7.02 $\pm$ 0.25	6.73 $\pm$ 0.29	7.30 $\pm$ 0.20
29	*ROI	83.83 $\pm$ 3.83	92.67 $\pm$ 6.66	75.00 $\pm$ 1.00
30	*LOI	82.33 $\pm$ 3.25	89.67 5.51	75.00 $\pm$ 1.00

\* Statistically significant parameters after t-test at 5% level of significance.

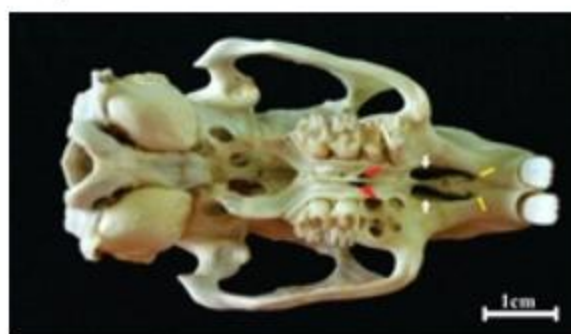## RESULTS

The mean head weight for males and females were recorded as  $0.33 \pm 0.08$  kg and  $0.25 \pm 0.07$  kg; while mean body weight also as  $2.86 \pm 0.20$  kg and  $2.13 \pm 0.25$  kg respectively; the female body weight being significantly higher than males (Table 2). Values of 12 other morphometric parameters were significant; 7 of which were female-biased. The orbital heights were statistically significant ( $p \leq 0.05$ ) and higher in females than in males but the orbital circumference parameters were biased towards males (Table 2).

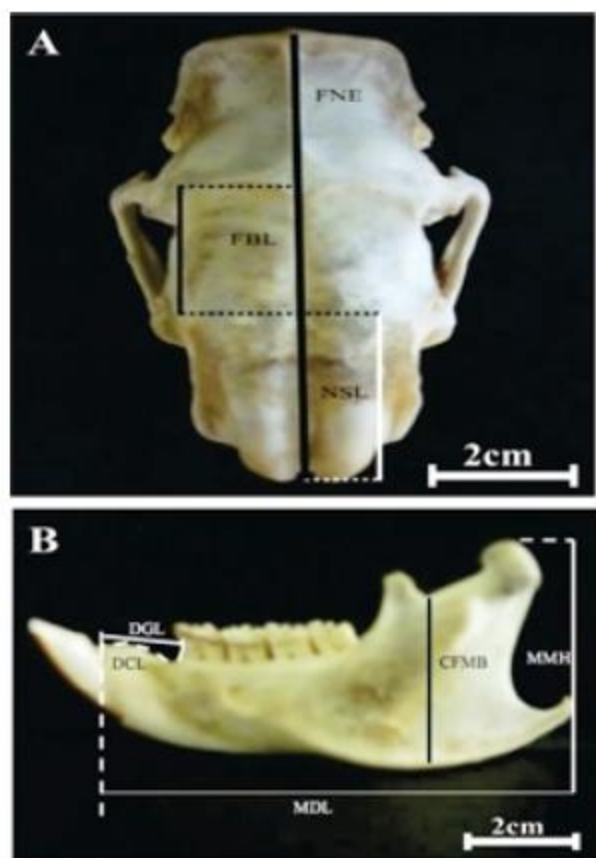


**Figure 1:** Medial view of the mandible of the greater cane rat. Note the mandibular foramen (A), lower cheek teeth (B), bulgy medial alveolar bulla ©. The mandibles were observed to be fused at the rostral symphysis. Caudal to the incisor teeth and at the rostral end of the symphysis was a depression which had nutrient foramina. The depressed area continued caudally for approximately 1.4 cm before the mandibles took an angular divergence at an approximate angle of  $53^\circ$  and followed a line which projected caudal and upward to terminate on the medial surface of condyloid process. This arrangement gave the medial surface a peculiar bulgy area housing the lower alveolar tooth (Figure 1) of about 1.5 cm to the lateral surface. The caudal aspect appeared and ended as a thin plate about midway of the length of the ventral mandibular rim. The caudal end of the symphyseal fusion formed a wedge into the opposite mandible. The mandible

presented 4 typical processes namely: the angular process, coronoid process, condyloid process and the incisor alveoli. The condyloid process was stout with articular surfaces on both ends, there was an angular process which extended about 1 cm caudal to the caudal vertical edge of the ramus and tapered curving slightly upward. The mandibular foramen was found typically midway between the coronoid and condyloid processes. Nutrient foramina were caudally situated few centimetres from the 3rd molar teeth. The mental foramen appeared to be represented by a collection of small foramina. The lateral surface of the mandible presented a tuberosity of varying prominence. This tuberosity is ventral to the 1st molar and rostral to a line which runs ventrally to join the angular process of the ramus. Dental formula was found to be I 1/1, C 0/0, P 1/1, M 3/3. All the skulls had erupted molar teeth.

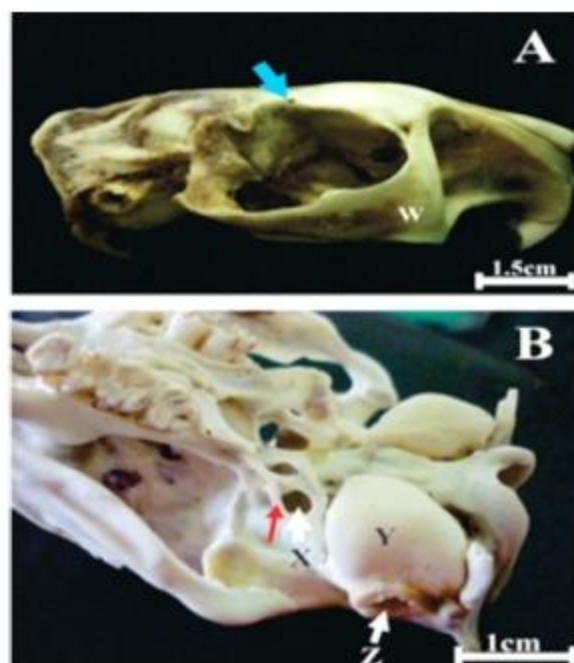


**Figure 2:** Ventral view of greater cane rat skull showing the rostral "unnamed" foramina (yellow arrows), incisive foramen (white arrows), and major palatine foramina (red arrows). Typical features of the rodents' skull were observed. The frontonasal suture showed variations in shape with wedge, transverse and U-shaped rostral tips. All males (100%) had transversely oriented rostral



**Figure 3:** Greater cane rat skull showing morphometric outlines of some measured parameters: (A) Dorsal view of skull and (B) Lateral view of mandible. NSL= Nasal length; FBL= Frontal bone length; FNE= Frontal to nuchal eminence length; DGL= Diastemal gap length; MDL= Mandibular distant length; MMH= Maximum mandibular height; CFMB= Condyloid fossa base to mandibular base; DCL= Disastemal curve length.

incisive foramen had a prominently raised ridge on the incisive bone in all males and some of the females. Immediately rostral to the foramen were two smaller foramina and in two specimens, the rostral foramina were more than one on each half of the median plane (Figure 2). The incisive foramen was found with a rostral unnamed foramen. However from this study, 50% (n=5) of the skulls had 3 rostral unnamed foramina while 1 had the typical 2 foramina. The rest (n=4) had only one of such foramen. Morphometric parameters were taken from dorsal,



**Figure 4:** (A) Lateral view of the greater cane rat skull showing supraorbital foramen (blue arrow) and the complete zygomatic arch (W); (B): Ventrolateral view of the skull showing the foramen ovale (X) and a spicule (red arrow) crossing it, the tympanic bulla (Y) and the external acoustic meatus (Z).

ventral, and lateral mandibular regions of the skull (Figure 3). The supraorbital foramen appeared on the dorsal part of the frontal bone, ventral to the bony rim and on the bony rim. There were variations in the location of the supraorbital foramen. Thirty percent had it on the dorsal part of the orbital rim on both sides, 10% had it ventral to the orbital rim on both sides. Ten percent had double foramina, the typical foramen being on the rim with the extra foramen located on the caudodorsal part of the left orbit and the dorsal part of the orbital rim on the right. All other skulls presented the foramen on the rim (Figure 4a). The zygomatic arch was fully formed and complete in this animal and was composed of the zygomatic process of the temporal bone, the temporal process of zygomatic bone and a 3rd triangular jugal bone (Figure 4a). The infraorbital foramen had an average breadth of  $1.02 \pm 0.08$  cm (right) and  $0.98$

$\pm 0.11$  cm (left). The greatest length was  $2.22 \pm 0.13$  cm (right) and  $2.13 \pm 0.19$  cm (left) respectively. A spicule was noted across the foramen ovale in all specimens examined with a prominent tympani bulla caudal to the spicule (Figure 4b).

#### DISCUSSION

This study on the skull of the GCR showed typical rodent features as described by Van der Merwe (2007) and presents cranio-morphometric parameters of various structures. Parameters studied were generally higher in females than in males. From the total 30 parameters studied, males were higher in 5 while females were higher in 7. Twelve of the total parameters were significantly sexually dimorphic, with higher values recorded more in females and confirm the presence of sexual dimorphism in the skull of the GCR. The skulls of males and females differed more in size than in shape; similar to the mink but contrary to badgers and otters which differ more in shape than in size (Wiig, 1985). Mandibular parameters were higher in females with some parameters being statistically significant with higher values noted more in females. This could imply greater efficiency in mastication since the larger indices indicate a larger surface area. Naturally, larger female skulls will have larger jaw muscles and larger absolute gape (Greaves, 1983). The functional significance of this dimorphism may mean that the females have a stronger bite than the males. Moors (1980) discussed two theories which account for sexual dimorphism in mustelids as including food exploitation and sexual selection.

The dental formula in GCR  $2(I1/1, Co/0, P1/1, M3/3)$  is atypical to that of mole rats and African Giant Rat  $2(I1/1 Co/0 Po/0 M3/3)$  (Demirsoy, 1998; Olude et al., 2010; Mustapha et al., 2014) and moles  $2(I3/3, C1/1, P4/4, M3/3)$  (Saunders and Manton, 1969). The incisors of Rodentia have a characteristic chisel-shaped form, and lack roots (Vinogradov and Argipulo, 1941). The

teeth were as described by Van der Merwe (2007) with the upper incisors dorsoventrally directed and the lower incisors rostradorsally inclined. The upper incisor teeth curved deep into the cavity of the alveolar process created in the skull for approximately  $3.7 \pm 0.32$  cm as against the lower teeth  $5.05 \pm 0.23$  cm. It is difficult to ascertain if this extension gives it some reinforcement as the teeth appeared to be fragile.

Dentition gives clues to the diet of mammals (UMD, 2009) and that of the GCR reflects its dietary habits as herbivores whose natural diet is mainly grasses and cane (Fitzinger, 1995). The GCR favourite food is elephant grass and sweet potatoes (National Research Council, 1991) as they prefer plants with lots of moisture and soluble carbohydrates (Agbelusi, 1997). The sharp incisors (used for cutting and gnawing) and the presence of a system of flat premolars and molars (for grinding and crushing) make the GCR well suited for this diet. Foramen ovale spicules were present and were observed to break easily during preparation. This is in consonance with the findings of Van der Merwe (2007) but contrary to reports of Olude et al., (2010) who observed no spicules in the African Giant Rat. The incisive foramen was found with the rostral unnamed foramen as described by Van der Merwe (2007). However in this study, 50% of the skulls had 3 rostral unnamed foramina while another had 2. The authors considered it inappropriate to call the foramen unnamed and thus, have proffered a name as the 'rostral accessory incisive foramen of Amarawike'

The infraorbital foramen was higher in length and breadth in GCR, as reported in Rodentia (Vinogradov and Argipulo, 1941). The average greatest breadth of this foramen was  $1.02 \pm 0.08$  cm (right) and  $0.98 \pm 0.11$  cm (left). The greatest length was  $2.22 \pm 0.13$  cm (right) and  $2.13 \pm 0.19$



cm (left) respectively.

The zygomatic arch of the GCR was complete and fully formed. In the skulls of moles, the zygomatic arch is often incomplete and the jugal bone may be small or absent (Saunders and Manton, 1969). The small jugal bone is present in the Rodentia (Vinogradov and Argipulo, 1941). Zygomatic arch is not complete in many species of the order Insectivora (Oktay, 1988). In this current study, zygomatic arch was well developed and composed of zygomatic process of temporal bone, the temporal process of zygomatic bone and a 3rd triangular jugal bone. In the skulls of moles, there is usually no bulla (Saunders and Manton, 1969). In this study, a well-developed bulla tympanica was also identified. The skulls of adult rodents often bear crests (Vinogradov and Argipulo, 1941). Similarly, a significant nuchal crest lying horizontally and the crista sagittalis externa were prominent.

In mole-rats and the African Giant Rat, there are 4 processes of the ramus mandibulae. In the present study, the condylar process was larger than coronoid process and condylar process was caudo-dorsally directed in mole-rats. In mole rats, the transit portion from the condylar process to the angular process was significantly curved in the GCR as also reported in the mole rats, while it is linear in badgers (Hidaka et al., 1998).

Therefore, we conclude that there is a consistent sexual dimorphism in the skull of the GCR. This study provided baseline research data on the skull typology of the GCR and will be useful also in the clinical management of this animal.

## REFERENCES

- ADDO, P. (2002). Detection of mating, pregnancy and imminent parturition in the grasscutter (*Thryonomys swinderianus*). Livest. Res. Rural Dev. 14 (4). <http://www.cipav.org.co/lrrd/lrrd14/4/addo144.htm>
- ADDO, P., DODOO, A., ADJEI, S., AWUMBILA, B. and AWOTWI, E. (2002). Determination of the ovulatory mechanism of the grasscutter (*Thryonomys swinderianus*). J. Anim. Reprod. Sci., 22(2): 11-13.
- ADEBAYO, A.O. and OLURODE, S.A. (2010). The morphology and morphometry of the epididymis in the greater cane rat (*Thryonomys swinderianus* Temminck). Folia Morphol., 69(4): 246-252.
- ADEBAYO, A.O., OKE, B.O. and AKINLOYE, A.K. (2009). Characterizing the gonadosomatic index and its relationship with age in greater cane rat (*Thryonomys swinderianus*, Temminck). J. Vet. Anat., 2: 53-59.
- ADJANOHOUN, E. (1993): Quelques Aspects Du Cycle Sexual De L'aulacode (*Thryonomys swinderianus* Temminck, 1827) Et Leurs Consequences Pratiques Sur La Conduite Des Elevages. In: 1<sup>er</sup> Conference Internationale L'aulacodiculture: Acquis Et Perspectives (Schrage R. and Yewadan LT, Eds): 111-118.
- ADU, E.K. and YEBOAH, S. (2000). The efficacy of the vaginal plug formation after mating for pregnancy diagnosis and embryonic resorption in utero in the greater cane rat (*Thryonomys swinderianus* Temminck). J. Trop. Anim. Health Pro., 32: 1-10 Kluwer Academic Publishers, Netherlands
- AGBELUSI, E. (1997): Ranching Grasscutter *Thryonomys swinderianus* T. For Meat Production in the Humid Forest

- Zone of Nigeria (On-line).FAO July Publication .  
<http://www.fao.org/montes/foda/wforcong/PUBLI/V3/T18E/2-2.HTML>.
- AJAYI, S.S. (1974): The Biology and Domestication of African Giant Rat (*Cricetomys gambianus* Waterhouse). PhD Thesis, University of Ibadan, Ibadan.
- ALLABY, M. (1999): Hystricomorpha: A dictionary of Zoology. Oxford University Press. Oxford.
- ASIBEY, E.O.A. and ADDO, P.G. (2000). The Grasscutter: A Promising Animal for Meat Production. In: African Perspective.Practices and Policies Supporting Sustainable Development. Turnham D. (Ed.). Scandinavian Seminar College, Denmark, in association with Weaver press, Harare, Zimbabwe: 120.
- BEZERRA, A.M.R. and DE OLIVEIRA, J.A. (2010). Taxonomic implications of cranial morphometric variation in the genus *Clyomys* Thomas, 1916 (Rodentia: Echimyidae). *J. Mammal.*,91(1): 260-272. doi: <http://dx.doi.org/10.1644/08-MAMM-A-320R1.1>
- BOKONYI, S. (1974): History of Domestic Animals in Central and Eastern European. Akademiai, Budapest:597.
- BYANET, O., ONYEANUSI, B.I., and IBRAHIM, N.D.G. (2009).Sexual dimorphism with respect to the macro-morphometric investigations of the forebrain and cerebellum of the Grasscutter (*Thryonomys swinderianus*).*Int. J. Morphol.*, 27(2): 361-365. <http://dx.doi.org/10.4067/S0717-95022009000200010>
- DEMIRSOY, A. (1998): Rodentia, Basic Rules of Life, Meteksan Corporation, Ankara: 621-629.
- DORST, J. and DANDELLOT, P. (1969): A Field Guide to the Larger Mammals of Africa. Boston: Houghton Mufflin Company.
- DWARIKA, S., MASEKO, B.C., IHUNWO, A.O., FUXE, K. and MANGER, P.R. (2008). Distribution and morphology of putative catecholaminergic and serotonergic neurons in the brain of the greater cane rat, *Thryonomys swinderianus*. *J. Chem. Neuroanat.*, 35: 108–122.
- ELSTON, G.N. and MANGERP. (2014). Pyramidal cells in V1 of African rodents are bigger, more branched and more spiny than those in primates. *Front. Neuroanat.*,8: 4. doi: 10.3389/fnana.2014.00004
- ENDO, H., HAYASHI, Y., YAMAZAKI, K., MOTOKAWA, M., PEI, J., LIN, L., CHOU, C. and OSHIDA, T. (2002). Geographical Variation of the mandible size and shape in the wild pig (*Suisscrofa*) from Taiwan and Japan. *Zool. Stud.*, 41(4): 452–460.
- FERNANDES, R.M., ANTONIO, V.A., ROBERTO, B.S., DAIELLE, F.S., GISELE, L.M., MARCIO, A.B. and CRISTIANE, F.R. (2008). Maternal malnutrition lactation reduces skull growth in weaned rat pups: Experimental and morphometric investigation. *Anat. Sci. Int.*, 83: 123–130.
- FITZINGER, (1995): Cane Rats. In R Nowak, Ed. Walker's Mammals of the World. The Johns Hopkins University Press: 1650-1651.
- GREAVES, W.S. (1983).A functional analysis of carnassials biting.*Biol. J. Linnean. Soc.*, 20: 353–363.
- HEBEL, R. and STROMBERG, M.W. (1976): Anatomy of the Laboratory Rat. The Wilkins and Wilkins Company, 428 E. Preston Street,

- Baltimore, Md. USA: Library of Congress Cataloging in Publication Data: 1-11.
- HIDAKA, S., MATSUMOTO, M., HIJI, H., OHSAKO, S. and NISHINAKAGAWA, H. (1998). Morphology and morphometry of skulls of raccoon dogs, *Nyctereutes procyonoides* and badgers, *Melesmeles*. *Vet. Med. Sci.* 60: 161-167.
- KUNZEL, W., BREIT, S. and OPPEL, M. (2003). Morphometric investigation of breed specific features in feline skull and consideration on their functional implication. *Anat. Hist. Embryol.* 32(4): 218-222.
- MOORS, P.J. (1980). Sexual dimorphism in the body size of mustelids (carnivora): the roles of food habits and breeding systems. *Oikos*, 34: 147-158.
- MUKERJEE, B. and RAJAN, T. (2006). Morphometric study of seminal vesicle of rat in normal health and stress conditions. *J. Anat. Soc. India*, 55(1): 31-36.
- MUSTAPHA, O.A., AYOADE, O. E., OGUNBUNMI, T. K. and OLUDE, M. A. (2014). Morphology of the oral cavity of the African giant rat (*Cricetomys gambianus*, Waterhouse). *Bulg. J. Vet. Med.* (in press), ISSN 1311-1477, online at [http://tru.unis-  
sz.bg/bjvm/bjvm.htm](http://tru.unisz.bg/bjvm/bjvm.htm).
- NATIONAL RESEARCH COUNCIL (1991): *Microlivestock: Little-Known Small Animals with a Promising Economic Future*. National Academic Press, Washington DC: 233-240.
- OKTAY, M. (1988): *Omurgalı Hayvanların Karşılaştırmalı Anatomisi*, İst Ün Yay Sayı 3489, Fen Fak. Sayı 203, İst. Ün.Fen.Fak.Basımevi, İstanbul: 56-117.
- OLAYEMI A., NICOLAS V., HULSELMANS J., MISSOUP A.D., FICHET-CALVETE., AMUNDALA D., DUDU A., DIERCKX T., WENDELEN W., LEIRS H., and VERHEYEN E., (2012): Taxonomy of the African giant pouched rats (*Nesomyidae: Cricetomys*): molecular and craniometric evidence support an unexpected high species diversity. *Zool. J. Linnean. Soc.*, 165 (3): 700-719. doi: 10.1111/j.1096-3642.2012.00823.x
- OLAYEMI, A. (2007): *Taxonomic Evaluation by Morphometric Analysis of Various Muroid Rodents from Parts of Southwestern Nigeria*. PhD Thesis, Obafemi Awolowo University, Ile Ife, Nigeria
- OLOPADE, J.O. (2006): *Morphometric Analysis of the Skull of Three Breeds of Goats in Nigeria*. PhD Thesis, Department of Veterinary Anatomy, University of Ibadan, Nigeria.
- OLOPADE, J.O. and ONWUKA, S.K. (2005). Some aspects of the clinical anatomy of the mandibulae and maxillofacial regions of the West African dwarf goat in Nigeria. *Int. J. Morphol.*, 23(1): 33-36.
- OLUDE, M.A., OLOPADE, J.O., AKINLOYE, A.K. and MUSTAPHA, O.A. (2010). Macro-anatomical investigations of the skeletons of the African giant rat (*Cricetomys gambianus* Waterhouse 1840) II: Fore limb. *Eur. J. Anat.*, 14(1): 19-23.
- OLUDE, M.A., OLOPADE, J.O., FATOLA, I.O. and ONWUKA, S.K. (2009). Some aspects of the neurocraniometry of the African

- giant rat (*Cricetomys gambianus* Waterhouse). *Folia Morphol.*,68(4): 224–227.
- OLUKOLE, S.G. (2009). Morphometric analysis of the kidneys of the adult domesticated African greater cane rat (*Thryonomys swinderianus*). *Eur. J. Anat.*, 13 (3): 117-120.
- ONADEKO, S.A. (1996): The Reproductive Ecology of the Grasscutter (*Thryonomys swinderianus* Temminck) in Captivity. PhD Thesis, University of Ibadan, Ibadan.
- OPARA, M.N., IKE, K.A. and OKOLI, I.C. (2006). Haematology and plasma biochemistry of the wild adult African Grasscutter (*Thryonomys swinderianus*; Temminck). *J. Am. Sci.*,2(2): 1722.
- REISSER, C.M.O., MARSHALL, B.A. and GARDNER, J.P.A. (2012). A morphometric approach supporting genetic results in the taxonomy of the New Zealand limpets of the *Cellanastrigilis* complex (Mollusca :Patellogastropoda : Nacellidae). *Invertebr. Syst.*,26: 193–203. <http://dx.doi.org/10.1071/IS11042>
- SAUNDERS, J.T. and MANTON, S.M. (1969): *A Manual of Practical Vertebrate Morphology*. 4th Ed. Charendon Press, Oxford.
- SPRUSTON, N. (2008). Pyramidal neurons: dendritic structure and synaptic integration. *Nat. Rev. Neurosci.*, 9(3): 206-221. doi: 10.1038/nrn2286.
- UNIVERSITY OF MINNESOTA DULUTH (UMD). (2009): Teeth: Laboratory 2 Worksheet. Skull Skeleton Lab 3 Document: 8 - 17. [http://www.d.umn.edu/~rmoen/Mammalogy\\_4764\\_2009/Handouts/Lab\\_01\\_Teeth.pdf](http://www.d.umn.edu/~rmoen/Mammalogy_4764_2009/Handouts/Lab_01_Teeth.pdf)
- VANDERMERE, M. (2007). Discriminating against *Thryonomys swinderianus* and *Thryonomys gregorianus*. *Afr. Zool.*,42(2): 165–171.
- VINOGRADOV, B.S. and ARGIPULO, A.I. (1941): *Fauna of the U.S.S.R, Mammals*, Zoological Institute of the Academy of Sciences of the U.S.S.R, New Series No. 29, Moskova.
- WEBB, J.E., WALLWORK, J.A. and ELGOOD, J.H. (1979): *Guide to Invertebrate animals*. 2nd Ed. London.
- WIIG, O. (1985). Multivariate variation in feral American mink (*Mustelavison*) from Southern Norway. *J. Zool.*,206: 441–452.
- WYSOCKI, J. (1985). Topographical anatomy and measurements of selected parameters of the rat temporal bone. *Folia Morphol.*,67(2): 111–119.