

# Superfetation in a Double Uterus – A Case Report

Umar Nasir Ibrahim, Musa Dauda, Khan Nighat, Imeh E. Okon

Superfetation is not usually a human phenomenon, except in rare cases of double uterus and continuous menstruation during pregnancy. This report describes the condition in the presence of a double uterus.

*Niger Med J. Vol. 50, No. 2, April – June, 2009: 52 – 53.*

**Key words: Superfetation, Double Uterus, Intra Uterine, Fetal Death.**

## INTRODUCTION

Superfetation is the formation of a fetus while another fetus is already present in the uterus. It is claimed to be common in some farm animals (horses and sheeps) but extremely rare in humans, this is because after fertilization, mechanisms are put in place to prevent further ovulation. Theoretically superfetation may occur before the obliteration of the uterine cavity by the fusion of decidua capsularis and decidua vera. It may also be induced artificially<sup>1</sup>.

The case reported here describes a situation where second pregnancy occurs in a multipara who is already in a midtrimester of the first pregnancy, each of the pregnancies in a separate uterus.

## CASE REPORT

Mrs I. A was a 25years old Gravida 4 para 3, +0 who was 24 weeks pregnant at the time of presentation, she was unbooked, with no history of any chronic medical illness, menstrual irregularities or bad Obstetrics history. She reported to a rural clinic with the complaints of absence fetal movement, abdominal pains and a non “growing abdomen”.

Physical examination reveals a stable woman with a symphysiofundal height of 20cm, normal external genitalia and a single vagina. Ultrasound scan showed a dead fetus at 24 weeks gestation and a separate viable embryo at eight weeks gestation (fig 1). A diagnosis of heterotopic pregnancy was made and she was scheduled for Laparotomy. At surgery two uteri were discovered (fig 2). The dead fetus was extracted fig 3, 4 and 5. She did well post operatively, continued antenatal care and was delivered at term by ceaserean section of a live male fetus that weighed 3.2kg.

.....  
**From:** Department of Obstetrics and Gynaecology, Federal Medical Centre, Azare, Bauchi State Nigeria.  
E-mail: unibrahim2000@yahoo.co.uk

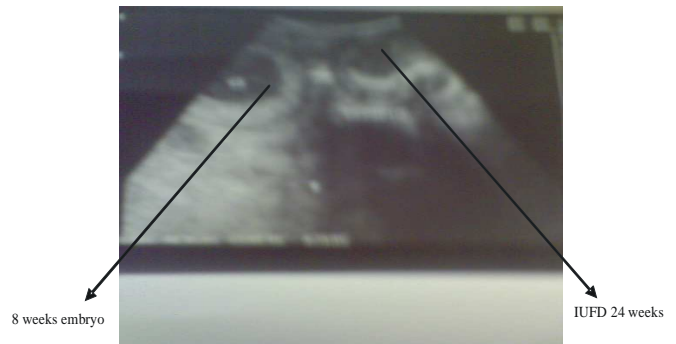


fig. 1:

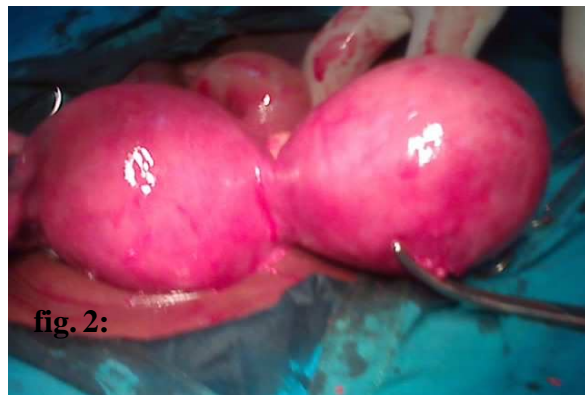

fig. 2:

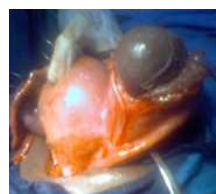

fig 3

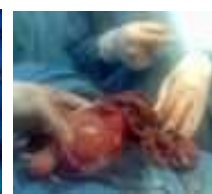

fig 4

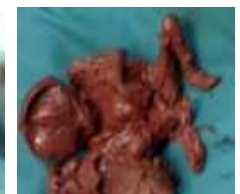

fig 5

## DISCUSSION

Reports of superfetation in human has often been treated with suspicion and some have clearly being discredited, as merely a cases of different level of development between twins.

The case presented occurred in a double uterus. The argument for superfetation in this case is the fact that there is at least a difference of Sixteen weeks between the two fetuses

#### SUPERFETATION IN A DOUBLE UTERUS

taking into consideration the collapse and autolysis in the dead fetus, also the occurrence of the pregnancies in separate uteri and their differential size. Superfetation occurring in pseudodidelphys uterus has been reported<sup>2</sup>.

The cause of the second ovulation is not known, probably caused by the fallen levels of the hormones due to the death of the first fetus or it may have occurred before the fetal demise, because of the available space in the second uteri. With advances in assisted reproductive techniques cases of superfetation are likely to be on the increase, and where there is doubt, ultrasound scan, ballard score, x – ray of the lower limbs, dental age on x – ray and ophthalmic examination may help in determining the gestational ages of the fetuses<sup>3</sup>.

#### REFERENCES

1. Dmowski W. P., Deooriol, Rana N. Embryo implantation during menstruation in the absence of adequate estradiol and progesterone support, with subsequent normal response to ovulation induction and superfetation. *Fertil. Steril* 1997; **68(3)**: 538–41.
2. Singhai S. R., Agarwal U., Sharma D., Sen J. Superfetation in uterus pseudo didelphys: an unreported event *Arch Gynecol Obstet* 2003; **268(3)**: 243–4.
3. Baijal N, Sahni M, Verma N, Kumar A, Parkhe N, Puliye JM. Discordant twins with the smaller baby appropriate for gestational age – unusual manifestation of superfetation: a case report. *BMC Paediatr* 2007; **197**: 2.