

Gastric Diverticulum: A Case Report

*OLOKOBA A. B., *OGUNMODEDE J. A., *OBATERU O. A., *YUSUF M.,
*BAMIDELE O.N., *AGBEDE O.E.

SUMMARY

Background: A gastric diverticulum is an out-pouching of the stomach that has similar characteristics to diverticula in other parts of the gastrointestinal tract. They are relatively rare findings.

Objective: The objective of this case report is to highlight a rare case of gastric antral diverticulum discovered incidentally during upper gastrointestinal endoscopy.

Case Report: A case of a 33 year old woman who presented with dyspepsia of moderate intensity, belching, nausea, but no vomiting or bloating of a few weeks duration. An initial diagnosis of acid peptic disease was made. She had an upper gastrointestinal endoscopy done which revealed mild gastric antral and duodenal inflammation. She was placed on a triple regimen of proton pump inhibitor and two antibiotics. She had a repeat endoscopy done 8 weeks later by which time the symptoms had greatly improved. The second endoscopy also revealed that the inflammation had resolved however a gastric diverticulum was noted in the antrum.

Conclusion: This case of gastric antral diverticulum is rare, and is the first one reported from Nigeria.

Niger. Med J. Vol. 49, No. 4, Oct – Dec, 2008: 104–105.

Keywords: Gastric Diverticulum, Rare, Endoscopy

INTRODUCTION

Gastric diverticula are infrequent anatomic abnormalities that are usually asymptomatic. Although most symptomatic patients are diagnosed during evaluation of vague epigastric discomfort, severe complications including perforation and hemorrhage may occur. A gastric diverticulum is an out-pouching of the stomach that has similar characteristics to diverticula in other parts of the gastrointestinal tract. They are relatively rare findings¹. Prevalence rates reported by Rodeberg et al in 2002 were 0.02% in autopsies and 0.04% in radiological studies²; while Raffin in 1989 reported 0.01-0.03%³. They occur in all ages, but are most common in middle age⁴, typically in the 5th to 6th decade⁵. There is no sexual predilection.

.....
From: *University of Ilorin Teaching Hospital/University of Ilorin. P.M.B.1459, Ilorin, Kwara State, **Department of Paediatrics, Federal Medical Centre, P.M.B. 005, Azare, Bauchi State.

Correspondence: DR OLOKOBA A. B. FWACP, DTMH(LONDON), MBA *Department of Medicine, University of Ilorin Teaching Hospital Ilorin, Ilorin. Kwara State. Email: drabolokoba@yahoo.com 08038050480, 08053357173

There are two types of gastric diverticula- the true diverticulum which involves the full thickness of the stomach wall and the partial (pseudo- or intramural) diverticulum which is a projection of the gastric mucosa into but not through the muscle layer.

75% of gastric diverticula occur in the posterior wall of the cardia near the lesser curvature close to the oesophagogastric junction (juxta-cardiac diverticula) while the partial type occurs commonly in the pre-pyloric antrum. They vary in size from 1cm to 10 cm in diameter. The aetiology of gastric diverticula is unknown, but predisposing factors to diverticula formation include peptic ulcer disease, carcinoma, and adjacent inflammatory conditions. Diverticula have also been reported to occur post-operatively⁶. Diverticula occur where there is high intraluminal pressure, are usually asymptomatic, but in some cases, the patients may present with epigastric pain, fullness or discomfort; or symptoms of oesophageal reflux.

CASE SUMMARY

The patient was a 33 year old woman who presented with dyspepsia of moderate intensity, belching and nausea of a few weeks duration. There was no vomiting or bloating. An initial diagnosis of acid peptic disease was made. She had an upper gastrointestinal endoscopy done which revealed mild gastric antral and duodenal inflammation. She was placed on a 2-week course of omeprazole 20mg bid, and a 1-week course of clarithromycin 500mg bid and amoxicillin 1g bid. She had a repeat endoscopy done 8 weeks later by which time the symptoms had greatly improved. The second endoscopy also revealed that the inflammation had resolved. During the session too, a gastric diverticulum was noted in the antrum (fig 1 and 2). It appeared normal with a normal overlying mucosa.

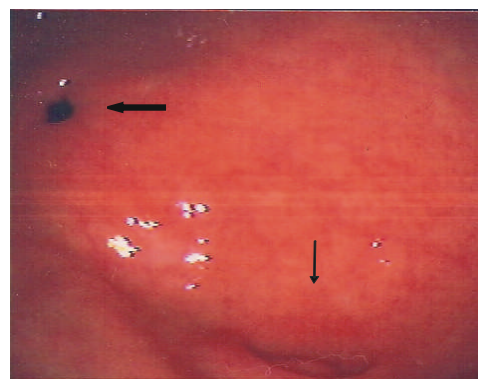


Figure 1: Antral diverticulum (thin arrow) shown in relation to the pyloric ring (thick arrow)

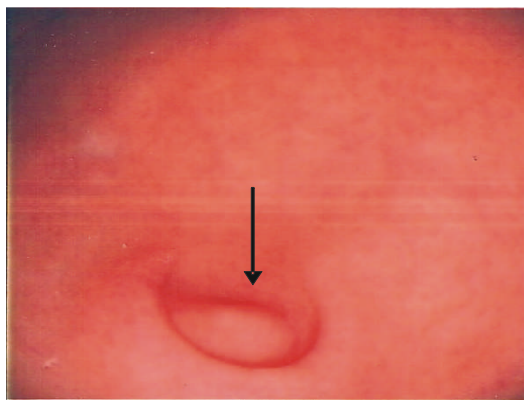


Figure 2. The same antral diverticulum (arrowed).

DISCUSSION

Though gastric diverticula have been found to occur in all ages, but typically in the 5th to 6th decade⁵, our patient was aged 33 years at the time of discovery of her diverticulum. A younger patient who was 11 years old has also been reported in literature⁷.

While most gastric diverticula occur in the posterior wall of the cardia near the lesser curvature close to the oesophago-gastric junction the partial type occurs commonly in the pre-pyloric antrum. They vary in size from 1cm to 10 cm in diameter, and are usually single. The diverticulum reported in this case was located in the antrum, was single and about 1 cm in diameter. However, occurrence of multiple pre-pyloric diverticula has been reported⁸.

There are several predisposing factors to diverticula formation as stated above. In our patient at least one factor appears to be evident. It is possible that the antral gastroduodenitis she had was a predisposing factor to the formation of the diverticulum. It may even have been present at the first endoscopy but missed due to effect of gastric peristalsis.

When a gastric diverticulum is discovered it is important to ascertain whether the diverticulum is responsible for the patient's symptoms, whether it is complicated and whether treatment is indicated¹. The fact that a diverticulum could be responsible for a patient's dyspeptic symptoms was reported by Anaise et al of a patient whose pain was reproduced by gently probing the diverticulum at endoscopy with a biopsy forceps,⁹ and the patient's symptoms resolved after diverticulectomy. The patient presented in our report most likely had an asymptomatic diverticulum. The presence of antral gastroduodenitis when she had symptoms and the resolution of dyspeptic symptoms when the antral and duodenal inflammation subsided confirms this. The diverticulum appeared normal and uncomplicated and probably may not need treatment.

Although endoscopy is the mainstay of diagnosis in gastric diverticular disease, diagnosis can also be made by contrast studies; though contrast studies may miss up to 5% of lesions⁵. A fundal diverticulum may look like a para-oesophageal hernia endoscopically¹ and smaller diverticula can also be confused with gastric ulcers or even cancers.

Complications of gastric diverticula are uncommon, but

can be life-threatening. Ulceration and gastrointestinal bleeding can occur¹⁰, and gastrointestinal bleeding can be severe enough to cause haemorrhagic shock¹¹, and even necessitate laparotomy⁵. There could be perforation, torsion, pyloric obstruction¹² and malignant transformation¹³. Diverticulitis however appears to be rare as the mouth of the diverticulum is relatively wide.

Treatment is rarely needed, but when complications arise patients may require laparotomy with diverticulectomy. The laparoscopic approach has also been used as a minimally invasive option to laparotomy¹⁴. To our knowledge there is no case of gastric diverticulum that has been reported from Nigeria.

CONCLUSION

Gastric diverticulum is rare and usually asymptomatic. To our knowledge this is the first case report from Nigeria.

REFERENCES

1. Velanovich V. Gastric diverticulum. Endoscopic and radiologic appearance. *Surg. Endosc.* 1994; **8**:1338-1339.
2. Rodeberg D. A., Zaheer S, Moir CR, Ishitani MB. Gastric diverticulum: a series of four pediatric patients. *J Pediatr Gastroenterol Nutr.* 2002; **34**: 564-567.
3. Raffin B. Diverticula, rupture and volvulus. In: *Gastrointestinal disease, pathophysiology diagnosis management*. Sleisenger MH, Fordtran KS (editors). 5th ed. Philadelphia: *WB Saunders*. 1989; 735-742.
4. Palmer E. D. Gastric diverticulosis. *Am. Fam. Physician.* 1973; **7**: 114.
5. LaJoie A., Strum W. B. Gastric diverticulum presenting as acute hemorrhage. *Gastrointest Endosc* 2008; **67**(1): 175-176.
6. Cruz C., Siriwardena A. K. Proximal gastric diverticulum after anterior lesser curve seromyotomy. *Dig Surg* 2001; **18**(3): 221-222.
7. Atmani S, Boujraf S, Rami S, Khattala K, Kamaoui I, Hida M et al. Gastric diverticulum in the child: Disease or radiological curiosity? *African Journal*
8. Schweiger F., Noonan J. S. An unusual case of gastric diverticulosis. *Am J Gastroenterol* 1991; **86**(12): 1817-1819.
9. Anaise D, Brand DL, Smith NL, Soroff HS. Pitfalls in the diagnosis and treatment of asymptomatic gastric diverticulum. *Gastrointest Endosc* 1984; **30**: 28-30.
10. Gibbons CP, Harvey L. An ulcerated gastric diverticulum- a rare cause of haematemesis and melaena. *Postgrad Med J* 1984; **60**: 693-695.
11. Perbet S., Constantin J. M., Poincloux L., Privat J., Bannier F., Cavot-Contantin S et al. Gastric diverticulum: a rare cause of haemorrhagic shock. *Intensive Care Med* 2008; **34**(7):1353-1354.
12. Probst J. G., Sachar L. A. Pyloric obstruction due to a gastric diverticulum; report of a case. *Mo Med.* 1948; **45**(4):276.
13. Fork F. T., Toth E., Lindstrom C. Early gastric cancer in a fundic diverticulum *Endoscopy.* 1998; **30**(1): S2.
14. Donkervoort S. C., Baak L. C., Blaauwgeers J. L., Gerhards MF. Laparoscopic resection of a symptomatic gastric diverticulum: a minimally invasive solution. *J S L S.* 2006; **10**(4): 525-527.