

## A case of Subconjunctival Filariasis in Abuja, Nigeria.

\*Adaora C Okudo, Olufemi E Babalola

Rachel Eye Center, Garki. Area 11, Abuja, Nigeria.

### Abstract

The report presents a case of subconjunctival filariasis in a 20-year-old female student who schools in Oye-Ekiti, Ekiti State, a known loa loa endemic region in Nigeria, and resident in Abuja. The patient presented on the 20<sup>th</sup> of February 2020, with a history of foreign body sensation and itching on two occasions within a 6-month period and had video evidence of a worm in her left eye. The worm was however not visualized in the clinic. She was placed on tabs Albendazole 20mg twice daily for 21 days and has not felt or seen the worm since she completed the medications. Subconjunctival filariasis is still an issue of concern in the rainforest region of Nigeria.

**Keywords:** Subconjunctival; Filariasis; Loa Loa; Nigeria.

### Introduction

Filariasis is still of concern in Nigeria as cases of ocular involvement are increasingly being reported even in the 21st century. Four cases of subconjunctival involvement were reported in a case series in 2018<sup>[1]</sup> and two cases of loaloa in the anterior chamber that led to vision loss following an aggressive chronic pan uveitis was reported in 2008 and 2016<sup>[2,3]</sup>. Majority of cases reported on ocular loasis has mainly been cases of migration from endemic to non-endemic regions<sup>[4,5,6]</sup>.

The Loa endemic region in Nigeria spans across the rainforest and guinea savannah (Figure 1). These regions are also conventional rubber plantation areas. Humans are affected by bites of the Deer fly (*Chrysopsilacea* and *dimidata* family *Tabanidae*) mainly during the day which then transmits the filaria into the body. The worm often then migrates to the eye<sup>[7]</sup>. Following a blood meal, an infected fly introduces the third-stage filarial larvae onto the skin of the human host. The larvae develop into adults that commonly reside in subcutaneous tissue

and can then migrate to the subconjunctival location. The adults produce microfilariae which are sheathed and have diurnal periodicity, during the day they are found in peripheral blood and when not in circulation reside in the lungs. The fly then ingests microfilaria during a blood meal and the microfilaria then loses their sheaths and migrate from the fly's midgut through the hemocoel to the thoracic muscles. During this migration it develops from the first stage larvae to the third-stage infective larvae. After which it migrates to the fly's proboscis and infect another human during another blood meal<sup>[8]</sup>.

Ocular presentation can range from benign<sup>[1]</sup> to sight threatening<sup>[8]</sup>.

**Corresponding Author:** \*Okudo Adaora Chinwendu  
Rachel Eye Center, 23 Onitsha Crescent, Off Gimbya  
Street, Garki Area 11. Abuja  
adaoraokudo@gmail.com

This is an open access journal, and articles are distributed under the terms of the Creative Commons Attribution-Non Commercial-Share Alike 4.0 License, which allows others to remix, tweak, and build upon the work non-commercially, as long as appropriate credit is given and the new creations are licensed under the identical terms.

**How to cite this article:** Okudo AC, Babalola OE. A case of Subconjunctival Filariasis in Abuja, Nigeria. *Niger Med J* 2022;63;(2): 176-180

Access this article online

Quick Response Code:



Website:

www.nigerianmedjournal.org

The purpose of reporting this case is because of its rare presentation within the Federal Capital Territory, a non-endemic urban region of Nigeria and the need for awareness of residence in endemic regions of Nigeria as a risk for ocular filariasis as is most likely in this case. It is also important to mention that this case shows the need to screen for filariasis in patients presenting with persistent ocular symptoms that are suggestive of filariasis even in a non-endemic region. This case also shows that undiagnosed and untreated ocular filariasis still remains a risk for blindness in Nigeria. Another lesson from the case is the diagnostic difficulty encountered. Also, the importance of video recording of symptoms by patients for doctors to visualize patients' symptoms and to discuss our management of this case.

### Ethics statement

Informed consent to report this case report was gotten from the patient verbally in the clinic and also via a phone conversation. The consent was documented in the patient's case notes. The research was in accordance to the Helsinki declaration.

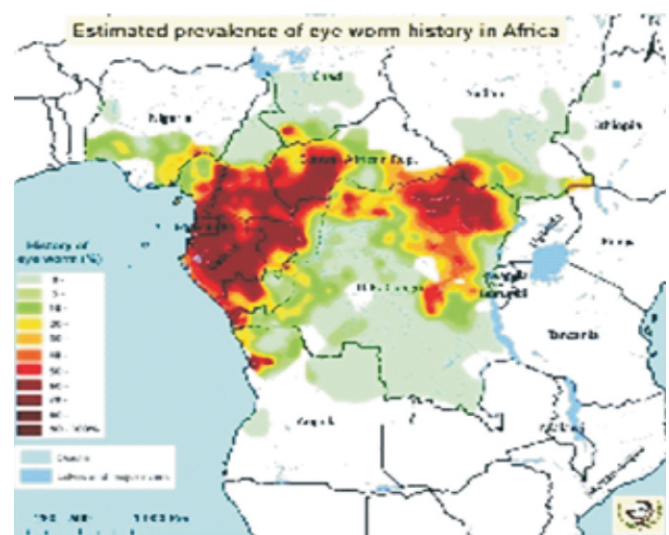
### Case Presentation

A 20-year-old student presented to the hospital on the 20th of February 2020 with a five day history of "worm in the left eye". The symptom started 6 months prior to presentation, when she felt a foreign body in her eye for 48 hours and asked a friend to look and her friend observed that there was a worm moving in her eye. The second time she had the symptom was 5 days prior to presentation, at this time it was a very painful and irritating feeling to the eye. There was associated itching, tearing and redness, blurred vision and loss of sleep at night because of the discomfort. The discomfort was worse when she closed her eyes. There was no second eye involvement, no skin masses, nodules or lesions. She resides in Karshi LGA, Abuja and schools in Oye Ekiti in Ekiti State, South-western Nigeria.

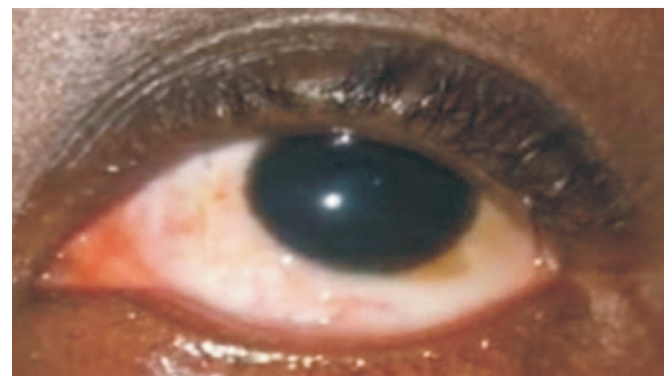
She grew up in Asokoro, Abuja with her family up until her late teens when she started her tertiary Education in Oye- Ekiti. The symptoms started when she was 20 years of age while she was in Oye-Ekiti. She went to the stream in Oye-Ekiti on a few occasions and to the mountains several times.

She claims not to have been involved in farming nor did she experience unusual bites.

Ocular examination revealed visual acuity of 6/5 and Intraocular pressures of 12mmHg in both eyes. Her conjunctiva was examined in the clinic, thoroughly on 3 occasions within a week and no worm was seen. However, the patient had video evidence of the worm, the video was taken in her home, prior to her first visit to the clinic (Figure 2). Anterior and posterior segment examinations of both eyes were normal. After three visits during which we could still not see the worm to surgically extract it, she was placed on tabs albendazole 200mg bd for 21 days. She subsequently stopped seeing or feeling the worm in the eye after treatment was completed. She completed her treatment on the 13th of March 2020 and there has been no feeling of the worm in her eye since then.



**Figure 1:** Map of the estimated prevalence of eye worm history in Africa. Cited from <https://www.who.int/apoc/raploa/en/>



**Figure 2:** Subconjunctival filarial

## Discussion

Loaloa is also called the African eye worm. Nigeria lies within the loaloa belt which cuts across the rain forest and some regions of the Guinea-savannah vegetation belt in West Africa (Figure 1). The estimated prevalence of eye worm history in Ekiti state, Nigeria is 20%<sup>[9]</sup>. Ekiti State falls within the rain forest and is a conventional rubber plantation area in Nigeria. These are risk factors for the vector of Loaloa which is the Deer fly (*Chrysopsrelictus*). The Deer fly is said mainly to bite during the day, at which time the filaria is transmitted to humans<sup>[8]</sup> Our patient most likely got exposed to loaloa in Ekiti State. She attested to exposure to muddy water streams, which also increased her risk. Our patient presented in Abuja which is not an endemic region for Loaloa. This is usually the case with loiasis as most documented cases have arisen from patients travelling from endemic regions to non-endemic areas<sup>[5,6]</sup>.

She presented mainly with features of subconjunctival location of the worm as has been documented in several studies<sup>[1]</sup>, Other studies have also described intraocular (within the anterior chamber)<sup>[2,3,10,11]</sup> and intradermal ocular adnexa<sup>[4]</sup> presentation. Ocular features can be confused with allergy especially when the worm is not seen by the physician.

Physicians should not under look patient's complaints of worm in the eye even if it is not visualized in the clinic. The patient should be encouraged to take pictures or videos, when ever they feel the symptoms again.

Another reported way of visualizing the worm in the clinic after thorough examination is to ask the patient to bend down with head faced down for about 30 minutes as this was shown to make the worm move to subconjunctival location<sup>[1]</sup>.

We did not visualize the worm but due to the video evidence we treated her for subconjunctival filariasis with tabs Albendazole 200mg twice daily for 21 days. She has not had any wormlike feeling in her eye since the 13th of March 2020 after her treatment.

Mebendazole and albendazole (benzimidazoles),

are antihelmintics with a broad spectrum that bind to the colchicine-sensitive site of the parasite  $\beta$ -tubulin, inhibiting its polymerization or assembly into microtubules hence causing disruption of microtubules. These microtubules are vital in promoting glucose uptake in larval and adult stages of the parasites hence depleting the glycogen stores of the parasites. These drugs also cause degenerative changes in the endoplasmic reticulum, the mitochondria of the germinal layer in the teguments and intestinal cells and release of lysosomes result in decreased production of adenosine triphosphate (ATP) hence depleting the energy needed for the survival of the helminth. These changes lead to death of the parasite<sup>[1,2]</sup>.

Studies have revealed that high doses of mebendazole is effective against adult worms of LoaLoa, but for its adverse effects and poor and variable absorbance, makes it have a limited use in treating loiasis. However, Albendazole a related benzimidazole has a wider spectrum of activity and high oral bioavailability<sup>[14]</sup>.

A double-blind placebo-controlled trial showed that albendazole 200mg given two times a day for 21 days causes microfilaria levels of patients with loiasis to reduce gradually. For those that received albendazole, microfilaria levels started to decline 14 days after commencing treatment and at 6 months had dropped significantly to 20% of pretreatment levels as compared to 84.8% in the placebo group. This gradual decline in microfilaria level explains the primary effect possibly an embryotoxic effect of the drug on the adult parasite. The eosinophil, IgG and IgG4 levels were also noted to have dropped significantly as well. Albendazole when used on patients with very high microfilaria levels did not show clinical adverse effects, hepatotoxicity, renal toxicity or hematological abnormalities<sup>[15]</sup>. As compared with DEC when given in cases of high microfilaremia even at slow dose increases given alongside with steroid use still caused severe side effects such as renal failure and fatal encephalopathy<sup>[16]</sup>.

Ivermectin on the other hand is effective against the microfilariae but not the adult worm, also when used to treat patients with high microfilaremia reports of fatal encephalopathy has been reported<sup>[17,18]</sup>.



Interesting note that there have been documented shorter courses of albenadazole treatment to 3 days that have significantly reduced the microfilaria level<sup>[19,20]</sup>. There are also reports of albendazole successfully treating 3 patients with symptomatic loasis that did not respond to DEC<sup>[21]</sup>. Albendazole has been used as primary treatment of loasis<sup>[16,17,18]</sup>, to treat refractory cases of DEC treatment<sup>[19]</sup> and as an adjunct alongside with DEC. We choose to use albendazole because of its safety as compared to other drugs such as DEC and Ivermectin.

Our patient was encouraged to carry out the usual investigations: a full blood count which might show eosinophilia, an afternoon thick blood smear in line with the normal periodicity of the worm, and skin snip to rule out other filarial problems especially onchocerciasis, but the patient declined to carry out these tests. Loaloe exhibit diurnal periodicity and a diagnosis is best made from blood collected during the mid-day (10 AM-2 PM). The presence of Calabar swellings can aid in the diagnosis.

Although we did not carry out a blood smear to confirm the diagnosis of Loaloe as stated above which was a limitation in the study, the visualization of the subconjunctival location of the worm in (figure 2) is highly indicative of loaloe infestation.

Differential diagnosis: Other filarial ocular infestations in Nigeria include *Onchocerca volvulus*, but the microfilaria of *Volvulus* is much smaller and typically found in skin snips and in the anterior chamber aqueous fluid, while the adult worm dwell in the nodules around the head, waist and knees. *Mansonellaperstans* is another filarial disease which can be confused with *Loa* in thick smears, but it is much smaller. Also, it does not cause angioedema or subconjunctival disease.

Sometimes patients who suffer from Loaloe infection, present with an edematous angioedematous swelling called Calabar swelling. However, not all cases of *Loa loa* have this presentation, and this was not the case in the patient under discussion.

In conclusion subconjunctival filariasis still a source of concern in the rainforest region of Nigeria. There is a need to determine the present burden of

this problem in regions of Nigeria known to be endemic for Loaloe and other filaria.

## References

1. Okonkwo ON, Hassan AO, Alarape T, Akanbi T, Oderinlo O, Akinye A, et al. Removal of adult subconjunctival *Loa loa* amongst urban dwellers in Nigeria. *PLOS Neglected Tropical Diseases* **12**: e0006920.
2. Pedro-Egbe CN, Chukwuka IO, Obunge OK. Live adult *Loa-Loa* in the anterior chamber of a Nigerian female. *Port Harcourt Medical Journal*. 2008;**3**:104-107.
3. Hassan S, Isyaku M, Yayo A, Sarkin Fada F, Ihesiulor GU, Iliyasu G. Adult *Loaloe* Filarial Worm in the Anterior Chamber of the Eye: A First Report from Savanna Belt of Northern Nigeria. *PLOS Neglected Tropical Diseases* 2016;**10**: e0004436.
4. Ahmad N, Indirawati M, Sirajuddin J, Wahyuni S. Subconjunctival Loiasis: A Rare Case Report. *J Case Rep Images Ophthalmol* 2018;**1**:100006Z17NA2018.
5. Carbonez G, Van De Sompel W, Zeyen Bull T. Soc Belge Ophtalmol Subconjunctival *Loaloe* Worm: *Case Report* 2002;45-8.
6. Verallo O, Fragiotta S, Carnevale C, De Rosa V, Vingolo EM. [Subconjunctival Loiasis: case reports and review of cases described in Italy]. *Clin Ter*. 2013;**164**:127-31.
7. Padgett JJ, Jacobsen KH. Loiasis: African eye worm External. *Transactions of the Royal Society of Tropical Medicine and Hygiene* 2008; **102**: 983–89
8. Center for disease control and prevention. Loiasis, life cycle of *Loaloe*. [Internet] Content source: CDC: Global Health, Division of Parasitic Diseases and Malaria; USA [Updated 2020/09/23; cited 2022/03/12]. Available from <https://www.cdc.gov/dpdx/loiasis/index.html>.
9. Zoure HGM, Wanji S, Noma M, Amazigo UV, Diggle PJ, et al. (2011) The Geographic Distribution of *Loa loa* in Africa: Results of Large-Scale Implementation of the Rapid Assessment Procedure for Loiasis (RAPLOA). *PLoS Negl Trop Dis* **5**: e1210. doi:10.1371/journal.pntd.0001210
10. Osuntokun O, Olurin O. Filarial Worm

- (Loaloa) In The Anterior Chamber. Report Of Two Cases. *Brit. J. Ophthalmol.* 1975 ; **59**: 166.
11. Barua P, Barua N, Hazarika NK, Das S. Loaloa In The Anterior Chamber Of The Eye: *A Case Report Indian J Med Microbiol.* 2005; **23**:59-60.
  12. Klion AD. Loaloa Antimicrobe [Internet] 1401 Forbes Ave. Suite 208, Pittsburgh, PA 15219, USA. E-Sun Technologies, Inc. [Cited on 2022/03/12]. Available from <http://www.antimicrobe.org/b14.asp>.
  13. Wishart DS, Feunang YD, Guo AC, Lo EJ, Marcu A, Grant JR, et al. DrugBank 5.0.2017. A major update to the DrugBank database for 2018. *Nucleic Acids Res.* doi:10.1093/nar/gkx1037.
  14. Van Hoegaerden M, Flocard F, Salle A, Chabaud B. The use of mebendazole in the treatment of filariases due to Loaloa and Mansonella perstans. *Ann Trop Med Parasitol* 1987; **81**:275-82.
  15. Klion, Amy D, Massougboji A, Horton J, Ekoué S, Lanmasso T, Ahouissou NL, et al. "Albendazole in Human Loiasis: Results of a Double-Blind, Placebo-Controlled Trial." *The Journal of Infectious Diseases* 1993; **168**: 202–6.
  16. Carme B, Boulesteix J, Boutes H, Puruehnce MF. Five cases of encephalitis during treatment of loiasis with diethylcarbamazine. *Am J Trop Med Hyg* 1991; **44**:684-90.
  17. Boussinesq M, Gardon J, Gardon-Wendel N, Kamgno J, Ngoumou P, Chippaux JP. Three probable cases of Loa loa encephalopathy following ivermectin treatment for onchocerciasis. *Am J Trop Med Hyg* 1998; **58**:461-9.
  18. Chippaux JP, Boussinesq M, Gardon J, Gardon-Wendel N, Ernoult JC. Severe adverse reaction risks during mass treatment with ivermectin in loiasis-endemic areas. *Parasitol Today* 1996; **12**:448-50.
  19. Tabi TE, Befidi-Mengue R, Nutman TB, Horton J, Folefack A, Pensia E, et al. Human loiasis in a Cameroonian village: a double-blind, placebo-controlled, crossover clinical trial of a three-day albendazole regimen. *Am J Trop Med Hyg* 2004; **71**:211-5.
  20. Tsague-Dongmo L, Kamgno J, Pion SD, Moyou-Somo R, Boussinesq M. Effects of a 3-day regimen of albendazole (800 mg daily) on Loaloa microfilaraemia. *Ann Trop Med Hyg* **98**:707-15.
  21. Klion AD, Horton J, Nutman TB. Albendazole therapy for loiasis refractory to diethylcarbamazine treatment. *Clin Infect Dis* 1999; **29**:680-2.