

# Routine Histopathological Analysis of the Products of Conception: Is there a Value?

Samuel Robsam Ohayi, Nnaemeka Thaddeus Onyishi

Department of Histopathology, Enugu State University Teaching Hospital and College of Medicine, Parklane, Enugu, Nigeria

## Abstract

**Background:** Spontaneous miscarriage is one of the two most common problems encountered in the first trimester of pregnancy. The value of histopathological analysis of products of conception (POC) obtained as a result is a source of controversy. The aim of this study is to evaluate the histopathological characteristics of suspected POC following the first-trimester miscarriage and determine the clinical value of such histopathological analyses. **Materials and Methods:** This is a retrospective study of the histopathological analysis of POC over a period from January 1<sup>st</sup> to December 31<sup>st</sup> of 2016 carried out in the histopathology laboratory of a university teaching hospital. Materials for the study were POC obtained following spontaneous first trimester miscarriage and received in our laboratory. Relevant information about the patients was retrieved from the laboratory database and matched with laboratory request forms and copies of histopathology reports archived in the laboratory. Obtained data were analyzed by simple statistical methods. **Results:** The most common clinical diagnosis on admission was incomplete abortion ( $n = 52$ ; 48.6%), followed by complete abortion ( $n = 31$ ; 29.0%); the lowest was blighted ovum ( $n = 1$ ; 0.9%). The predominant histopathological type was normal POC which constituted 73 cases (68.2%). Other histopathological diagnoses include hydatidiform mole (9, 8.4%) and no evidence of conception (15, 14%). Clinical and ultrasound evaluation missed 2 (22.2%) of the 9 histopathologically diagnosed hydatidiform moles. **Conclusion:** Histopathological analysis of POC helps to diagnose molar pregnancies and other conditions which can be missed by clinical and ultrasound evaluation. Therefore, routine histopathological analysis of POC is advocated.

**Keywords:** Chorionic villi, histopathology, molar pregnancy, product of conception, spontaneous miscarriage

## INTRODUCTION

Spontaneous miscarriage (spontaneous abortion) is one of the two most common problems encountered in the first trimester of pregnancy.<sup>1</sup> Spontaneous miscarriage is defined as involuntary, spontaneous loss of a pregnancy before 20–24 completed weeks.<sup>2</sup> The worldwide incidence of spontaneous miscarriage is not known, though some studies document a range of 10%–20% occurring within the first trimester, a period defined as the first 12–14 weeks of gestation.<sup>3</sup> Of this, about 80% occur in the first 12 weeks of gestation.<sup>4-6</sup>

Opinion varies on the value of histopathological analysis of the products of conception (POC).<sup>7,8</sup> Such analysis consists of gross and microscopic examination of tissues received in the histopathology laboratory. In our center, POC passed spontaneously or evacuated surgically or medically are routinely subjected to histopathological examination.

This study aimed at evaluating the histopathological characteristics of suspected POC following the first-trimester miscarriage to determine whether such evaluation is clinically useful.

## MATERIALS AND METHODS

This study was a retrospective study in which the histopathological reports of POC submitted to the histopathology laboratory of a university teaching from January 1<sup>st</sup> to December 31<sup>st</sup> of 2016 were retrieved, reviewed, and analyzed. The patients in the study are women whose

**Address for correspondence:** Dr. Samuel Robsam Ohayi,  
Department of Histopathology, Enugu State University Teaching Hospital and  
College of Medicine, Parklane, GRA, Enugu, Nigeria.  
E-mail: robhay@yahoo.com

**Submitted:** 21-Dec-2019 **Revised:** 16-Feb-2020

**Accepted:** 20-Mar-2020 **Published:** 04-Jul-2020

This is an open access journal, and articles are distributed under the terms of the Creative Commons Attribution-NonCommercial-ShareAlike 4.0 License, which allows others to remix, tweak, and build upon the work non-commercially, as long as appropriate credit is given and the new creations are licensed under the identical terms.

**For reprints contact:** WKHLRPMedknow\_reprints@wolterskluwer.com

**How to cite this article:** Ohayi SR, Onyishi NT. Routine histopathological analysis of the products of conception: Is there a value? Niger Med J 2020;61:136-9.

### Access this article online

#### Quick Response Code:



**Website:**  
www.nigeriamedj.com

**DOI:**  
10.4103/nmj.NMJ\_242\_19

POC following a spontaneous miscarriage in the first trimester were received and analyzed in the histopathology laboratory of the hospital. The records of the patients, including age, gestational age, clinical diagnosis (on admission), and method of evacuation of retained POC (RPOC), among other relevant information were retrieved from the laboratory database and matched with that in the laboratory request forms which had been received with the specimen and archived in the laboratory to ensure harmony. Copies of histopathology reports archived in the laboratory were also retrieved, and diagnosis and gross and histological features were extracted, whereas slides, tissue blocks, and/or gross specimens were also reviewed in cases where doubt existed about the report.

Routinely, suspected POC received in our laboratory were put in a solution of 10% formalin for fixation. Each sample is examined macroscopically by a histopathologist who as part of the process takes blocks of the tissue to be embedded in paraffin blocks for processing. Thereafter, the paraffin blocks were sectioned with the aid of a microtome into 4  $\mu$ - thick sections which were then stained using hematoxylin and eosin after fixing to a glass slide. Stained sections were microscopically examined by a histopathologist for the presence of fetal tissues, trophoblasts, or chorionic villi in the sections to confirm or rule out conception. Other features that could be observed including abnormalities of chorionic villi, presence of deciduae without chorionic villi, and absence of POC were also noted when seen.

Ethical approval was obtained from the ethics committee of the hospital and the codes of ethics of the Declaration of Helsinki were adhered to. Obtained data were analyzed by simple statistical methods for percentages and frequencies. Cases with incomplete patient information or in which doubt existed about the archived laboratory report but the specimen was missing were excluded from the study.

## RESULTS

During the period under review, 110 specimens were received in our histopathology laboratory with clinical diagnosis of POC, out of which three were excluded from this study for various reasons. The 107 specimens studied constituted 11.7% of all specimens received in the laboratory in the period. Age distribution of patients is shown in Table 1 with the average age of patients as  $29.02 \pm 8.1$  years standard deviation (SD) and range as 18–48 years. The age group of 21–30 years has the highest incidence of spontaneous abortion ( $n = 53$ ; 49.5%). The mean parity was  $3.6 \pm 2.5$  SD, whereas range was 0–7. A total of 7 (6.5%) patients gave a history of at least one episode of miscarriage in the past.

As shown in Table 2, the most common clinical diagnosis on admission was incomplete abortion ( $n = 52$ ; 48.6%), followed by complete abortion ( $n = 31$ ; 29.0%), whereas the lowest was blighted ovum ( $n = 1$ ; 0.9%). Clinical diagnosis was based of clinical findings and was confirmed by ultrasound findings where necessary; this diagnosis guided the choice of management adopted for each patient. Complete abortion was

confirmed by ultrasound in 29 patients (27.1%), and therefore any intervention was not needed, whereas surgical and medical evacuation of RPOC were done in 64 cases (59.8%) and 14 cases (13.1%), respectively.

The predominant histopathological diagnosis was normal POC [Figure 1] which constituted 73 cases (68.2%). Other histopathological diagnoses [Table 3] were hydatidiform mole (9, 8.4%) and no evidence of conception (15, 14%). Of the histopathologically diagnosed hydatidiform moles, 2 (22.2%) were missed by clinical and ultrasound evaluation.

## DISCUSSION

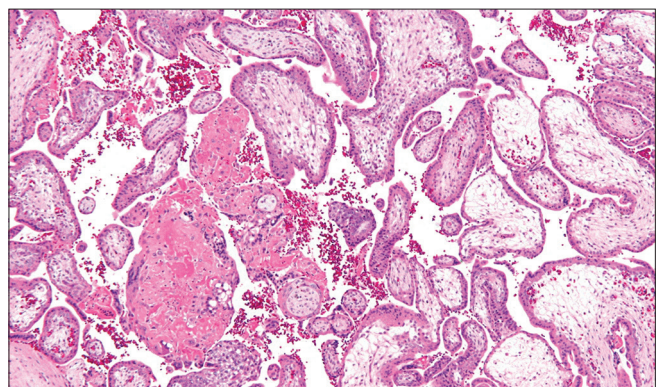
Prompt and correct diagnosis of POC is important for the overall well-being of a patient who suffers miscarriage. This is especially so in an environment like ours where managing the potential complications of undiagnosed or wrongly diagnosed condition is a reasonable challenge and where childbearing is a major source of anxiety among the married. In our sociological context, a childless woman feels some degree of

**Table 1: Age distribution of patients**

Age group (years)	n (%)
$\leq 20$	10 (9.3)
21-30	53 (49.5)
31-40	39 (36.5)
$\geq 40$	5 (4.7)
Total	107 (100)

**Table 2: Diagnosed type of abortion on admission**

Clinical diagnosis	n (%)
Incomplete	52 (48.6)
Complete	31 (29.0)
Missed	11 (10.3)
Blighted ovum	1 (0.9)
Inevitable	8 (7.5)
Septic	4 (3.7)
Total	107 (100)



**Figure 1:** Photomicrograph showing the normal product of conception – chorionic villi with normal trophoblastic rimming, no hydropic stromal change and the presence of blood vessels

**Table 3: Histological diagnosis of products of conception**

Histological diagnosis	n (%)
Normal product of conception	73 (68.2)
Decidual/Arias-Stella reaction	8 (7.5)
Molar pregnancy (partial)	8 (7.5)
Molar pregnancy (complete)	1 (0.9)
No feature of pregnancy/no POC	15 (14.0)
Fetal parts	2 (1.9)
Total	107 (100)

POC – Product of conception

social safety if she had had a pregnancy confirmed (including histologically) even if it ended in spontaneous miscarriage than if it had never been confirmed that she could conceive. Furthermore, on clinical grounds, according to one report from a survey, abortion-related complications contribute about 7% of maternal mortality in Nepal.<sup>9</sup> Beta-human chorionic gonadotropin assay, abdominopelvic ultrasound scan, and histopathological analysis of recovered uterine content are the methods of reaching this diagnosis. Although clinical history and ultrasound scan can help to determine the type of miscarriage, sometimes histopathological evaluation may be required to confirm the nature of POC or to differentiate a miscarriage from other clinical conditions that may present in like manner, thereby making an accurate diagnosis.

The usefulness of histopathological analysis of POC is still a source of debate among researchers and clinicians. For its advocates, routine histopathological examination of POC following a spontaneous miscarriage is necessary because it helps to establish that there was an intrauterine pregnancy and to diagnose or rule out molar pregnancy.<sup>5,7,10</sup> Some also believe that it is useful in protecting clinicians from litigation for instance in missed ectopic pregnancy or subsequent gestational trophoblastic disease (GTD) situations which outcomes may lead to claims of negligence by patients.<sup>11</sup> Histopathological analysis of RPOC can also help in determining the cause of recurrent miscarriage, especially if complemented with karyotyping.<sup>7,12</sup> In a setting where this author works, the evaluation of POC also has a forensic value. It helps with resolving some women's claim of traumatic abortion following assault, a criminal offense in our legal system, as the absence of POC proven histopathologically will point to other sources of vaginal bleeding including menstruation and therefore absolve an accused especially when there was no other clinical evidence of trauma. However, other researchers argue that histopathological evaluation of POC should be carried out only in cases of specific indication (s), namely diagnostic uncertainty preoperatively or intraoperatively, suspicion of unexpected pathology upon inspecting obtained tissue, or when a smaller amount of tissue than expected is collected following a spontaneous miscarriage.<sup>8,13</sup> In this study, normal POC constituted the most common histopathological diagnosis (68.2%). This is similar to figures reported in other studies.<sup>7,13,14</sup> Other histopathological types were also seen with some having features with noteworthy clinical implications. Molar pregnancy constituted 9 (8.4%) of the cases. This

compares with 4.3% reported by Rashid<sup>14</sup> but is in contrast with the reports by Fram<sup>7</sup> and Alsibiani,<sup>13</sup> which showed far higher (18%) and far lower (0.4%) values, respectively. Of the molar pregnancies, 2 (22.2%) were not detected by clinical and ultrasound evaluation similar to other studies which also reported the values of missed clinical and radiological diagnosis of molar pregnancy ranging from 18% to 64%.<sup>7,15,16</sup> Furthermore, in this study, we found that 14% of cases showed no histological evidence of conception, though RPOC had been diagnosed by clinicians following clinical and ultrasound assessment. This finding is similar to reports from other studies.<sup>13,14</sup> These findings affirm the importance of routinely subjecting POCs to histopathological analysis as done in our center. Similarly, routine histopathological examination of POC is supported by the need to diagnose GTD which can be missed by other diagnostic methods. This is because GTD has relative high incidence in some regions, can persist and therefore cause persistent uterine haemorrhage and other complications and some of them can transform to the malignant variant, choriocarcinoma.<sup>17</sup> In contrast, however, Sellmyer *et al.* from their study of the physiologic, histologic, and imaging features of RPOC concluded that adequate clinical history with certain specific ultrasound findings, namely thickened endometrial echo complex or a vascularized endometrial mass as seen by color and power Doppler ultrasound is sufficient to correctly diagnose RPOC by ultrasonography.<sup>18</sup> Interestingly, these same authors acknowledge that the sensitivity and specificity of ultrasound as a diagnostic tool for RPOC has wide variation since it is based on equally widely variable criteria and the clinical setting.<sup>18</sup>

In this study, the mean age at the time of abortion was  $29.02 \pm 8.1$  years, and most of the patients were in the age group of 21–30 years. These and other age characteristics of the patients as reflected in Table 1 are comparable to findings in other studies.<sup>13,14,19</sup> The most diagnosed clinical condition on admission was incomplete abortion (48.6%), followed by complete abortion (29.0%), whereas the least was blighted ovum (0.9%). These findings are compared with the findings in other studies which reported incomplete abortion as the most common clinical condition at presentation.<sup>7,13,14</sup> However, all three studies documented higher values of missed abortion, though Alsibiani and Rashid independently reported higher values for blighted ovum but lower values for complete abortion in contrast with this study.<sup>7,13,14</sup>

## CONCLUSION

Spontaneous miscarriage is a common gynecologic problem. Histopathological analysis of POC helps with diagnosis of molar pregnancies and determining if there was intrauterine conception at the first instance given that both scenarios could be missed on clinical and ultrasound assessment. Therefore, POC should be routinely subjected to histopathological analysis. This will help prevent missing the diagnosis of either or both conditions which can bring stress on a patient.



## Limitations

Immunohistochemical evaluations were not carried out in this study chiefly because of the unavailability of immunohistochemical equipment in our center; this could have aided in further characterization of these lesions, especially as regards some gestational abnormalities which probably have gone undetected.

## Acknowledgment

The authors would like to thank the laboratory scientists of the Department of Histopathology, ESUT Teaching Hospital, Enugu, for their help with processing the slides for this work.

## Financial support and sponsorship

Nil.

## Conflicts of interest

There are no conflicts of interest.

## REFERENCES

- Whittaker PG, Taylor A, Lind T. Unsuspected pregnancy loss in healthy women. *Lancet* 1983;1:1126-7.
- World Health Organisation, UNICEF, United Nations Population Fund. Vaginal bleeding in early pregnancy. In: *Managing Complications in Pregnancy and Childbirth: A Guide for Midwives and Doctors*. 2<sup>nd</sup> ed. Geneva: WHO; 2017. Available from: [https://www.who.int/maternal\\_child\\_adolescent/en/](https://www.who.int/maternal_child_adolescent/en/). [Last accessed on 2019 Mar 11].
- World Health Organisation. *Safe Abortion: Technical and Policy Guidance for Health Systems*. 2<sup>nd</sup> ed. Geneva: WHO; 2012. Available from: [https://www.who.int/publications/unsafe\\_abortion/en/](https://www.who.int/publications/unsafe_abortion/en/). [Last accessed on 2019 Mar 13].
- Poland BT, Miller JR, Jones DC, Trimble BK. Reproductive counselling in patients who have had a spontaneous abortion. *Am J Obstet Gynecol* 1977;127:685-9.
- Hinshaw K, Fayyad A, Munjuluri P. The Management of Early Pregnancy Loss. Revised Guideline no. 25. Green-top Guideline no. 25. London: Guidelines and Audit Committee of the Royal College of Obstetricians and Gynaecologists; 2006. Available from: <http://www.rcog.org.uk/womens-health/clinical-guidance/management-early-pregnancy-loss-green-top-25>. [Last accessed on 2019 Mar 13].
- de la Rochebrochard E, Thonneau P. Paternal age and maternal age are risk factors for miscarriage; results of a multicentre European study. *Hum Reprod* 2002;17:1649-56.
- Fram KM. Histological analysis of the products of conception following first trimester abortion at Jordan University Hospital. *Eur J Obstet Gynecol Reprod Biol* 2002;105:147-9.
- Heath V, Chadwick V, Cooke I, Manek S, MacKenzie IZ. Should tissue from pregnancy termination and uterine evacuation routinely be examined histologically? *BJOG* 2000;107:727-30.
- Shrestha DR. *Reproductive Health: National and International Perspectives. Abortion Care*. 2<sup>nd</sup> ed. Sanepa Lalitpur, Nepal: Sigma General Offset; 2012.
- Fulcheri E, di Capua E, Ragni N. Histologic examination of products of conception at the time of pregnancy termination. *Int J Gynaecol Obstet* 2003;80:315-6.
- Bagshawe KD, Lawler SD, Paradinas FJ, Dent J, Brown P, Boxer GM. Gestational trophoblastic tumours following initial diagnosis of partial hydatidiform mole. *Lancet* 1990;335:1074-6.
- Farquharson R. The modern preventive treatment of recurrent miscarriage. *Br J Obstet Gynecol* 1996;103:106-10.
- Alsibiani SA. Value of histopathologic examination of uterine products after first-trimester miscarriage. *Biomed Res Int* 2014;2014:863482.
- Rashid PA. The role of histopathological examination of the products of conception following first-trimester miscarriage in Erbil Maternity Hospital. *Zanco J Med Sci* 2017;21:1938-42. <https://doi.org/10.15218/zjms.2017.054>.
- Paradinas FJ. The diagnosis and prognosis of molar pregnancy: The experience of the National Referral Center in London. *Int J Obstet Gynecol* 1998;60 Suppl 1:S57-64.
- Sebire NJ, Rees H, Paradinas F, Seckl M, Newlands E. The diagnostic implications of routine ultrasound examination in histologically confirmed early molar pregnancies. *Ultrasound Obstet Gynecol* 2001;18:662-5.
- Ellenson LH, Pirog EC. The female genital tract. In: Kumar V, Abbas AK, Fausto N, Aster JC, editors. *Robbins and Cotran Pathologic Basis of Disease*. 8<sup>th</sup> ed. Philadelphia: Saunders; 2010. p. 1005-63.
- Sellmyer MA, Desser TS, Maturen KE, Jeffrey RB Jr., Kamaya A. Physiologic, histologic, and imaging features of retained products of conception. *Radiographics* 2013;33:781-96.
- Makaju R, Shrestha S, Sharma S, Dhakal R, Bhandari S, Shrestha A, *et al*. Histopathological changes in the chorionic villi and endometrial decidual tissues in the product of conception of spontaneous abortion cases. *Kathmandu Univ Med J* 2015;52:357-60.