

# Unilateral Sinonasal Masses: Review of Clinical Presentation and Outcome in Ahmadu Bello University Teaching Hospital, Zaria, Nigeria

Iliyasu Yunusa Shuaibu<sup>1</sup>, Muhammed Aminu Usman<sup>1</sup>, Abdulrazak Ajiya<sup>2</sup>

<sup>1</sup>Department of Surgery, Division of Otorhinolaryngology, Ahmadu Bello University, Zaria, Nigeria, <sup>2</sup>Department of Otorhinolaryngology, Bayero University, Kano, Nigeria

## Abstract

**Background:** Unilateral persistent nasal obstruction may indicate the presence of sinonasal lesion, which could be inflammatory or neoplastic. It is a common practice to assume that unilateral nasal mass in adults is either inverted papilloma or a malignant lesion. **Objectives:** The objective is to study the pattern of clinical presentation and outcome of treatment of patients managed for unilateral nasal masses at Ahmadu Bello University Teaching Hospital, Zaria. **Materials and Methods:** The record of patients managed for unilateral nasal masses over 5 years between January 2013 and December 2017 was reviewed. Data obtained for this study included demographic characteristics such as age, sex, occupation, main presenting symptoms, duration of symptoms, histological type, type of treatment given, and current status of patients. The data were analyzed using the Statistical Package for the Social Science version 23.0. **Results:** A total of 38 cases were reviewed for this study and there were 25 (65.8%) males and 13 (34.2%) females with a sex ratio (male: female) of 1.9:1. The mean age was 50.8 years, with the standard deviation of  $\pm 13.7$ . Rhinorrhea, nasal blockage and the presence of nasal growth were the most common symptoms at presentation seen nearly in all the patients. Inflammatory polyp 16 (42.1%) was the most common histological type observed in this study. The majority of patients with malignant sinonasal masses had well-differentiated squamous cell carcinoma 5 (13.2%). Most of our patients 29 (76.3%) presented to the hospital within 1–3 years of the onset of the symptoms. The majority of our patients 26 (68.4%) did very well and were discharged from the clinic following resolution of their symptoms. Three (7.9%) had recurrent nasal mass. We recorded three cases of mortality from the 38 patients managed. **Conclusion:** Inflammatory polyp was the most common unilateral sinonasal mass followed by inverted papilloma. A thorough clinical evaluation of any patients with prolonged nasal symptoms will go a long way in the early detection of these lesions.

**Keywords:** Clinical presentation, inflammatory polyp, outcome, unilateral sinonasal mass

## INTRODUCTION

Patients with sinonasal masses may present to the otorhinolaryngologist with rhinorrhea and nasal obstruction. Unilateral persistent nasal obstruction may indicate the presence of sinonasal lesion which could be inflammatory or neoplastic.<sup>1,2</sup> Although most cases of sinonasal masses are inflammatory polyp, neoplastic lesions do also occur, especially in unilateral pathologies. It is a common practice to assume that unilateral sinonasal mass in adults is either inverted papilloma or a malignant lesion. However, some workers reported simple nasal polyp and squamous cell carcinoma as the most frequent sinonasal lesion.<sup>3</sup> The etiology of nasal polyp is generally unknown; however, certain clinical conditions such as allergy, asthma, infection, aspirin hypersensitivity,

and cystic fibrosis have been found to be associated with it.<sup>4</sup> Patients with unilateral sinonasal masses may present with nasal obstruction, rhinorrhea, epistaxis, facial pain, hyposmia/cacosmia, proptosis, and diplopia.<sup>5</sup> At onset, it may be difficult to differentiate these symptoms from common cold or rhinosinusitis. It is thus imperative to fully evaluate patients presenting with these symptoms by taking thorough

**Address for correspondence:** Dr. Abdulrazak Ajiya,  
Department of Otorhinolaryngology, Bayero University, Kano, Nigeria.  
E-mail: ajiyaabdulrazak@yahoo.com

**Submitted:** 07-Aug-2019 **Revised:** 06-Oct-2019  
**Accepted:** 12-Dec-2019 **Published:** 02-Mar-2020

This is an open access journal, and articles are distributed under the terms of the Creative Commons Attribution-NonCommercial-ShareAlike 4.0 License, which allows others to remix, tweak, and build upon the work non-commercially, as long as appropriate credit is given and the new creations are licensed under the identical terms.

**For reprints contact:** reprints@medknow.com

**How to cite this article:** Shuaibu IY, Usman MA, Ajiya A. Unilateral sinonasal masses: Review of clinical presentation and outcome in Ahmadu Bello university teaching hospital, Zaria, Nigeria. Niger Med J 2020;61:16-21.

### Access this article online

#### Quick Response Code:



**Website:**  
www.nigeriamedj.com

**DOI:**  
10.4103/nmj.NMJ\_128\_19

history, complete head-and-neck examination, endoscopic, and radiological evaluation.<sup>6,7</sup> The complex nature of sinonasal anatomy permits the tumor to grow and fill a particular sinus or nasal cavity before invading the periosteum/perichondrium or bone. This may explain why patient with sinonasal tumors present with late disease. Study has shown that only 25% of maxillary sinus tumors are confined within the antrum at the time of presentation.<sup>8</sup> Sinonasal mass may be diagnosed clinically, endoscopically, radiologically, and pathologically.

The most common benign sinonasal tumor is inverted papilloma. This tumor occurs more frequently in male, with a sex ratio of 3:1.<sup>5</sup> The tumor has tendency of recurrence after excision and can also undergo malignant transformation.<sup>4</sup> Sinonasal squamous cell carcinoma is the most common malignant lesion of the sinonasal region usually arising from the lateral wall of the nose.<sup>8</sup>

There is currently dearth of literature on pattern of presentation and treatment outcome of unilateral sinonasal masses in North Western Nigeria. The aim of this study is to present the pattern of clinical presentation and outcome of treatment of patients managed for unilateral nasal masses at Ahmadu Bello University Teaching Hospital (ABUTH), Zaria.

## MATERIALS AND METHODS

This was a retrospective descriptive study of patients who were managed for unilateral nasal masses at the division of Otorhinolaryngology, Department of Surgery, ABUTH, Zaria, Nigeria. ABUTH is a tertiary health care facility in the North Western Nigeria and is a referral center to many primary, secondary, tertiary, and private health facilities in Nigeria. Ethical approval was obtained from the Ethics Review Committee of ABUTH. The record of patients managed for unilateral nasal masses over a 5-year period between January 2013 and December 2017 was reviewed. Our protocol for managing nasal masses included complete history taking and thorough examination of the head and neck including endoscopic nasal examination where possible. The patient would also undergo radiological investigations and preoperative biopsy. All the preoperative punch biopsies were conducted in the clinic under local anesthesia with the aid of rigid endoscope/bright headlight.

Patients with inflammatory polyp and benign nasal mass were managed with surgical excision and followed up. Approaches used during excision of the masses included intranasal, lateral rhinotomy, Weber Ferguson, and endoscopic, respectively.

All patients with advanced malignant unilateral nasal masses were referred for chemoradiotherapy after excision. Our protocol for follow-up after surgical excision of the sinonasal mass is 6 months for inflammatory and benign lesions, and 5 years for malignant tumors.

Data obtained from this study included demographic characteristics such as age, sex, occupation, main presenting symptoms, duration of symptoms, endoscopic and radiological

findings histological type, type of treatment given, and current status of patients. Excluded from the study were patients whose case records were either not found or did not have complete information. The data were entered into the Spreadsheet and analyzed using the Statistical Package for the Social Sciences version 23.0 software (SPSS Inc., Chicago, Illinois, USA). Quantitative data were summarized as frequencies and percentages, and presented as tables. Fisher's exact test was used to determine *P* value and to test statistical significance, which was set at a *P* < 0.05

## RESULTS

Within the 5-year period of review, 997 sinonasal cases were seen and 49 of them had unilateral sinonasal masses. Only 38 of them fulfilled the inclusion criteria and there were 25 (65.8%) males and 13 (34.2%) females with a sex ratio (male: female) of 1.9:1. The mean age was 50.8 years with the standard deviation of  $\pm 13.7$ . The most common age group affected was 56–65 years, whereas the least affected was 16–25 years, as shown in Table 1.

Rhinorrhea, nasal blockage, and the presence of nasal growth were the most common symptoms at presentation seen nearly in all the patients with nonneoplastic and neoplastic lesions. Epistaxis was observed to be common among patients with neoplastic lesions. Only one patient with nonneoplastic lesion presented with epistaxis. Proptosis and cheek swelling were the least symptoms at presentation and were observed in patients with neoplastic lesions, as shown in Table 2.

Inflammatory polyp 16 (42.1%) was the most common histological type observed in this study with a mean age of 48 years [Figure 1]. Among the 16 patients with inflammatory polyp, 3 had antrochoanal polyp confirmed preoperatively through flexible nasopharyngoscopy.

**Table 1: Age sex distribution of the study population**

Age group (years)	Male	Female	Total (%)
16–25	1	3	4 (10.5)
26–35	3	2	5 (13.2)
36–45	4	1	5 (13.2)
46–55	6	1	7 (18.4)
56–65	11	6	17 (44.7)
Total (%)	25 (65.8)	13 (34.2)	38 (100)

**Table 2: Symptoms at presentation in the study group**

Symptom	Nonneoplastic	Benign	Malignant	Total (%)
Rhinorrhea	16	15	7	38 (100)
Nasal blockage	16	15	7	38 (100)
Mass	16	14	7	37 (94.7)
Epistaxis	1	8	5	14 (36.8)
Facial pain	1	1	4	6 (15.8)
Diplopia	0	1	2	4 (10.5)
Cheek swelling	0	1	1	2 (5.3)
Proptosis	0	1	1	2 (5.3)

Among the benign tumors, inverted papilloma [Figure 2] was the most common accounting for 10 (26.3%) with a mean age of 56 years, followed by pleomorphic adenoma 2 (5.3%) with a mean age of 54 years. The majority of patients with malignant sinonasal masses had well-differentiated squamous cell carcinoma 5 (13.2%) with a mean age of 61 years, as shown in Table 3 and Figure 3.

Majority of the patients 29 (76.3%) presented to the hospital within 1–3 years (average of 1.4 years) of the onset of the symptoms. Up to six (15.8%) patients presented with the history between 10 and 12 years. Overall, the mean duration of mass before presentation was 3.1 years with the standard deviation of  $\pm 3.3$ . Patients with malignant unilateral nasal masses presented earlier than those with the benign lesion. An analysis to find if there is a relationship between the duration of the mass before presentation and nature of the mass was statistically significant (Fisher's exact test  $P < 0.05$ ) [Table 4].

Left sinonasal region was the most common side affected by the mass accounting for 22 (57.9%).

Twenty-four (63.2%) patients had computed tomography scan paranasal sinuses which confirmed unilateral disease involving the nose and or paranasal sinuses. Other patients (36.8%) had X-ray paranasal sinuses showing unilateral soft-tissue shadow/opacification.

Thirty-one (82%) patients with benign unilateral sinonasal masses were managed by surgical excision only. The remaining patients 7 (18%) with malignant tumors were treated with surgical excision and postoperative chemoradiotherapy, as shown in Figure 4.

Twenty-six (68.4%) of our patients were discharged from the clinic following excision and resolution of symptoms. Three (7.9%) had recurrent nasal mass (1 nasal polyp and 2 inverted papilloma). We recorded three cases of mortality from the 38 patients managed (1 natural killer [NK]/T-cell lymphoma and 2 squamous cell carcinoma). Six patients were lost to follow-up as shown in Figure 5.

## DISCUSSION

Unilateral sinonasal masses may be due to neoplastic and nonneoplastic lesions. According to Rudralingam *et al.*,<sup>9</sup> unilateral nasal masses constitute 6% of all sinonasal pathologies. In this study, unilateral nasal masses constitute 4.9% of all sinonasal pathologies.

Majority of the patients (44.7%) in this study presented in the fifth decade at the time of presentation. It has been reported in other studies that patients with neoplastic sinonasal lesions usually present at fifth–seventh decades.<sup>10</sup>

The male-to-female sex ratio in this study was 1.9:1. It has been shown that the incidence of sinonasal tumor in males is twice that of females.<sup>11</sup> However, Humayun *et al.*<sup>12</sup> reported a sex ratio of 3.5:1 in their study.

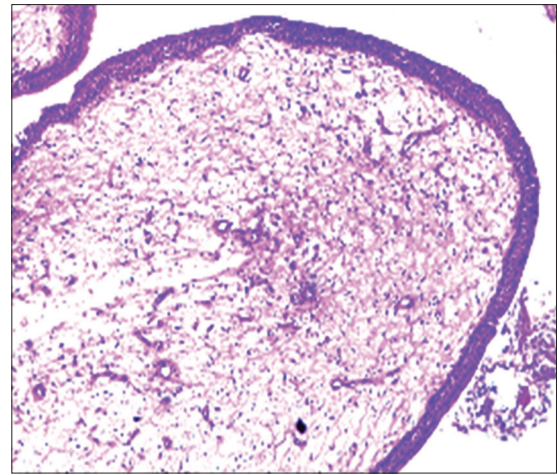


Figure 1: Inflammatory polyp (H and E,  $\times 100$ )

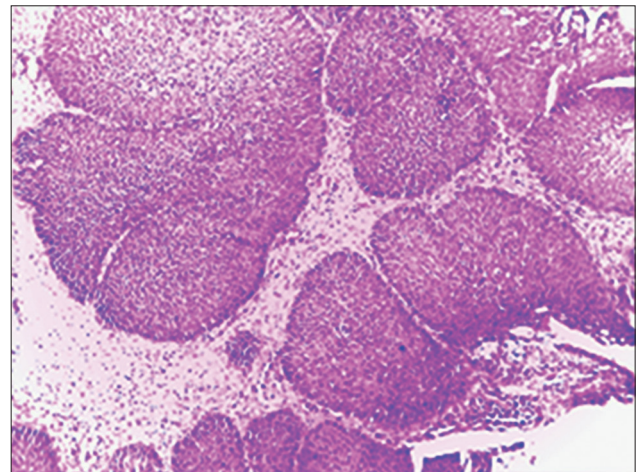


Figure 2: Inverted papilloma (H and E,  $\times 100$ )

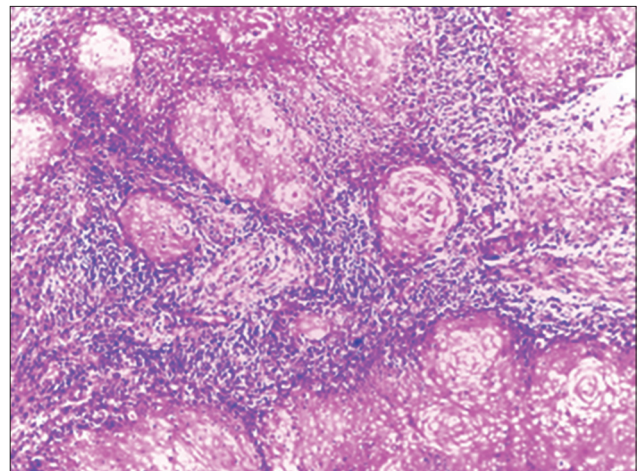


Figure 3: Well-differentiated squamous carcinoma (H and E,  $\times 100$ )

Patients with unilateral nasal masses can present with nasal blockage, rhinorrhea, epistaxis, hyposmia, facial pain, shaky tooth, cheek swelling, diplopia, and proptosis. Nasal blockage was the most common symptom followed by rhinorrhea and

nasal growth in our patients presenting with both neoplastic and nonneoplastic cases. However, epistaxis and facial pain were the predominant symptoms among patients with neoplastic cases. Nair *et al.*<sup>10</sup> also reported nasal blockage as the most common symptom in nonneoplastic cases, with epistaxis and other extra nasal symptoms more common in the neoplastic group. Another study by Tritt *et al.*<sup>13</sup> showed that unilateral nasal masses presenting with epistaxis was significantly associated with neoplastic pathology. Twenty patients had rigid nasal endoscopy, which confirmed the presence of the lesion and its site of origin. In most of them, examination was limited due to either bleeding or the mass completely filled the nose. No mass was found in the

contralateral nasal cavity. In this study, nonneoplastic lesion constitutes 42.1% of all the unilateral nasal masses. In a similar study Kahveci *et al.*<sup>14</sup> reported that 74.2% and 25.2% of their cases were nonneoplastic and neoplastic lesions, respectively. Another study by Gomes *et al.*<sup>15</sup> showed that nonneoplastic and neoplastic lesions were 64.7% and 35.3%, respectively. The predominance of neoplastic lesions in our study may be due to relatively advance age of our patients at presentation.

**Table 3: Histological types of unilateral nasal masses**

Tumor type	Number of patients (%)	Mean age (years)
Nonneoplastic		
Inflammatory polyp	16 (42.1)	48
Benign		
Inverted papilloma	10 (26.3)	56
Pleomorphic adenoma	2 (5.3)	54
Angiofibroma	1 (2.6)	16
Cavernous hemangioma	1 (2.6)	43
Desmoid tumor	1 (2.6)	23
Malignant		
Squamous cell carcinoma	5 (13.2)	61
Rhabdomyosarcoma	1 (2.6)	64
NK/T cell lymphoma	1 (2.6)	45

NK – Natural killer

Histologically, inflammatory polyp was the most common nonneoplastic lesions among our study participants. This compares favorably with the findings of Iseh<sup>16</sup> who reported inflammatory polyp and mucocele as the most common. Kucur *et al.*<sup>17</sup> also reported inflammatory polyp, chronic sinusitis, and antrochoanal polyp as the most common in their study. Another study showed that acute and chronic rhinosinusitis of bacterial and fungal origin were the most common inflammatory lesion reported by Nair *et al.*<sup>10</sup>

Among the benign tumors, inverted papilloma was the most common in this study. It is a benign, but locally aggressive tumor that usually presents as the unilateral fleshy mass that can recur after excision<sup>18</sup> and has 10% incidence of malignant transformation to transitional cell carcinoma.<sup>19</sup> Both synchronous and metachronous occurrences have been described in the literature.<sup>20</sup> All our patients had lateral rhinotomy and medial maxillectomy.

**Table 4: Duration of the nasal mass at presentation**

Duration (years)	Nonneoplastic	Benign	Malignant	Total (%)
1–3	14	8	7	29 (76.3)
4–6	2	0	0	2 (5.3)
7–9	0	1	0	1 (2.6)
10–12	0	6	0	6 (15.8)
Total (%)	16 (62.1)	15 (39.5)	7 (18.4)	38 (100)

Pleomorphic adenoma is the second most common benign tumor in our study. It usually arises from the minor salivary gland of the nose. All the patients had excision of the tumor through endoscopic approach with no recurrence.

Other benign tumors found in this study were angiofibroma, cavernous hemangioma, and desmoid tumor (2.6% each). Angiofibroma is a locally aggressive benign tumor that usually extends to the nasal cavity from the nasopharynx. In recent years, endoscopic approach in the management of angiofibroma is being popularized.<sup>21</sup> Hemangiomas rarely occur in the nasal cavity. We observed one case, which was managed conservatively. In their study, Humayun *et al.*<sup>12</sup> reported inverted papilloma, meningioma, and hemangioma as the most common benign unilateral nasal masses. Another

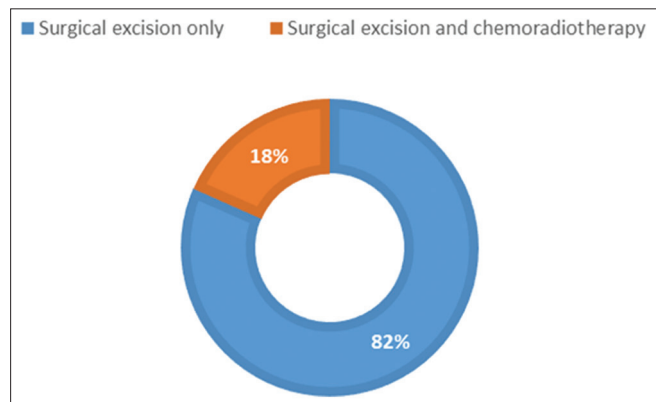


Figure 4: Treatment offered to the patients with nasal mass

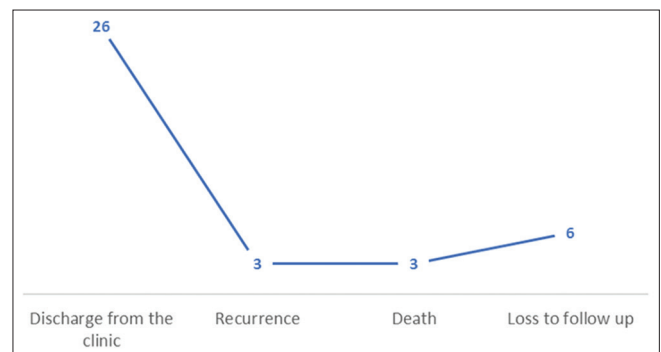


Figure 5: Outcome of treatment among the study population (n = 38)

study reported inverted papilloma, pyogenic granuloma, fibrous dysplasia, osteoma, and hemangioendothelioma as the most common.<sup>17</sup>

Sinonasal malignancy has an incidence of 0.5–1/100,000/year and accounts for 0.2–0.8 of all malignancies and 3% of aerodigestive tract neoplasm.<sup>22</sup> In a report by Ologe *et al.*,<sup>23</sup> it constituted 18% of all head-and-neck malignancies in Ilorin. We found seven patients with unilateral sinonasal malignancy. Squamous cell carcinoma was the most common followed by embryonal rhabdomyosarcoma and NK/T-cell lymphoma. In their study, Nair *et al.*<sup>10</sup> found squamous cell carcinoma, adenocarcinoma, and non-Hodgkin lymphoma as the most common malignant unilateral nasal masses. Squamous cell carcinoma, adenoid cystic carcinoma, and B-cell non-Hodgkin lymphoma were reported as the most common by Belli *et al.*<sup>24</sup>

Majority of our patients presented within 1–3 years of the onset of the symptoms. We observed that all the patients with malignant unilateral nasal masses presented earlier than those with benign lesion. This may be due to aggressive nature of the malignant lesions compare to benign. Furthermore, having symptoms such as epistaxis and facial pain, observed to be more common among our patients with malignant disease, may explain the reason for their early presentation compare to those with benign disease.

Among our patients, we discharged 26 of them from the clinic following surgical excision. Majority had inflammatory polyp and inverted papilloma. Recurrent nasal mass was observed among two patients with inverted papilloma and one with inflammatory nasal mass. Malignant disease is usually associated with poor prognosis, especially when advanced. We recorded three mortalities during the period under the study. Two of them were managed for advanced squamous cell carcinoma. The other was a case of NK cell lymphoma. We followed up all patients with inflammatory polyp and benign lesions for an average of 6 months and those with malignant disease for 5 years.

### Limitation

Inability to get complete records of all patients managed for unilateral sinonasal masses due to missing or failure to report information by the attending surgeon. The sample size is relatively too small to make population-based conclusions.

### CONCLUSION

Inflammatory nasal polyp is the most common type of unilateral nasal mass, followed by inverted papilloma in this study. Rhinorrhea, nasal blockage, and observance of nasal growth were common to all patients. However, epistaxis and facial pain were observed in patients with neoplastic lesions. Patients with malignant lesion presented relatively earlier than those with inflammatory and benign lesions. The outcome of patients with inflammatory and

benign lesions is good when compared to those with malignant lesion in this study. Awareness campaign and thorough history, examination, and investigation of any patients with prolonged nasal symptoms will go a long way in detecting malignant as well as other sinonasal lesions early.

### Financial support and sponsorship

Nil.

### Conflicts of interest

There are no conflicts of interest.

### REFERENCES

1. Karthikeya P, Mahima VG, Bhavna G. Sinonasal verrucous carcinoma with oral invasion. *Indian J Dent Res* 2006;1:82-6.
2. Kristensen S, Vorre P, Elbrond O, Sogaard H. Nasal schneiderian papillomas. *Clin Otolaryngol* 1985;10:12534.
3. Uysal İÖ, Misir M, Polat K, Altuntaş EE, Atalar MH, Tuncer E, *et al.* Primary malignant melanoma of the nasal cavity. *J Craniofac Surg* 2012;23:e2-5.
4. Hulse KE, Stevens WW, Tan BK, Schleimer RP. Pathogenesis of nasal polyposis. *Clin Exp Allergy* 2015;45:328-46.
5. Kim WA. Tumours of the nose and sinuses. In: Hussain SM, editor. Logan turner's Diseases of the Nose, Throat and Ear Head and Neck Surgery. 11<sup>th</sup> ed. New York: CRC Press; 2016. p. 119-29.
6. Paz Silva M, Pinto JM, Corey JP, Mhoon EE, Baroody FM, Naclerio RM. Diagnostic algorithm for unilateral sinus disease: A 15-year retrospective review. *Int Forum Allergy Rhinol* 2015;5:590-6.
7. Sutar HB. Clinicopathological study of nasal polypoidal masses. *Ann Int Med Den Res* 2015;1:315-9.
8. Kerawala C, Clarke P, Newbold K. Nasal cavity and paranasal sinus malignancy. In: Watkinson JC, Clarke RW, editors. Scott-Brown's Otorhinolaryngology Head and Neck Surgery. 8<sup>th</sup> ed. New York: CRC Press; 2009. p. 73-91.
9. Rudralingam M, Jones K, Woolford TJ. The unilateral opaque maxillary sinus on computed tomography. *Br J Oral Maxillofac Surg* 2002;40:504-7.
10. Nair S, James E, Awasthi S, Nambiar S, Goyal S. A review of the clinicopathological and radiological features of unilateral nasal mass. *Indian J Otolaryngol Head Neck Surg* 2013;65:199-204.
11. Goldenberg D, Golz A, Fradis M, Márta D, Netzer A, Joachims HZ. Malignant tumors of the nose and paranasal sinuses: A retrospective review of 291 cases. *Ear Nose Throat J* 2001;80:272-7.
12. Humayun AH, Huq AH, Ahmed SM, Kamal MD, Kyaw KU, Nilakanta B. Clinicopathological study of sinonasal masses. *Bangladesh J Otorhinolaryngol* 2010;16:15-22.
13. Tritt S, McMains KC, Kountakis SE. Unilateral nasal polyposis: Clinical presentation and pathology. *Am J Otolaryngol* 2008;29:230-2.
14. Kahveci OK, Duran A, Miman MC. Our histopathological result for intranasal masses: Retrospective study of 6 years. *J Clin Anal Med* 2012;3:289-92.
15. Gomes P, Gomes A, Salvador P, Lombo C, Caselhos S, Fonseca R. Clinical assessment, diagnosis and management of patients with unilateral sinonasal disease. *Acta Otorrinolaringol Esp* 2020;71:16-25.
16. Iseh KR. Lateral rhinotomy-a review of 38 operations from Sokoto Nigeria. *Niger J Surg Res* 2006;8:57-61.
17. Kucur C, Oghan F, Özbay I, Erdogan O, Tok S, Sanal B, *et al.* Unilateral nasal pathologies: Clinical presentation and management. *ENT Updates* 2015;5:23-9.
18. Bohman A, Oscarsson M, Holmberg K, Johansson L, Millqvist E, Nasic S, *et al.* Heredity of nasal polyps. *Rhinology* 2015;53:25-8.
19. Rogers DJ, Bevans SE, Harsha WJ. Endoscopic resection of juvenile nasopharyngeal angiofibroma. *Adv Otorhinolaryngol* 2012;73:132-6.

20. Leoncini G, Zanetti L. The papillomas of the sinonasal tract. A comprehensive review. *Pathologica* 2017;109:31-4.
21. Dulguerov P, Jacobsen MS, Allal AS, Lehmann W, Calcaterra T. Nasal and paranasal sinus carcinoma: Are we making progress? A series of 220 patients and a systematic review. *Cancer* 2001;92:3012-29.
22. Rice DH, Stanley RB. Surgical therapy of tumors of the nasal cavity, ethmoid sinus, and maxillary sinus. In: Panje W, editor. *Comprehensive Management of Head and Neck Tumors*. 2<sup>nd</sup> ed. Philadelphia: Saunders; 1999. p. 558-81.
23. Ologe FE, Adeniji KA, Segun-Busari S. Clinicopathological study of head and neck cancers in Ilorin, Nigeria. *Trop Doct* 2005;35:2-4.
24. Belli S, Yildirim M, Eroglu S, Emre FK. Single-sided sinonasal mass: A retrospective study. *North Clin Istanbul* 2018;5:139-43.