

Hypokalemia-induced myopathy and massive creatine kinase elevation as first manifestation of Conn's syndrome

Sir,

Primary hyperaldosteronism is characterized by hypersecretion of aldosterone from the adrenal cortex. If the aldosterone-producing pathology is adenoma then the disease is called Conn's syndrome. Hypertension, hypokalemia and metabolic alkalosis are developed in excessive secretion of aldosterone.¹ In this article, it is aimed to present a case diagnosed as myopathy caused by hypokalemia and elevated creatin kinase developed secondary to the primary hyperaldosteronism in a 43-year-old female patient, who has admitted with symptoms of muscle weakness, exhaustion, fatigue, dry mouth, frequent urination and drinking a lot of water.

A 43-year-old female patient has admitted to our endocrinology clinic with the complaints of muscle weakness, exhaustion, fatigue, dry mouth, frequent urination and drinking a lot of water, which were present for approximately 1 year and increased recently. The patient's blood pressure was 150/90 mm Hg, pulse was 80 per min., and fever was 37.2°C. System examination was normal except for 3/5 muscle weakness in both the upper and lower extremities. Laboratory tests revealed hypokalemia and elevation of massive CK [Table 1]. The patient had history of hypertension and was using Olmesartan 20 mg 1 × 1; and since her potassium was 1.7 mmol/L, the causes of secondary hypertension were investigated. 1 mg of dexamethasone suppression test has revealed that cortisol level was 1.3 mg/dl. Plasma aldosterone and Plasma Aldosterone/Plasma Renin activity was increased. Vanil mandelic acid, metanephrine and normetanephrine were normal in 24-hour urinary. Saline infusion test was performed and plasma aldosterone was found as 980 ng/dl [Table 1]. Adrenal Computed Tomography revealed an adenoma-related nodular lesion of 32 × 20 mm in diameter in the right adrenal [Figures 1 and 2]. The patient was diagnosed with Conn's syndrome, presented with hypokalemic myopathy and elevation of massive CK. After medical treatment, muscle weakness and laboratory parameters were completely normal in line with the normalized potassium levels. The patient's initial symptoms were thought to be connected to hypokalemia developed secondarily to Conn's syndrome. The patient was referred

Table 1: Laboratory values of patient

Parameters	Arrival values	After treatment
K (N: 3,5-5,1 mmol/L)	1,7	5
ALT (N: 0-41 U/L)	72	13
AST (N: 0-40 U/L)	166	13
LDH (N: 135-224 U/L)	860	365
CK (Creatine kinase) (N: 0-200 U/L)	4267	91
Glukoz (N: 82-115 mg/dl)	124	93
Kreatinin (N: 0.7-1.2 mg/dl)	0,6	0,6
Na (N: 136-145 mmol/L)	138	137
Ca (N: 8.8-10.2 mg/dl)	8,2	9,2
1 mg DST* (N:<1.8 mg/dl)	1,3	-
Plasma aldosterone/plasma renin activity (N:<20 ng/dl/ng/ml)	204,17	-
Plasma aldosterone value (N:<70-300 ng/dl)	980	-
Plasma renin activity (N: 0.7-3.3 ng/dl)	0,48	-

*DST – Dexamethasone suppression test; ALT – Alanine aminotransferase; AST – Aspartate aminotransferase; LDH – Lactate dehydrogenase; CK – Creatine kinase; NA – Sodium; CA – Calcium

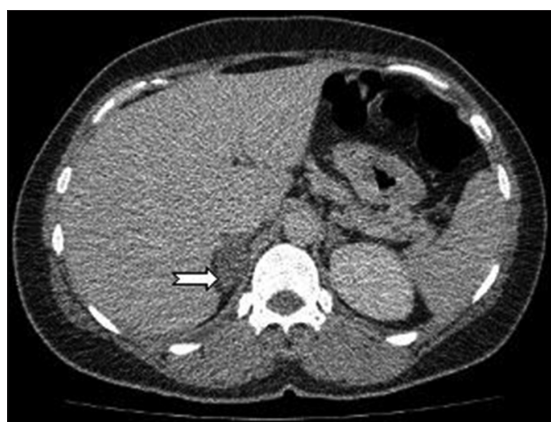

Figure 1: In axial contracted CT section in the right adrenal gland hypodense nodular lesion (white arrow) can be seen size in diameter 32 × 20 mm

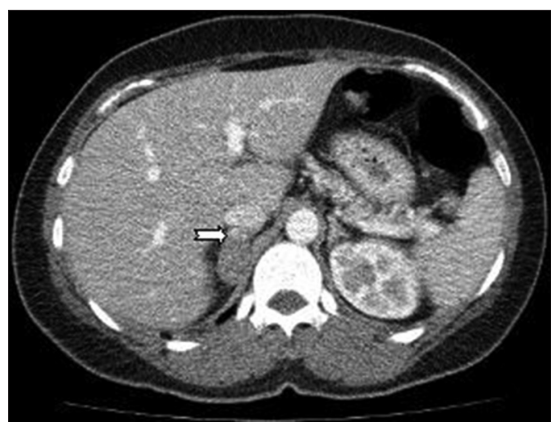

Figure 2: In axial cross-section dynamic contrast-enhanced CT, anterior part of the right adrenal gland showing the minimal contrast enhancement (white arrow) 20 HU density well-defined in diameter 32 × 20 mm nodular lesions observed

for adrenal surgery with the diagnosis of Conn's syndrome, and histopathology result was reported adenomas.

Severe muscle weakness may be present due to hypokalemia seen in Conn's syndrome.^{2,3} It is also reported that elevation of CK may be present in Conn's syndrome.^{4,5} In our patient, there was an ongoing and increasing muscle weakness. The measured value of potassium was 1.7 mmol/L, and CK was 4267 U/L. There was a dramatic improvement in the patient's clinical and laboratory values after potassium supplementation. Our patient was diagnosed as Conn's syndrome as a result of the tests performed considering the secondary hypertension due to the symptoms of hypokalemia, hypertension, and high levels of massive CK, and the patient underwent surgery. And in the result of the operation, adenoma was reported in accordance with the radiological imaging.

As a result, it should be kept in mind that hypokalemia-related myopathy and elevated massive CK may be the first presentation of Conn's syndrome in a patient followed up due to hypertension.

Serdar Olt, Selcuk Yaylaci, Lacin Tatli¹,
Yasemin Gunduz¹, Tayfun Garip, Ali Tamer

Department of Internal Medicine and ¹Radiology, Sakarya University
Faculty of Medicine, Sakarya, Turkey


Address for correspondence:

Dr. Selcuk Yaylaci,
Department of Internal Medicine, Sakarya University Faculty of
Medicine, 54100 Sakarya, Turkey.
E-mail: yaylakis@hotmail.com

REFERENCES

- Mattsson C, Young WF Jr. Primary aldosteronism: Diagnostic and treatment strategies. *Nat Clin Pract Nephrol* 2006;2:198-208.
- Huang YY, Hsu BR, Tsai JS. Paralytic myopathy: A leading clinical presentation for primary aldosteronism in Taiwan. *J Clin Endocrinol Metab* 1996;81:4038-41.
- Kotsaftis P, Savopoulos C, Agapakis D, Ntaios G, Tzioufa V, Papadopoulos V, *et al.* Hypokalemia induced myopathy as first manifestation of primary hyperaldosteronism-an elderly patient with unilateral adrenal hyperplasia: A case report. *Cases J* 2009;2:6813.
- Crawhall JC, Tolis G, Roy D. Elevation of serum creatine kinase in severe hypokalemic hyperaldosteronism. *Clin Biochem* 1976;9:237-40.
- Steinfurt J, Müller MC, Seidel A, Salm R, Ochs A. Pareses, myalgias, and massive CK elevation: A severe neurological disorder?. *Med Klin (Munich)* 2010;105:496-500.

Access this article online

Quick Response Code:	Website: www.nigeriamedj.com
	DOI: 10.4103/0300-1652.119658