

Familial dextrocardia in a Nigerian family

Sir,

Dextrocardia is a rare congenital defect characterised by reversal of the position of the heart to the right side of the thoracic cavity. Its true incidence worldwide is not completely known but it is estimated to occur in about 1 in 12,019 pregnancies in the United State of America.¹ Its incidence among Nigerians is also unknown, however there have been case reports mostly amongst Nigerian adults.² Dextrocardia could be familial, however the exact cause is not completely understood; while both autosomal recessive and dominant modes of inheritance have been implicated some cases are sporadic events.^{3,4} Familial dextrocardia amongst Nigerians still remains a rarity and none has been documented amongst same

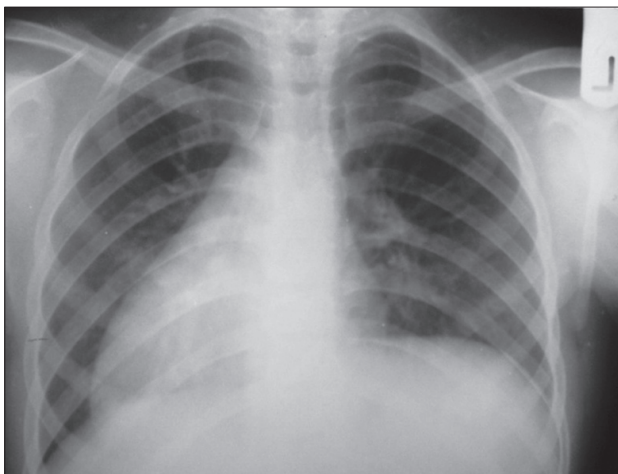


Figure 1: Chest X-ray of case 1 showing dextrocardia

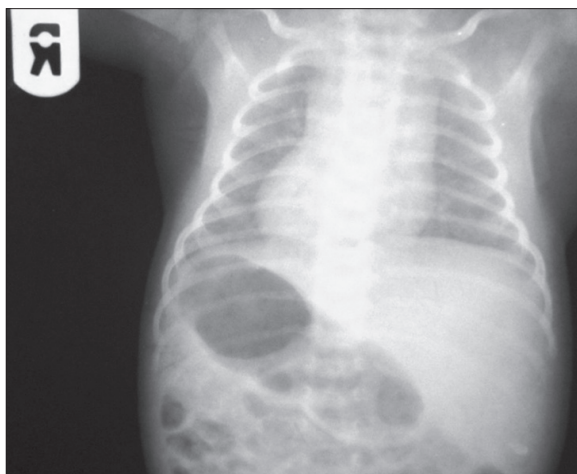


Figure 2: Chest X-ray of case 2 showing dextrocardia, the gastric bubble on the right side and the liver on the left side

generation of family members to the best of the author's knowledge; therefore its occurrence in a Nigerian family is reported.

The first case was a 5-year-old girl whose complaints were of recurrent cough, breathlessness and fever shortly after birth; she was also small for age but was not cyanosed; she was the second of the mother's three children in a polygamous family setting and was a product of consanguineous marriage (Parents are first cousins). She had chest-X-ray [Figure 1], electrocardiograph (ECG) and echocardiographic confirmation of the diagnosis of situs inversus totalis with partial atrioventricular septal defect. She had a younger sibling (the second case) who was a 3-year-old boy was also diagnosed with situs inversus totalis at the third week of life following routine check-up [Figures 2 and 3a-e]; he did not have intracardiac structural defect and had remained symptom free with normal developmental milestone. The second wife's only child was normal.

The exact inheritance pattern in familial dextrocardia is not completely understood; Campbell³ studied 21 sibs of 10 families with situs inversus and reported the importance of consanguinity while Cockayne⁴ reported several members of same family affected with situs

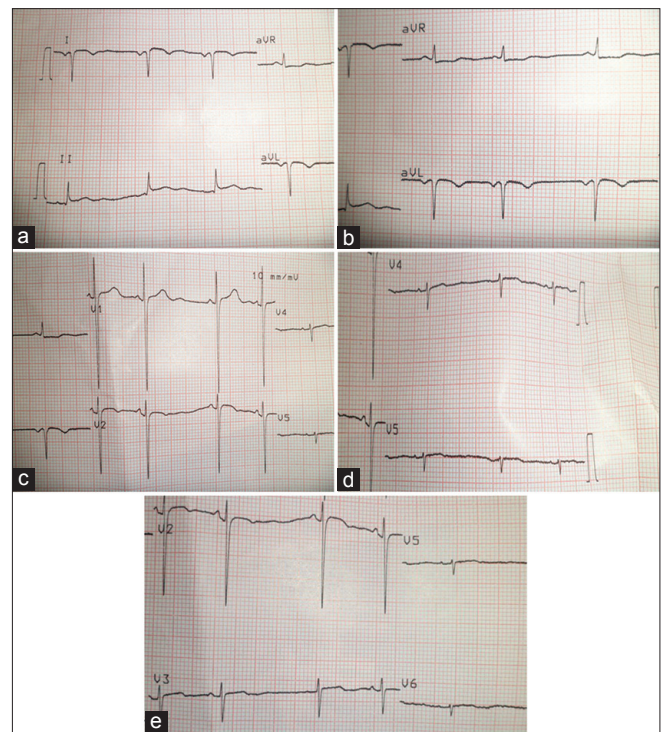


Figure 3: ECG stripe showing (a) Negative deflections of P, QRS and T waves in lead I and positive deflections in aVR. (b) Upright complexes in aVR and negative deflections in lead aVL. (c) High amplitude QRS complexes noted in V1, V2. (d) Lower amplitude complexes in V4, V5. (e) V2, V3 has higher amplitude of QRS complexes compared to V5, V6

inversus and further noted a high percentage of its occurrence in marriages involving first cousins; he then suggested an autosomal recessive mode of inheritance, however the documentation of dextrocardia in two successive generations as observed by Chib *et al.*,⁵ may suggest an autosomal dominant mode of inheritance in some cases; however, in our case, both parents were not affected and they were first cousins, while the second wife, who was not related to the husband, recently had a child who was also not affected, which may further buttress the significance of consanguinity and an autosomal recessive mode of inheritance. Though both cases had situs inversus totalis with mirror image dextrocardia, only the propositi had associated structural cardiac defects, why this occurred is not completely understood but may further highlight variability in its expression. Therefore, complete evaluation of family members of propositi is important since most cases of situs inversus totalis without any other severe malformation may remain asymptomatic and only detected as an incidental finding when they present for other unrelated illness. Finally, dextrocardia could run in families, but the exact cause is not completely understood; therefore, all family members of propositi should be evaluated in order not to miss the diagnosis.

Aliyu Ibrahim

Department of Paediatric, Paediatric Cardiology Unit,
Aminu Kano Teaching Hospital/Bayero University, Kano, Nigeria

Address for correspondence:

Dr. Aliyu Ibrahim,
Department of Paediatric, Paediatric Cardiology Unit, Aminu Kano
Teaching Hospital/Bayero University, Kano, Nigeria.
E-mail: ibrahimaliyu2006@yahoo.com

REFERENCES

1. Bohun CM, Potts JE, Casey BM, Sandor GG. A population-based study of cardiac malformations and outcomes associated with dextrocardia. *Am J Cardiol* 2007;15:305-9.
2. Ahmed H, Alhassan K, Amole AO. Kartagener's syndrome in a child: A six year follow up. *Nig J Paediatrics* 1997;24:24-30.
3. Campbell M. The mode of inheritance in isolated laevocardia and dextrocardia and situs inversus. *Br Heart J* 1963;25:803-13.
4. Cockayne EA. The genetics of transposition of the viscera. *Q J Med* 1938;7:479-93.
5. Chib P, Grover DN, Shahi BN. Unusual occurrence of dextrocardia with situs inversus in succeeding generations of a family. *J Med Genet* 1977;14:30-2.

Access this article online	
Quick Response Code:	Website: www.nigeriamedj.com
	DOI: 10.4103/0300-1652.119656