

Endoscopic management of emphysematous periurethral and corporal abscess

Priyadarshi Ranjan, Saurabh Sudhir Chipde, Sandeep Prabhakaran, Surabhi Chipde¹, Rakesh Kapoor

Departments of Urology and Kidney Transplantation, ¹Anaesthesiology, Sanjay Gandhi Post Graduate Institute of Medical Sciences, Lucknow, India

ABSTRACT

We came across an interesting case which was presented with fever, dysuria and perineal pain, not responding to antibiotics. The computed tomography scan showed periurethral abscess containing multiple air specs with involvement of bilateral corpora cavernosa. We successfully treated this patient with endoscopic drainage. Spontaneous periurethral and corporal abscess in male is a rare entity and emphysematous form in corpora has not been described before.

Key words: Emphysematous infections, corporal abscess, periurethral abscess

Address for correspondence:

Dr. Rakesh Kapoor,
Department of Urology and Kidney
Transplantation, Sanjay Gandhi
Post Graduate Institute of Medical
Sciences, Lucknow, India.
E-mail: rk Kapoor@saggi.ac.in

INTRODUCTION

There are few case reports of corporal abscess in males, which are usually caused after trauma, intervention or infection.^{1,2} These were managed with either incision and drainage or percutaneous aspiration. We are reporting an unusual case of spontaneous emphysematous periurethral abscess which involved the bilateral corpora cavernosa, and was managed endoscopically.

CASE REPORT

A 48-year-old gentleman, with history of diabetes mellitus, presented to the emergency department with high grade fever, lower urinary tract symptoms and perineal pain for 3 weeks. Local examination revealed a mildly tender swelling at the penoscrotal [Figure 1] and perineal region. Gentle perineal compression resulted in pus discharge from the urethra. Per-rectal examination revealed boggy over the prostate, but the trans-rectal ultrasound was inconclusive. An urgent computed tomography scan revealed a moderate sized periurethral collection around the bulbo-membranous urethra extending into both the corporal bodies, containing specs of air foci [Figure 2]. Urine culture grew mixed flora. The patient was taken up for cystourethroscopy, which revealed the bulging area near bulbo-membranous

junction with trickling of pus. The prostatic urethra and verumontanum were normal. Prostate was de-roofed, but was completely normal. The most bulging point in the bulbar urethra was de-roofed, which drained 75-80 ml of copious thick pus. A suprapubic catheter was placed. His fever

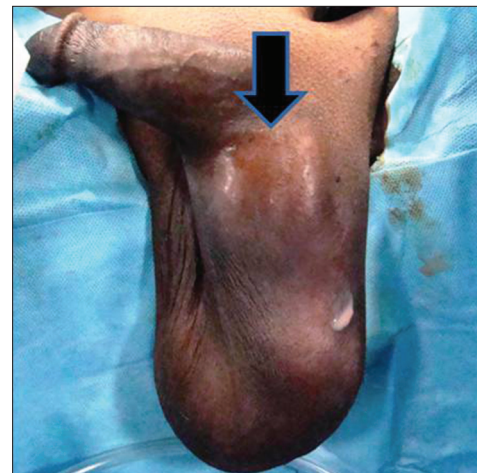

Figure 1: Clinical photograph showing swelling in scotoperineal region, which on compression discharged the pus per urethra

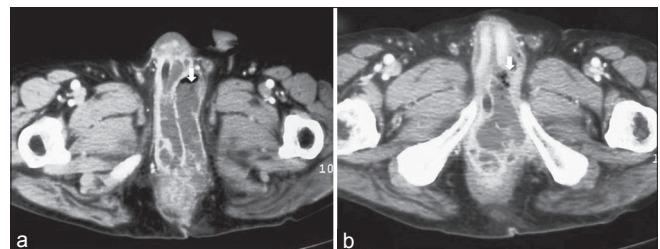


Figure 2: Computed Tomography scan showing abscess in the region of corporal bodies (a) and root of penis (b) with presence of air foci

Access this article online

Quick Response Code:



Website:

www.nigeriamedj.com

DOI:

10.4103/0300-1652.114579

and toxemia resolved after drainage and broad spectrum intravenous antibiotics. A retrograde urethrogram after 3 months revealed mild narrowing at bulbo-membranous region, which was managed endoscopically. He was put on self calibration and remained asymptomatic after 6 months and didn't have erectile dysfunction.

DISCUSSION

Corporeal infection and abscess formation has been described in association with trauma, penile prosthesis, cavernosography, intracorporeal papaverine injection and gonorrhoea.¹⁻³ Yachia and Fiedman reported a case of tuberculous cold abscess of corpus cavernosum.⁴ This condition had been treated with either percutaneous minimally invasive aspiration or conventional incision and drainage.^{1,5,6}

Minami *et al.*, have described two cases of corporal abscess, although not emphysematous; which were treated by incision and drainage.⁶ This resulted in erectile dysfunction. Others also found the similar outcome.⁷ In our case, we got the response with the endoscopic drainage and didn't encounter the problem of erectile dysfunction.^{6,7}

We performed a thorough search of literature, but didn't found any report of emphysematous abscess involving the corpora.

Take home message: The periurethral and corporal abscess doesn't always require open or percutaneous drainage, but can be managed endoscopically with good results.

REFERENCES

1. Moskovitz B, Vardi Y, Pery M, Bolker M, Levin DR. Abscess of corpus cavernosum. *Urol Int* 1992;48:439-40.
2. Niedrach WL, Lerner RM, Linke CA. Penile abscess involving the corpus cavernosum: A case report. *J Urol* 1989;141:374-5.
3. Rosen T. Unusual presentation of gonorrhoea. *J Am Acad Dermatol* 1982;6:369-72.
4. Yachia D, Friedman M, Auslaender L. Tuberculous cold abscess of the corpus cavernosum: A case report. *J Urol* 1990;144:351-2.
5. Thanos L, Tsagouli P, Eukarpidis T, Mpouhra K, Kelekis D. Computed tomography-guided drainage of a corpus cavernosum abscess: A minimally invasive successful treatment. *Cardiovasc Intervent Radiol* 2011;34:217-9.
6. Minami T, Kajikawa H, Kataoka K. Abscess of corpus cavernosum: Two case reports. *Hinyokika Kyo* 2006;52:387-9.
7. Sater AA, Vandendris M. Abscess of corpus cavernosum. *J Urol* 1989;141:949.

How to cite this article: Ranjan P, Chipde SS, Prabhakaran S, Chipde S, Kapoor R. Endoscopic management of emphysematous periurethral and corporal abscess. *Niger Med J* 2013;54:209-10.

Source of Support: Nil, **Conflict of Interest:** None declared.