

Brain sonography in African infants with complicated sporadic bacterial meningitis

Kenneth C. Eze, Sam U. Enukegwu¹, Angela I. Odike²

Departments of Radiology, Irrua Specialist Teaching Hospital (ISTH) Irrua and GreenHill Radiological Centre, Ebhoakhuala, Ekpoma, ¹St Bridget Radiological Centre, Benin City, ²Department of Paediatrics, Irrua Specialist Teaching Hospital (ISTH), Irrua, Edo State, Nigeria

ABSTRACT

Background: To determine the structural findings in brain sonography of African infants with complicated sporadic bacterial meningitis. **Materials and Methods:** Retrospective assessment of medical records of patients who underwent brain sonography on account of complicated bacterial meningitis. The brain sonography was carried out over a 4-year period (between September 15, 2004 and September 14, 2008). **Result:** A total of 86 infants were studied (40 boys and 46 girls in a ratio of 1:1.1); more than 70% of the patients were aged below 6 months. Presenting complaint included convulsion with fever in 34 (39.53%), persistent fever 20 (23.26%), bulging fontanelles 8 (9.30%), coma 7 (8.14%) and sepsis with convulsion 6 (6.98%), among others. Patients' place of previous treatment included specialist hospitals 33 (38.37%), private hospitals 21 (24.42%), herbal home centres 12 (13.95%), nursing homes 8 (9.30%), patent medicine stores 7 (8.14%) and other non-doctor attended clinics 5 (5.81%) infants. The sonographic findings included hydrocephalus 36 (41.86%), cerebral infarction 12 (13.95%), encephalocoele 9 (10.40%) and intracerebral abscess 7 (8.14%) infants. Cerebritis 5 (5.81%), intracerebral hemorrhage 3 (3.49%), porocephalic cysts 2 (2.33%), cerebral oedema 2 (2.33%), intraventricular haemorrhage 1 (1.16%) and subdural collection 1 (1.16%) infants; 8 patients (9.30%) had normal findings. **Conclusion:** Hydrocephalus, cerebral infarction and intracerebral abscess were the most common complications elicited by sonography in this study. Early and adequate treatment with antibiotics in patients with persistent fever and convulsion with fever will reduce the complications of meningitis and its long-term neurological sequelae.

Key words: Africa, brain, complication, infants, meningitis, sonography

Address for correspondence:

Kenneth C. Eze,
Department of Radiology,
Faculty Medicine,
Nnamdi Azikiwe University,
Nnewi Campus,
Anambra State, Nigeria.
E-mail: ezechallenge@yahoo.co.uk

INTRODUCTION

Bacterial meningitis in African children is a major public health problem, because of its common occurrence, high mortality and high rate of residual neurological sequelae associated with it. In southern Nigeria, pneumococcal meningitis has been identified as the highest cause of sporadic pyogenic meningitis, while, in northern Nigeria, meningococcal meningitis is predominant in a common epidemic form.¹⁻³

Several studies have identified that meningitis is more common in 0-2 years aged infants.¹⁻⁵ From the age of 0-6

months, the anterior and posterior fontanelles are patent and can be used as acoustic window to directly and clearly visualise the intracranial content and the brain for abnormalities.^{6,7} From the age of 6 months up to 2 years, the brain can be visualised through very thin temporal bones.⁸ When complications of bacterial meningitis set in, resulting in hydrocephalus or reduced developmental milestones, the closure of the fontanelles may be delayed and it is then possible to visualise through the fontanelles even up to the age of 2 years.^{9,10} Among the imaging modalities for assessment of the brain in bacterial meningitis, plain film is the most readily available. However, the yield of plain radiography is poor as it can only show intracranial calcification, fractures or craniofacial disproportion as a pointer to hydrocephalus.¹¹

Computed tomography (CT) scan and magnetic resonance (MR) imaging have excellent definition of structures defining normalities or abnormalities with great details.⁸⁻¹² Furthermore, MR imaging can also image the brain in different planes without additional repositioning of the

Access this article online	
Quick Response Code:	Website: www.nigeriamedj.com
	DOI: 10.4103/0300-1652.122340

patients and can assess the vessels without the need of intravenous contrast. However, major disadvantages of both CT and MR imaging are the associated high cost and the fact that they are not readily available. Also, CT and MRI require high maintenance cost and high level of expert technical engineers for steady operation of the technical part of the machine.^{6-8,11} For countries like Nigeria with lack of steady power supply, dedicated power generators are required to supply power to CT and MRI machines,¹¹ which greatly increase the running cost. The minimum monthly wage of workers in Nigeria during the period of the study was ₦7,500:00 only, while the cost of CT scan (brain) for children at the University of Benin Teaching Hospital (UBTH), located about 90 km from Irrua, was ₦15,000 – ₦20,000:00, depending on whether intravenous contrast medium is used. The cost of MR imaging for children at the University College Hospital (UCH) Ibadan, located about 200 km from Irrua, the nearest centre with MR imaging scanner was ₦40,000:00 only. Radiation hazards to infants is also due to the use of CT for brain imaging in bacterial meningitis.^{6-8,11}

Ultrasound scan is cheap, readily available, lacks any form of radiation hazard and can be performed without sedation.^{7,8} When high frequency (7.5–15 MHz) transducer is used, it is possible to display excellent normal structure and any abnormality. The cost of ultrasound scan in our centre at the time of this study was ₦700:00 (government hospital) and N1000.00 for Greenhill Radiological Centre, Ekhuokuala, Ekpoma, as compared to N15,000:00 for brain CT at UBTH, Benin City and about N40,000 for brain MR imaging at UCH, Ibadan. Therefore, when it is possible to assess the intracranial content using ultrasound, brain sonography is the most cost-effective, practical, radiation-free, readily available, and accessible method of imaging the brain of children in developing countries.⁶⁻⁸

Although ultrasound is operator dependent, when performed by competent operators, it can be very accurate and has excellent correlation with the results obtained by both CT and MR imaging.^{10,12,13} Also, some studies have shown that it is better to image the developing brain with ultrasound as compared with CT or MR imaging as the findings from ultrasound correlate more with patients' outcome than those from CT or MR imaging.⁸ Sonography can also be done repeatedly without any hazards to the baby, unlike the use of CT, in which radiation hazards is a major problem and the use of MR imaging in which cost is a major limiting factor.^{6,7}

MATERIALS AND METHODS

This is a retrospective assessment of the case notes, radiology requests and reports of patients who were referred for brain sonography for complicated bacterial meningitis in our centre. Complication was determined by

previous treatment for bacterial meningitis in other centres or in our centre several weeks or months before referral for brain sonography on account of development of extra neurological complaint.

The data were collected from the radiology and medical record department of the hospitals. The study patient included both patients in the outpatient department and those referred from other hospitals and clinics in the environs.

Brain sonography was done using 7.5 MHz sector transducer fitted of a Siemens S₁ 250 Scanner (Siemens AG, Germany 1992). Occasionally, when the lesions were very gross, Toshiba Justvision 400 (Toshiba Inc, USA, 2003) fitted with 3.5 MHz convex transducer was used to image the brain, especially in severe hydrocephalus and in subdural haematoma or intraventricular haemorrhage with hydrocephalus. The brain sonography was carried out over a 4-year period at Irrua Specialist Teaching Hospital, Irrua and Green Hill Radiological Centre, Ekpoma, Edo state, Nigeria, between September 15, 2004 and September 14, 2008. The collected data were analysed using Microsoft Excel (Microsoft Inc USA, 2006).

RESULTS

A total of 86 children aged 0-12 months were examined with brain ultrasound scan on account of complicated bacterial meningitis in the study period comprising 40 boys and 46 girls (male to female ratio of 1:1.1).

Only 33 patients were in the hospital, while 53 came from other clinics or treatment centres [Table 1]. The age range of the patients is shown in Table 2 with an age group of 0-7 months, comprising 78 (90.69%) of the patients [Table 2].

Among the observed presenting complaints, persistent fever with convulsion in 34 (39.53%) and persistent fever in 20 (23.26%) infants were the most common complaints while on treatment for meningitis, which necessitated the request for brain sonography. Other presenting complaints are bulging fontanelle in 8 (9.30%), coma in 7 (8.14%) and swelling of the head in 5 (5.81%) among others [Table 3].

The sonographic findings are shown in Table 4. Hydrocephalus was the most common findings in 36 patients (41.86%); 8 (9.30%) patients showed normal findings, while 12 (13.95%) showed cerebral infarction. Other findings are shown in Table 4 and in Figures 1 and 2. Figure 1 shows early stage of hydrocephalus, Figure 2 shows late stage and Figure 3 shows normal brain sonography in a neonate.

The data were analysed using Microsoft Excel (Microsoft Inc, USA, 2007).

Table 1: Place of previous treatment

Place of Previous Care	Number	%
General hospital	33	38.37
Private hospital	21	24.42
Non-doctor attended clinic	5	5.81
Nursing home	8	9.30
Herbal home	12	13.95
Patent medicine store	7	8.14
Total	86	100

Table 2: Age range

Age range (Months)	M	F	Total	%
0-1	6	11	17	19.77
2-3	10	12	22	25.58
4-5	11	13	24	27.91
6-7	9	6	15	17.44
8-9	2	2	4	4.65
10-12	2	2	4	4.65
Total	40	46	86	100

Table 3: Presenting complaint

Presenting Complaint	Total	%
Persistent fever	20	23.26
Sepsis with convulsion	6	6.98
Coma	7	8.14
Convulsion with fever	34	39.53
Inability to move/paraplegia	2	2.33
Swelling of the head	5	5.81
Bulging fontanelles	8	9.30
Inability to hold the head erect	1	1.16
Inability to sit	1	1.16
Cellulitis of the skull	1	1.16
Persistent cough with convulsion	1	1.16
Total	86	100

Table 4: Sonographic findings

Sonographic Findings	Number	%
Hydrocephalus/ventriculomegaly	36	41.86
Encephalocoele cerebral atrophy/widening of sulci	9	10.47
Intracerebral abscess	7	8.14
Subdural hematoma	1	1.16
Intracerebral haemorrhage	3	3.49
Cerebral infarction	12	13.95
Echogenic sulci/cerebritis	5	5.81
Normal	8	9.30
Porocephalic cyst	2	2.33
Intracerebral haemorrhage with cerebral oedema	2	2.33
Intraventricular haemorrhage/debris/ventriculitis	1	1.16
Total	86	100

DISCUSSION

In this study, 73.26% of the patients were aged 0-5 months. This occurred because the patients were

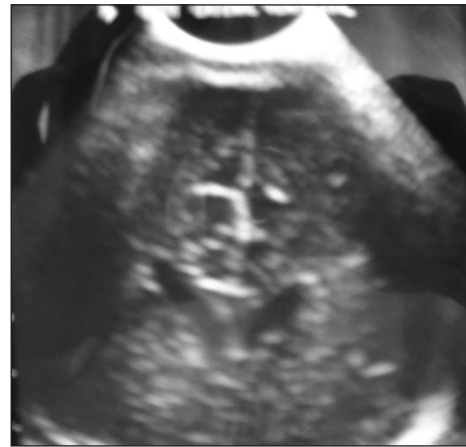


Figure 1: Brain sonography showing early stage of dilated ventricle

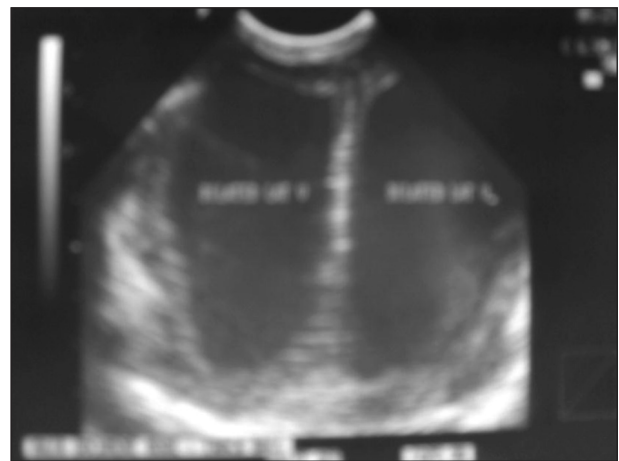


Figure 2: Brain sonography showing grossly dilated lateral ventricles

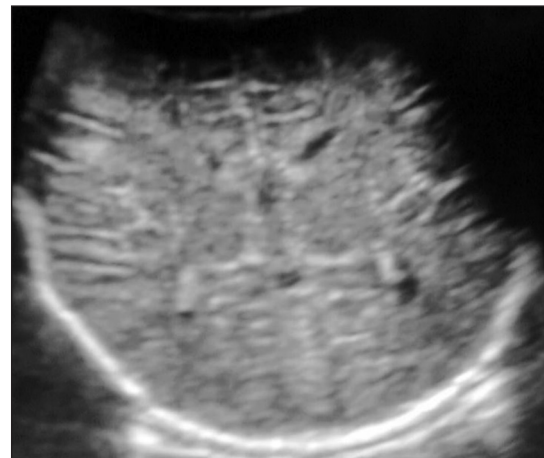


Figure 3: Brain sonography showing normal brain in a neonate

referred for ultrasound as the referring clinicians were convinced that it will be an appropriate mode of investigation as most of the patients have had previous care.¹⁻⁵

Several reasons have been proposed by different authors on why patients with meningitis in developing countries have high mortality and residual radiological sequelae. Low rate of referral and inadequate treatment in peripheral health centres before referral to the teaching hospital, where most studies were done, was recognised as the most important reasons.^{10,12-14} Delayed presentation, previous care in orthodox facilities, limited recognition of the possibility of meningitis, partial treatment, lack of typical signs and inadequate referral practices were also identified by many authors.^{10,12-15} However, what was missing was the lack of conclusive diagnosis of structural damage done to the brain, which may require treatment. Among the diagnostic modalities, sonography is the best, hazard-free and readily available modality for infants aged 0-12 months for diagnosis of the intracranial structures. In this study, the health facilities where most patients were treated before referral were, general hospitals for 33 (38.37%), private hospitals for 21 (24.42%) and herbal homes for 12 (13.95%) patients [Table 1]. General hospitals in many rural areas in Nigeria including Edo State were staffed with one or two general duty doctors with only few years of experience after graduation from medical school and no postgraduate training in paediatrics. These doctors may not recognise the non-classical signs, symptoms and complications of meningitis, especially at earlier stages for early treatment and referrals, and some of the hospitals were not supported with adequate laboratory facilities for accurate diagnosis.^{14,15}

Brain sonography was employed by several authors as an aid for the diagnosis of bacterial meningitis in infants.⁶⁻¹² However, the mainstay of the use of brain sonography in meningitis is the monitoring of intracranial complication of the disease.^{12,16} Among the recorded complications, hydrocephalus is the most common complications seen in 36 patients (41.86%) in this study [Figures 1 and 2]. This comprised 28 (32.56%) communicating hydrocephalus and 8 (9.30%) non-communicating hydrocephalus. Different degrees of cerebral infarction, often with widening of the adjacent lateral ventricle were noted in 12 (13.95%) patients. These findings agree with the findings of other authors on the subject.^{9,10,12-15} Soni *et al.*, noted ventriculomegaly in 59% and Fotsin *et al.*, recorded 71.43% communicating hydrocephalus among those with complications.^{9,15}

Twelve patients (13.95%) had cerebral infarction, noted as hypoechoic areas with irregular margins. The infarction could have resulted from ischaemia or areas of haemorrhage with liquefaction. Normal findings were recorded in 8 patients (9.30%) [Table 4, Figure 3]. Therefore, only less than 10% of the patients had normal findings, showing that majority of the patients had complications noted in the study, which is consistent with study by previous authors.¹⁷⁻¹⁹ However, authors who studied other brain lesions in infants in addition to

complicated meningitis recorded higher percentage of normal findings.^{7,8,20}

The use of brain sonography in children with meningitis could help diagnose the complications at early stages. Formal training for doctors on brain sonography is necessary and important for its accurate use.^{21,22}

In conclusion, childhood meningitis is particularly a major cause of death, illness and long-term neurological impairment in Africans. All efforts should be made, to ensure its early diagnosis to reduce its complications. The employment of sonography in general hospital in rural areas using appropriately trained general duty doctors could be rewarding in the long term towards reduction of complications of meningitis in children.

REFERENCES

- Ozumba UC. Changing pattern of acute bacterial meningitis in Enugu, Nigeria. *East Afr Med J* 1994;71:300-31.
- Johnson AW, Adedoyin OT, Abdul-Karim AA, Olanrewaju AW. Childhood pyogenic meningitis: Clinical and investigative indicators of etiology and outcome. *J Natl Med Assoc* 2007; 99:937-47.
- Ogunlesi TA, Okeniyi JA, Oyelami OA. Pyogenic meningitis in Ilesha, Nigeria. *Indian Paediatr* 2005;42:1019-23.
- Akpede GO. Presentation and outcome of sporadic acute bacterial meningitis in children in the African meningitis belt: Recent experience from northern Nigeria highlighting emergent factors in outcome. *West Afr J Med* 1995;14:217-26.
- Imananagha KK, Peters EJ, Philip-Ephram EE, Ekott JU, Imananagha LN, Ekure EN, *et al.* Acute bacterial meningitis in a developing country: Diagnosis related mortality among paediatric patients. *Cent Afr J Med* 1998;44:11-5.
- Nzeh DA, Erinle SA, Saidu SA, Pam SD. Transfontanelle ultrasonography: An invaluable tool in the assessment of the infant brain. *Trop Doct* 2004;34:226-7.
- Nzeh D, Oyinloye OI, Odebode OT, Akande H, Braimoh K. Ultrasound evaluation of brain infections and its complications in Nigerian infants. *Trop Doct* 2010;40:178-80.
- Eze KC, Enukegwu SU. Transfontanelle ultrasonography of infant brain: Analysis of findings in 114 patients in Benin City, Nigeria. *Niger J Clin Pract* 2010;13:179-82.
- N'Goan Am, N'Gbesso RD, Amon-Tanoh F, Oauttara DN, Keita K, Djedje AT. Fontanel ultrasonography of purulent meningitis in children in Abijan (Ivory Coast). *Sante* 1997;7:169-72.
- Soni JP, Gupta BD, Soni M, Gupta M, Dabi DR, Nema KR. Cranial ultrasonic assessment of infants with acute bacterial meningitis. *Indian Pediatr* 1994;31:1337-43.
- Eze KC, Salami TA, Eze CU, Alikah SO. Computed tomography study of complicated bacterial meningitis. *Niger J Clin Pract* 2008;11:351-4.
- Han BK, Babcock DS, McAdams L. Bacterial meningitis in infants: Sonographic findings. *Radiology* 1985;154:645-50.
- Ferberbaum R, Vaz FA, Krebs VL, Diniz EM, Ramos SR, Manissadjan A. Bacterial meningitis in the neonatal period. Clinical evaluation and complications in 109 cases. *Arq Neuropsiquiatr* 1993;51:72-9.
- Akpede GO, Omoigberale AI, Dawodu SO, Olomu SC, Shatima DR, Apeleakha M. Referral and previous care of children with meningitis in Nigeria: Implication for the presentation and outcome of meningitis in developing countries. *J. Neurol Sci* 2005;228:41-8.

15. Gonsu Fotsin J, Kago I, Dzogang MT, Kamga HG, Koki P, Dombou A, *et al.* Purulent Meningitis in children in Yaoundé (Cameron). Survey of complications using echoencephalography. *Ann Pediatr (Paris)* 1991;38:110-4.
16. Edwards MK, Brown DL, Chua GT. Complicated infantile meningitis: Evaluation of real-time sonography. *AJNR Am J Neuroradiol* 1982;3:431-4.
17. Chapp-Jumbo EN. Neurological infection in a Nigerian University Teaching Hospital. *Afr Health Sci* 2006;6:55-8.
18. Ofovwe GE, Ibadin MO, Okunola PO, Ofoegbu B. Pattern of emergency neurologic morbidities in children. *J Natl Med Assoc* 2005;97:488-92.
19. Nwosu CM, Njeze GF, Opara C, Nwajuaku C, Chukwura CK. Central nervous system infection in rainforest zone of Nigeria. *East Afr Med J* 2001;78:97-101.
20. Tabari AM, Isyaku K, Mamman M, Ma'aji S, Idris SK. Experience on transfontanelle neurosonography in Kano, Nigeria: A preliminary report. *Niger Postgrad Med J* 2008;15:255-8.
21. Davis PJ, Cox RM, Brooks J. Training in neonatal cranial ultrasound: A questionnaire survey. *Br J Radiol* 2005;78:55-6.
22. Reynolds PR, Dale RC, Cowan FM. Neonatal cranial ultrasound interpretation: A clinical audit. *Arch Dis Child Fetal Neonatal Ed* 2001;84:F92-5.

How to cite this article: Eze KC, Enukegwu SU, Odike AI. Brain sonography in African infants with complicated sporadic bacterial meningitis. *Niger Med J* 2013;54:320-4.

Source of Support: Nil, **Conflict of Interest:** None declared.

New features on the journal's website

Optimized content for mobile and hand-held devices

HTML pages have been optimized for mobile and other hand-held devices (such as iPad, Kindle, iPod) for faster browsing speed.

Click on [**Mobile Full text**] from Table of Contents page.

This is simple HTML version for faster download on mobiles (if viewed on desktop, it will be automatically redirected to full HTML version)

E-Pub for hand-held devices

EPUB is an open e-book standard recommended by The International Digital Publishing Forum which is designed for reflowable content i.e. the text display can be optimized for a particular display device.


Click on [**EPub**] from Table of Contents page.

There are various e-Pub readers such as for Windows: Digital Editions, OS X: Calibre/Bookworm, iPhone/iPod Touch/iPad: Stanza, and Linux: Calibre/Bookworm.

E-Book for desktop

One can also see the entire issue as printed here in a 'flip book' version on desktops.

Links are available from Current Issue as well as Archives pages.

Click on  View as eBook