

# Outcome of bronchoscopic biopsies in the University of Benin Teaching Hospital

S. U. Okugbo, Ezekiel E. Ugiagbe<sup>1</sup>

Department of Surgery, Cardiothoracic Division, University of Benin Teaching Hospital, Benin City, Edo State, <sup>1</sup>Department of Pathology (Morbid Anatomy), University of Benin Teaching Hospital, Benin City, Edo state, Nigeria

## ABSTRACT

**Aim:** Our study was done to evaluate our bronchoscopic techniques, sizes and diagnostic yield. **Materials and Methods:** This was a retrospective study comprising all cases of bronchial biopsies done in the University of Benin Teaching Hospital from 2007 to 2011. All patients who had flexible bronchoscopy under general anaesthesia during the period under review where enrolled in the study. **Results:** There were a total of 16 patients: Nine males and seven females, with a mean age of 46.9 years. The main indications were cough (87.5%), weight loss (62.5%), X-ray findings of a chest lesion (87.5%), chest pain (62.5%), difficulty with breathing (31.3%) and massive haemoptysis (25%). Histology results showed inadequate samples in six and Bronchogenic carcinoma in four patients. The histology was pivotal in eight patients. **Conclusion:** Bronchoscopic biopsies are fraught with problems and other clinical investigative tools would certainly be important in improving the results.

**Key words:** Biopsy, flexible bronchoscopy, outcome

### Address for correspondence:

Dr. Ezekiel E. Ugiagbe,  
Department of Morbid Anatomy,  
University of Benin Teaching  
Hospital, PMB 1111, Benin City,  
Edo State, Nigeria.  
E-mail: ugiasghama@yahoo.com

## INTRODUCTION

Bronchoscopy is an important tool for diagnosis in lesions presenting in the lungs. It aids the visualisation of lesions and directs biopsy from lesions that are thus visualised.<sup>1</sup> Biopsy specimens can be obtained using biopsy forceps, or brushings or transbronchial needle.<sup>1</sup> For accurate biopsy, the lesions should be visualised through the bronchial tree; hence, centrifugal lesions may not be accessed.<sup>2,3</sup> This is the limitation of the procedure.

Bronchoscopy is an invasive procedure either done with the aid of a flexible or rigid bronchoscope. The biopsy specimens size obtained differ between instruments, with the rigid producing bigger tissues than the flexible.<sup>1</sup> Biopsy specimens obtained are generally between 1 and 2 mm in size.<sup>4</sup> The flexible scope find better patient acceptance, since it is routinely done in the awake patient and as an outpatient procedure. It also has a better reach extending to the 6<sup>th</sup> level of bronchial branching. However, apart from the smaller size of the specimen obtained,

the tissues may be further crushed as they are retrieved through the port in the instrument.<sup>3,4</sup> This may distort tissue integrity and affect histological diagnosis. These drawbacks have spurred the development of other means of increasing tissue size and yield notably the cryobiopsy technique.<sup>4</sup>

Our study was done to evaluate our flexible bronchoscopic techniques, sizes and diagnostic yield.

## MATERIALS AND METHODS

This is a retrospective study comprising all cases of bronchial biopsies done in the University of Benin Teaching Hospital from 2007 to 2011. During the period, all patients who had diagnostic flexible bronchoscopy under general anaesthesia under review were enrolled in the study. The data were obtained from the theatre, outpatient clinic records and collated and their clinical histories gleaned from the case notes for epidemiological and biodata. The data were analysed using Statistical Package for the Social Sciences (SPSS) 16 and the result presented in tables and graphs. Cases whose histological reports were missing were removed from the study. All the bronchial biopsies were obtained by the aid of flexible bronchoscope.

The flexible bronchoscopy was done under general anaesthesia by the Cardiothoracic Surgeons. The scope used was the Olympus model. Biopsy was obtained

### Access this article online

#### Quick Response Code:



#### Website:

www.nigeriamedj.com

#### DOI:

10.4103/0300-1652.114567

using the Olympus biopsy forceps and the specimens were immediately fixed in formalin solutions. They were subsequently embedded in paraffin wax and cut sections routinely stained with haematoxylin and eosin. Additional stains were done as required. The number of specimens showing unequivocal evidence of carcinoma was determined. The cell type was identified as squamous-cell, adenocarcinoma, oat-cell, or large-cell undifferentiated. This classification is based on that proposed by the World Health Organisation.

The flexible bronchoscope was introduced through an appropriate sized endotracheal tube via a connector such that continuous patient ventilation by the Anaesthetist was still feasible [Figure 1].

The biopsy forceps was used to take 4-5 biopsy specimens. These were all at the sites of visualised lesions or points of apparent bronchial distortions. There were challenges with tissue samples by the Histopathologist with multiple consultations, inadequacy of samples were adjudged from crushed tissues, poor staining and unrepresentative tissues.

## RESULTS

There were a total of 16 patients: Seven females and nine males. The mean age was 46.9 years.

The mean number of biopsies taken was four.

The mean tissue biopsy size was 2.0 mm with a range of 1-5 mm.

Table 1 shows the distribution of the histological diagnosis with a majority being inadequate for diagnosis and 25% showing carcinoma.

Table 2 shows the frequency distribution of the histological diagnosis of the lung cancers with squamous cell carcinoma being the predominant histological type.

Table 3 shows the indications for the bronchoscopy and biopsy, with suspicious lesions on chest radiograph and unremitting cough being the commonest indications.

Table 4 shows the accuracy of the biopsy specimen compared with the overall final diagnosis in these patients. The majority of the patients were bronchogenic carcinoma with pulmonary tuberculosis a close second.

## DISCUSSION

The indication for biopsy was a combination of clinical symptoms and signs together with lesions seen on chest X-ray. This coincides with the approved guidelines by the British Thoracic Society (BTS) as bronchoscopy is an important tool for resolving the diagnostic problem.<sup>5</sup> Lung

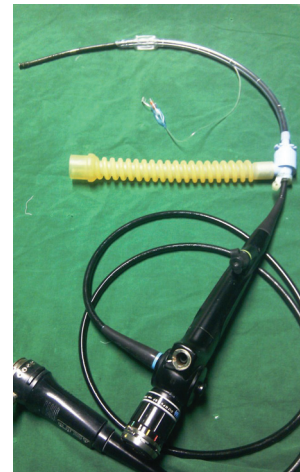


Figure 1: A bronchoscope and adaptor

Table 1: Histological diagnosis

Diagnosis	Frequency	Percent
Inadequate sample	6	37.50
Lung carcinoma	4	25.00
Chronic Inflammatory lesion	3	18.75
Chronic venous congestion	1	6.25
Inflammatory lesion	1	6.25
Normal	1	6.25
Total	16	100

Table 2: Histology of the lung tumour

Type	Frequency
Squamous cell carcinoma	3
Adenocarcinoma	1

Table 3: Indication for bronchoscopy

Indication	Frequency	Percentage
Lesion on X-ray	14	87.5
Unremitting cough	14	87.5
Weight loss	10	62.5
Chest pain	7	43.8
Difficulty with breathing	5	31.3
Massive haemoptysis	4	25.0

Table 4: The biopsy accuracy

Final diagnosis	Frequency	Percentage	Biopsy accuracy (%)
Bronchogenic carcinoma	10	62.50	4 (40)
Pulmonary tuberculosis	5	31.25	3 (60)
Good pasture disease	1	6.25	0 (0)
Total	16	100	7 (44)

tumour was an important differential in all the patients in the study. Biopsy, in these instances, provides tissue specimens for histological diagnosis.<sup>5,6</sup> Lesions found on chest radiographs formed the main reason for referral for bronchoscopy. This is important as patients tend to present

with non specific symptoms. Bronchoscopy, therefore, helps to resolve the diagnosis.<sup>1-3</sup>

Biopsy sizes showed a similarity with tissue sizes obtained from other studies.<sup>4,7,8</sup> Tissue histology results were adequate for histological diagnosis only in eight patients. In only one case was the tissue returned as normal. Other investigations including percutaneous biopsy and open lung biopsy with sputum cytology were employed in all patients to increase diagnostic accuracy.<sup>8-10</sup>

The indications in this study highlight the importance of the biopsy specimen for obtaining diagnosis and directing the course of treatment. The finding of 50% usefulness in this study was low compared to work done in other centres.<sup>7</sup> This may be due to the tissue handling of small specimens and possibly presence of unrepresentative tissues in the specimen collected. Possibly the small sizes were pivotal in the result. Other workers have demonstrated the improved usefulness of cryobiopsies.<sup>4,10</sup>

Multiple biopsies is the rule, at least five being adjudged the best for obtaining adequate tissue with probability of appropriate tissue diagnosis.<sup>2</sup>

The site of biopsy is important in obtaining representative tissue for histopathology. Biopsy obtained from sites of extrinsic bronchial impression have a smaller yield of about 25% as against >75% for directly visualised bronchial lesions.<sup>3,5,7</sup> All three patients with adenocarcinoma had unrepresentative biopsy specimens, which diagnosis was only confirmed either at thoracotomy or transthoracic lung and pleural biopsy.

Rigid bronchoscopy was not used in any of the patients as the combination of flexible bronchoscopy and transthoracic lung and pleural biopsy in combination with cytology sufficed in establishing the diagnosis in all patients. However, its use may have improved the sensitivity of bronchoscopic biopsies since it does not have the drawback of smaller tissue sample sizes, crushing of specimen seen

in flexible bronchoscopes, however, it has limitation in the reach within the bronchial tree.<sup>1,3</sup>

## CONCLUSION

Bronchoscopic biopsies are fraught with problems and other clinical investigative tools would certainly be important in improving the results.

## REFERENCES

1. Gellert AR, Rudd RM, Sinha G, Geddes DM. Fiberoptic bronchoscopy: Effect of multiple bronchial biopsies on diagnostic yield in bronchial carcinoma. *Thorax* 1982;37:684-7.
2. Payne CR, Stovin PG, Barker V, McVittie S, Stark JE. Diagnostic accuracy of cytology and biopsy in primary bronchial carcinoma. *Thorax* 1979;34:294-9.
3. Rudd RM, Gellert AR, Boldy DA, Studdy PR, Pearson MC, Geddes DM, *et al.* Bronchoscopic and percutaneous aspiration biopsy in the diagnosis of bronchial carcinoma cell type. *Thorax* 1982;37:462-5.
4. Aktas Z, Gunay E, Hoca NT, Yilmaz A, Demirag F, Gunay S, *et al.* Endobronchial cryobiopsy or forceps biopsy for lung cancer diagnosis. *Ann Thorac Med* 2010;5:242-6.
5. Payne CR, Hadfield JW, Stovin PG, Barker V, Heard BE, Stark JE. Diagnostic accuracy of cytology and biopsy in primary bronchial carcinoma. *J Clin Pathol* 1981;34:773-8.
6. Mountain CF. Clinical biology of small cell carcinoma: Relationship to surgical therapy. *Semin Oncol* 1978;5:272-9.
7. Webb J, Clarke SW. A comparison of biopsy results using rigid and fiberoptic bronchoscopes. *Br J Dis Chest* 1980;74:81-3.
8. Flower CD, Verney GI. Percutaneous needle biopsy of thoracic lesions: An evaluation of 300 biopsies. *Clin Radiol* 1979;30:215-8.
9. Tao LC, Pearson FG, Delarue NC, Langer B, Sanders DE. Percutaneous fine-needle aspiration biopsy. I. Its value to clinical practice. *Cancer* 1980;45:1480-5.
10. Griff S, Ammenwerth W, Schönfeld N, Bauer TT, Mairinger T, Blum TG, *et al.* Morphometrical analysis of transbronchial cryobiopsies. *Diagn Pathol* 2011;6:53.

**How to cite this article:** Okugbo SU, Ugiagbe EE. Outcome of bronchoscopic biopsies in the University of Benin Teaching Hospital. *Niger Med J* 2013;54:157-9.

**Source of Support:** Nil, **Conflict of Interest:** None declared.