

A case report of complete mole with co-existent exaggerated placental site reaction and review of the literature

Ozhan Ozdemir, Mustafa Erkan Sari, Vefa Selimova, Bunyamin Ugur Ilgin, Cemal Resat Atalay

Department of Obstetrics and Gynecology, Ankara Numune Education and Research Hospital, Ankara, Turkey

ABSTRACT

Exaggerated placental site (EPS) is defined as a non-neoplastic trophoblastic lesion, which intermediate trophoblasts infiltrate exaggeratedly into endometrium and myometrium. These lesions may occur following normal pregnancy, ectopic pregnancy, abortus or molar pregnancy. Herein we share a case of EPS detected after evacuation due to molar pregnancy. We also review the related literature, where only a few reports exist describing the clinical course, histopathology and differential diagnosis of EPS.

Key words: Exaggerated placental site, gestational trophoblastic disease, placental site trophoblastic tumour

Address for correspondence:

Dr. Ozhan Ozdemir,
Department of Obstetrics and
Gynecology, Ankara Numune
Training and Education Hospital,
Ankara-06010, Turkey.
E-mail: seyozi@hotmail.com

INTRODUCTION

Exaggerated placental site (EPS) is defined as a non-neoplastic trophoblastic lesion where middle trophoblasts infiltrate exaggeratedly into endometrium and myometrium. It consists of cells showing the same immunophenotypical features as the intermediate trophoblasts in the normal placental implantation site, and is observed as an exaggerated form of the normal physiological process.¹ These lesions may occur following normal pregnancy, ectopic pregnancy, abortus or molar pregnancy. They are seen in 1.6% of the first trimester abortuses.^{2,3} Despite the fact that EPS is non-neoplastic, it may infiltrate prominently into myometrium to generate cordons, and it should be histologically distinguished from the neoplastic lesions, particularly the placental site trophoblastic tumours (PSTT). It is important to make the differential diagnosis as the PSTT cells of the neoplastic proliferation of intermediate trophoblasts and the EPS cells have similar cytological and immunophenotypical features.⁴

CASE REPORT

A 26-year-old patient, gravida 3 para 1, applied with delayed menstruation of 6 weeks, and nausea to our

clinic. The uterus was found to be 10-week size in pelvic examination, and a 10 × 8 cm heterogeneous mass with solid and cystic fields was seen in uterine cavity by abdominopelvic ultrasonography. No foetal image was noticed. Mole evacuation was planned with a pre-diagnosis of complete hydatidiform mole. Pre-treatment blood beta human chorionic gonadotropin (β -hCG) level was measured to be 279.000 mIU/mL, and no additional signs were found in systemic examination or scanning. The pathology revealed EPS in addition to complete hydatidiform mole [Figure 1]. Trophoblastic cells were positive with pancytokeratin (panCK) and high molecular weight cytokeratin (34BE12), but negative with p63 in sites of EPS, whereas the Ki 67 proliferation index was stated to be 2-3%. The patient was followed up with weekly β -hCG measurements after the evacuation. The β -hCG declined to a level of 6700 mIU/mL in the first 4 weeks, but in the following three measurements it increased again. Thereupon, single agent methotrexate was given weekly, and remission was achieved after 3 weeks of treatment.

DISCUSSION

EPS is defined as a non-neoplastic trophoblastic lesion where middle trophoblasts infiltrate exaggeratedly into endometrium and myometrium. It consists of cells showing the same immunophenotypical features as the middle trophoblasts in the normal placental implantation site, and is observed as an exaggerated form of the normal physiological process where the number of these cells are increased.¹ This lesion was formerly defined as syncytial endometritis, but this is neither an inflammatory process

Access this article online

Quick Response Code:



Website:

www.nigeriamedj.com

DOI:

10.4103/0300-1652.129670

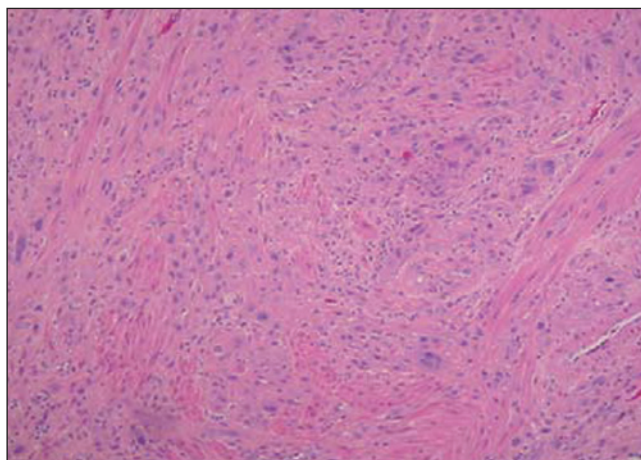


Figure 1: Infiltration of middle trophoblasts into myometrial smooth muscle layer (haematoxylin and eosin, 10 ×)

nor it is limited within the endometrium. Therefore the term 'Exaggerated Placental Site' has been recommended by the World Health Organisation.⁵

EPS may occur following normal pregnancy, ectopic pregnancy, abortus, or molar pregnancy. There are few reports describing the clinical course of EPS. Cases were reported in English literature following spontaneous abortus, elective abortus, C-section delivery and along with placenta previa, but this is the first case together with complete hydatidiform mole.^{1,6-8}

The distinction between normal and EPS is subjective because there is no exact information about the proportion and coverage of intermediate trophoblast infiltration in the implantation site in different periods of normal pregnancy.⁵ While most of the cells constituting this lesion are the mononuclear intermediate trophoblasts, there are also multinuclear intermediate trophoblasts infiltrating in various rates. Despite the infiltration of intermediate trophoblastic cells, the structure of implantation site is not impaired in most cases. Endometrial glands may totally be covered with trophoblasts but they are not damaged. Similarly, trophoblasts may infiltrate the myometrium without causing any necrosis. However, necrosis and degeneration may typically be seen in desidual vicinity in cases of spontaneous abortus. Other signs of pregnancy such as hyalinised spiral arteries, hypersecretory glands and chorionic villi are usually present.⁵

It is important to make the differential diagnosis as the PSTT cells of the neoplastic proliferation of intermediate trophoblasts and the EPS cells have similar cytological and immunophenotypical features. Beside these morphological similarities, as the trophoblasts in early pregnancy have primitive appearances and invade the spiral arteries intensively, classic histological criteria distinguishing a malignant process from a benign one fail to be valid. In our case EPS was seen in areas together with complete

hydatidiform mole, and remission in β -hCG levels was not provided following the evacuation of mole. Therefore, there seemed to be a persistent gestational trophoblastic disease in this patient, and it was important to distinguish this case from PSTT.

While a concurrent pregnancy and no mass in the myometrium is helpful for the diagnosis of EPS, it is in favour of PSTT if it occurs months after a term pregnancy or abortus, with presence of a mass in the myometrium.³ Whereas absence of chorionic villi, presence of mitoses and trophoblastic cells constituting joined masses microscopically support the diagnosis of PSTT, presence of chorionic villi and absence of mitosis in contrast favour the reaction of EPS.^{9,10} Cases in which distinction is hard to make, Ki-67 proliferation index is considerably useful. Natural killer cells and activated T lymphocytes are Ki-67 positive. While Ki-67 proliferation index being less than 5% is in favour of EPS, levels more than 5% support PSTT. Ki-67 proliferation index being close to zero despite the excessive trophoblastic infiltration, brings to mind that the number of increasing middle trophoblasts in implantation site is not dependent of *de novo* proliferation.⁵

EPS and PSTT have similar profiles immunohistochemically. Intermediate trophoblasts in implantation site are stained positively with cytokeratin and human placental lactogen (hPL), CD 146 (Mel-CAM), human leucocyte antigen-G (HLA-G) and e-cadherine, whereas they are negative with epithelial membrane antigen and Ber-EP4.^{5,9,11,12} Intermediate trophoblasts in the implantation site and the PSTT cells do not express p63. The distinction between the trophoblastic diseases can be done using p63, HLA-G, cytokeratin, hPL and Ki-67.¹³ Our case was diagnosed with EPS with p63 being negative, cytokeratin being positive and Ki-67 proliferation index being less than 5%.

RESULTS

EPS is a benign trophoblastic lesion and do not require a special treatment or follow-up. It is difficult to distinguish it from PSTT morphologically and immunohistochemically, and Ki-67 proliferation index is recommended for this distinction.

REFERENCES

1. Hasegawa T, Matsui K, Yamakawa Y, Ota S, Tateno M, Saito S. Exaggerated placental site reaction following an elective abortion. *J Obstet Gynaecol Res* 2008;34:609-12.
2. Yeasmin S, Nakayama K, Katagiri A, Ishikawa M, Iida K, Nakayama N, *et al.* Exaggerated placental site mimicking placental site trophoblastic tumor: Case report and literature review. *Eur J Gynaecol Oncol* 2010;31:586-9.
3. Dotto J, Hui P. Lack of genetic association between exaggerated placental site reaction and placental site trophoblastic tumor. *Int J Gynecol Pathol* 2008;27:562-7.
4. Shih IM, Kurman RJ. Ki-67 labeling index in the differential diagnosis of exaggerated placental site, placental site

- trophoblastic tumor, and choriocarcinoma: A double immunohistochemical staining technique using Ki-67 and Mel-CAM antibodies. *Hum Pathol* 1998;29:27-33.
5. Shih IM, Kurman RJ. The pathology of intermediate trophoblastic tumors and tumor-like lesions. *Int J Gynecol Pathol* 2001;20:31-47.
 6. Aydın A, Şahin N, Çıralık H, Mızrak H, Sönmez S. Exaggerated placental site reaction (two case report). *Genel Tıp Derg* 1997;7:36-8.
 7. Akbayir O, Alkis I, Corbacioglu A, Ekiz A, Akca A, Cekic S. Exaggerated placental site reaction detected during caesarean delivery: A case report. *Clin Exp Obstet Gynecol* 2012;39:234-5.
 8. Chen YF, Ismail H, Chou MM, Lee FY, Lee JH, Ho ES. Exaggerated placenta site in placenta previa: An imaging differential diagnosis of placenta accreta, placental site trophoblastic tumor and molar pregnancy. *Taiwan J Obstet Gynecol* 2012;51:440-2.
 9. Shen DH, Liao XY, Liu YL, Wang H, Yu YZ. Clinicopathological study of intermediate trophoblastic non-tumor lesions: Exaggerated placental site and placental site nodule. *Zhonghua Bing Li Xue Za Zhi* 2004;33:441-4.
 10. Chen X, Shi Y, Xie X. The clinical and pathological characteristics of exaggerated placental site. *Zhonghua Fu Chan Ke Za Zhi* 1998;33:352-4.
 11. Shih IM. The role of CD146 (Mel-CAM) in biology and pathology. *J Pathol* 1999;189:4-11.
 12. Singer G, Kurman RJ, McMaster MT, Shih IM. HLA-G immunoreactivity is specific for intermediate trophoblast in gestational trophoblastic disease and can serve as a useful marker in differential diagnosis. *Am J Surg Pathol* 2002;26:914-20.
 13. Shih IM, Kurman RJ. p63 expression is useful in the distinction of epithelioid trophoblastic and placental site trophoblastic tumors by profiling trophoblastic subpopulations. *Am J Surg Pathol* 2004;28:1177-83.

How to cite this article: Ozdemir O, Sari ME, Selimova V, Ilgin BU, Atalay CR. A case report of complete mole with co-existent exaggerated placental site reaction and review of the literature. *Niger Med J* 2014;55:180-2.

Source of Support: Nil, **Conflict of Interest:** All authors have contributed academically and scientifically in this letter, and share the scientific and ethical responsibility of it.