

# Operative stabilization of open long bone fractures: A tropical tertiary hospital experience

Adeleke O. Ifesanya, Temitope O. Alonge

Department of Orthopaedics and Trauma, University College Hospital, Ibadan, Nigeria

## ABSTRACT

**Background:** Operative treatment of open fractures in our environment is fraught with problems of availability of theater space, appropriate hardware, and instrumentation such that high complication rates may be expected. **Materials and Methods:** We evaluated all open long bone fractures operatively stabilized at our center to determine the outcome of the various treatment modalities as well as the determinant factors. **Result:** A total of 160 patients with 171 fractures treated between December 1995 and December 2008 were studied. There were twice as many males; mean age was 35.0 years. About half were open tibia fractures. Gustilo IIIa and IIIb fractures each accounted for 56 cases (45.2%). Fifty-three percent were stabilized within the first week of injury. Interval between injury and operative fixation averaged 11.1 days. Anderson-Hutchin's technique was employed in 27 cases (21.8%), external fixation in 21 (16.9%), plate osteosynthesis in 50 (40.3%), and intramedullary nail 15 cases (12.1%). Mean time to union was 24.7 weeks. Fifty-two complications occurred in 50 fractures (40.3%) with joint stiffness and chronic osteomyelitis each accounting for a quarter of the complications. Union was delayed in grade IIIb open fractures and those fractures treated with external fixation. **Conclusion:** A significant proportion of open long bone fractures we operatively treated were severe. Severe open fractures (type IIIb) with concomitant stabilization using external fixation delayed fracture union. While we recommend intramedullary devices for open fractures, in our setting where locking nails are not readily available, external fixation remains the safest choice of skeletal stabilization particularly when contamination is high.

**Key words:** Injuries, Nigeria, open fracture, road crashes, treatment

### Address for correspondence:

Dr. Adeleke O. Ifesanya,  
Department of Orthopaedics  
and Trauma, University College  
Hospital, Ibadan, Nigeria.  
E-mail: lekeifesanya@yahoo.com

## INTRODUCTION

Open fractures of the long bones are common in developing countries and are mostly due to the ever-increasing number of vehicular road traffic crashes, communal clashes, and civilian gunshot injuries. In these countries, functional emergency medical services are often nonexistent and patients with open fractures usually present late to the hospitals, some of who would have had some intervention by traditional bonesetters.<sup>1,2</sup>

The ultimate aim of management of open fractures is to halt bacterial proliferation in the wound and in the circulation, remove dead and nonviable tissues by extensive wound debridement, ensure adequate coverage of exposed bone

and achieve stable skeletal fixation to allow for fracture healing.<sup>3</sup> The choice of antibiotics used for preventing infection in these injuries is often determined by local or institutional antibiotic policies.<sup>4</sup>

Methods of achieving soft tissue cover after wound debridement are fairly standardized and the choice of technique may be determined by practice location and the experience of the attending plastic surgeon. However, the modalities of skeletal stabilization are very variable as they are dictated by the experience of the trauma surgeon, the availability of implants and or explants as well as the peculiar fracture characteristics. The most common technique of skeletal stabilization in open fractures is the use of external fixators. These devices are neither cheap nor readily available especially in developing countries where health insurance is usually not available and patients have to purchase their implants or explants prior to surgery.<sup>5</sup>

The surgical procedures (wound debridement, soft tissue cover, and skeletal stabilization) are usually carried out as emergency procedures and on account of the limitations outlined above, the attending trauma surgeon may be

Access this article online	
Quick Response Code:	Website: <a href="http://www.nigeriamedj.com">www.nigeriamedj.com</a>
	DOI: 10.4103/0300-1652.99825

compelled to make use of the implants or explants available at the time of surgery.

The aim of this retrospective study is to evaluate the outcomes of the modes of skeletal stabilization of open fractures treated at a tropical teaching hospital.

## MATERIALS AND METHODS

Cases of open long bone (humerus, radius, ulna, femur, tibia, and fibula) fractures operatively stabilized in the authors' institution over a 13-year period between December 1995 and December 2008 were identified from the operating theater diary. Hospital notes of these patients were retrieved and retrospectively reviewed.

Along with the patients' biodata, the etiology of the fractures, the open fracture types (according to the system of Gustilo, Mendoza, and Williams),<sup>6</sup> modes of skeletal stabilization, and the outcome of the various treatment options were documented. Patients whose hospital notes were not found were excluded from the study.

At first presentation, all the patients had their wounds inspected, wound swabs taken, and the wound layout sketched in the patients' record files (these cases were managed before the unit procured a digital camera). The wounds were subsequently covered with betadine-soaked guaze dressing. Intravenous ceftriaxone and ciprofloxacin was administered for 5 days based on previous studies on sensitivity pattern of microbial isolates from open fractures.<sup>4</sup> Intravenous metronidazole was added to the antibiotic regimen when there was a history of farm

injury. Oral antibiotics (ciprofloxacin and cefuroxime) was commenced after 5 days and continued for 6 weeks. Tetanus prophylaxis and active tetanus immunization were also given. Parenteral narcotic (or narcotic analogue) analgesic was given to relieve pain and the fractures were splinted prior to surgery with the aid of plaster backslabs or skin traction. Surgery comprised wound debridement, soft tissue cover as required (with the assistance of the plastic surgeon when a flap rotation was required) and skeletal stabilization was carried out as appropriate depending on the level of contamination, available explants or implants and the experience of the surgeon.

## RESULTS

A total of 294 open long bone fractures were operatively stabilized during the period. Table 1 summarizes the mode of treatment of all the cases. Only 171 cases in 160 patients whose case files could be retrieved were studied in detail [Table 2]. There were 99 men (61.9%) and 61 women with a mean age of 34.4±13.3 years (range: 4-66 years) and a peak of 21-50 years (74.4%). Vehicular road traffic crashes were the leading cause of injury accounting for 74 cases or 46.3% [Figure 1]. As Table 2 shows, the tibia was the most common bone operatively stabilized (82 fractures or 48.0%).

Gustilo types IIIa and IIIb varieties accounted for 74 (43.3%) and 79 (46.2%) fractures respectively. The modalities for skeletal stabilization employed include the Anderson-Hutchin's ("pins and plaster") technique (30), uniplanar, unilateral external fixators (43), plate osteosynthesis (68), and intramedullary nailing (15). Other methods (screws,

**Table 1: Total number of open long bone fractures and the various methods of operative stabilization during the period under study**

Bone	Method of fixation					Total (%)
	Plating	X-fix	A-H	Nailing	Other	
Tibia	17	98	32	7	10	164 (55.8)
Radius/ulna	19	4	–	7	5	35 (11.9)
Femur	34	10	1	3	3	51 (17.3)
Humerus	12	8	–	4	3	27 (9.2)
Other	5	2	–	–	10	17 (5.8)
Total (%)	87 (29.6)	122 (41.5)	33 (11.3)	21 (7.1)	31 (10.5)	294 (100.0)

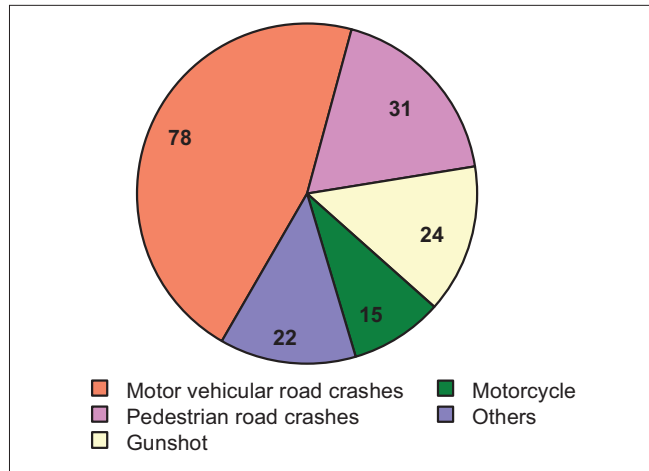
A-H=Anderson-Hutchin's technique, X-fix=External fixation, Other: k-wires, interfragmentary screws

**Table 2: Methods of operative stabilization of open long bone fracture cases whose hospital records were retrieved and full documentation carried out**

Bone	Method of fixation					Total (%)
	Plating	X-fix	A-H	Nailing	Other	
Tibia	12	35	29	4	2	82 (48.0)
Radius/ulna	16	2	–	6	3	27 (15.8)
Femur	28	2	1	3	2	36 (21.0)
Humerus	10	3	–	2	1	16 (9.4)
Other	2	1	–	–	7	10 (5.8)
Total (%)	68 (39.8)	43 (25.1)	30 (17.5)	15 (8.8)	15 (8.8)	171 (100.0)

A-H=Anderson-Hutchin's technique, X-fix=External fixation, Other: k-wires, interfragmentary screws

staples, k-wires, etc) were employed in 22 fractures. In effect, external fixation devices were utilized in 73 (42.7%) cases. Details are shown in Table 2. Plate osteosynthesis was the method of fracture stabilization in 7 Gustilo type I, 3 type II, 44 type IIIa, 13 type IIIb, and 1 type IIIc injuries. There was a



**Figure 1:** Causes of open fractures managed operatively

tendency to use external fixation devices for type IIIb injuries while plating was preferred in type IIIa injuries ( $P=0.001$ ).

The average time interval between injury and operative stabilization of the fractures was  $11.1 \pm 13.4$  days (range 1-75 days) with 50% of the fractures stabilized within the first week, 35% between the 2<sup>nd</sup> and 6<sup>th</sup> week and 15% after the 6<sup>th</sup> week of injury. Average timing of surgery were as follows: Plate osteosynthesis (73.5 days), external fixation (11.6 days), Anderson-Hutchin's technique (17.0 days), intramedullary nailing (19.5 days), others (15.2 days).

The patients were followed up for an average of  $11.4 \pm 13.4$  months (range 1-85 months). Bone union (bridging callus on anteroposterior and lateral radiographs as well as the absence of pain on palpation and weight bearing) was documented in 100 fractures and the healing time ranged from 3 to 78 weeks (mean:  $20.4 \pm 16.2$  weeks) [Table 3]. A third of the humeral fractures took longer than 6 months to heal while all but one of the forearm fractures healed within 6 months of the injury [Table 3]. Type IIIb open tibial fractures and the use of external fixator appeared to delay bone union ( $P=0.489$ ).

**Table 3: Relationship between the fracture healing time and patients' age, bone involved, severity of open fracture, and methods of fracture stabilization**

Variable	Healing time				Total	Statistics
	Within 3 months	3-6 months	6-12 months	>12 months		
Age range (in years)						
Up to 10	1	3	–	–	4	
11-20	3	3	2	1	9	
21-30	9	11	5	3	28	$X^2=15.696$ $P=0.985$
31-40	8	14	7	1	30	
41-50	7	6	4	–	17	
51-60	2	3	1	–	6	
61-70	1	3	1	1	6	
Total	31	43	20	6	100	
Bone fractured						
Tibia	11	26	13	2	52	$X^2=15.879$ $P=0.601$
Radius/ulna	12	3	–	1	16	
Femur	3	8	5	1	17	
Humerus	3	4	1	2	10	
Others	2	2	1	–	5	
Total	31	43	20	6	100	
Gustilo type						
I	5	2	–	–	7	$X^2=27.995$ $P=0.110$
II	2	3	–	–	5	
IIIa	17	15	9	4	45	
IIIb	6	23	11	2	42	
IIIc	1	–	–	–	1	
Total	31	43	20	6	100	
Method of stabilization						
Plate osteosynthesis	13	17	7	5	42	$X^2=34.576$ $P=0.489$
External fixation	3	14	8	1	26	
Anderson-Hutchin's tech.	5	9	4	–	18	
Intramedullary nail	5	2	–	–	7	
Other	5	1	1	–	7	
Total	31	43	20	6	100	

Table 4 shows the complications which occurred in 45.6% of the cases; secondary chronic osteomyelitis accounted for a quarter of the complications. Two patients required an amputation for gangrene following initial stabilization of the fractures (one was a Gustilo IIIc distal radial fracture, the other was a type IIIb tibial fracture). There was documented removal of infected implants in 10 patients after fracture union (average of 985.4 days after stabilization; range: 296-2,212 days). These were made up of eight plates and screws (3 femoral, 2 radial, 1 ulnar, ankle, and tibial) and 2 intramedullary nails (tibial and femoral). Two tibial external fixators were removed before fracture union due to severe pin track infection.

Complications were more likely in types IIIb and IIIc open fractures ( $P=0.006$ ). Neither the method of treatment nor the interval before fixation impacted on the occurrence of complications ( $P=0.675$ , and  $0.138$  respectively). In addition, the interval before skeletal fixation did not influence healing time ( $P=0.426$ ).

## DISCUSSION

The challenges of open fractures are multiple; prevention of infection (including tetanus), wound management and above all, fracture stabilization and union. The early use of antibiotics, aggressive and repeated debridement, fracture stabilization, and early bone coverage are factors that have greatly reduced the incidence of infection and nonunion in these fractures.<sup>7,8</sup>

The choice of antibiotics used to tackle infections is often made following the results of the wound swab or entirely on an established unit policy based on common local microbial isolates.<sup>4</sup> While antibiotic administration is often systemic, methods of continuous local antibiotic delivery to open fractures have been described.<sup>9</sup>

Wound management is often standardized but the debate on the best option for skeletal stabilization rages on.<sup>10</sup> This is more evident in developing countries where the choice of method depends not only on factors such as the experience of the attending surgeon but also on the availability of the required fixation hardware.

A significant proportion of open fractures operatively stabilized in this study belong to the severe (Gustilo type III)

variety. We found the Anderson-Hutchin's technique adequate in the management of most open tibia fractures provided the wound was not circumferential and no flap or skin graft cover was required after debridement. In patients with circumferential leg wounds and/or patients who had a flap or skin graft, we employed the Hoffman's external fixator or the AO uniplanar, unilateral external fixator.<sup>5</sup> Following the removal of external fixators after fracture union, the explants were sometimes resterilized (provided the patients from whom they were recovered tested negative for HIV and hepatitis B infections) and kept on the shelf for emergency use in our hospital. We are yet to receive feedback on adverse effects arising from reuse of explants which comes in handy especially for indigent patients. Although studies have advocated the use of intramedullary nails which afford access to the wounds apart from being easier to manage with better patient compliance,<sup>11</sup> it was sparingly used in this series. This is due to nonavailability of instrumentation for locked nails in our center hence the limited use of unreamed intramedullary nails. The triflanged nails were used for the tibia, Kuentscher nails for the femur and Rush pins for the humerus, radius, and ulna. Due to this limitation, fractures with significant comminution were stabilized by other methods. The micromotion that is allowed across the tibia fractures consequent on dynamization with the Anderson-Hutchin's technique might explain the shorter fracture healing time associated with the use of this technique in our series.<sup>5</sup> However, this technique has been virtually phased out in our institution due to its limited indication, difficulties of wound care and associated incidence of fracture redisplacement.

Apart from implant availability, the discrimination between the use of plate osteosynthesis and external fixation devices was also based on which bone was fractured (plating being preferred for fractures of the femur which would not be rigidly stabilized with the type of AO external fixator available in our center), as well as the degree of wound contamination (external fixation devices being reserved for the more contaminated injuries).

Tornetta *et al.* found no difference in healing time between external fixation and non-reamed locked nailing although there was slightly better range of knee motion and less malunion with the latter.<sup>10</sup> This was not our experience as intramedullary nailing was associated with shorter healing

**Table 4: The relationship between the severity of the open fracture and the incidence of complications in open fractures operatively stabilized**

Gustilo type	Wound infection	Nonunion	Delayed union	CSOM	Joint stiffness	Others	Total (%)
I	–	–	1	3	1	–	5 (6.4)
II	–	–	–	1	–	–	1 (1.3)
IIIa	2	1	2	8	7	6	25 (32.1)
IIIb	9	4	8	10	9	7	44 (56.4)
IIIc	–	–	–	–	1	2	3 (3.8)
Total (%)	11 (14.1)	5 (6.4)	11 (14.1)	22 (28.2)	18 (23.1)	15 (19.2)	78 (100.0)

$\chi^2$ : 91.198;  $P=0.006$ . Four of the 11 wound infections were external fixator pin track infections

time though this finding was not statistically significant. This may be attributed to the reservation of external fixation for the more severe fractures in our series.

Templeman *et al.* described a high complication rate in high energy open tibial fractures treated by plate osteosynthesis.<sup>3</sup> External fixation unlike plate osteosynthesis preserves the precarious blood supply to the bone and its poor soft tissue cover.<sup>12</sup> Neither of these methods seemed to improve healing time probably due to the former being reserved for severer injuries as earlier explained. The high incidence of contiguous joint stiffness can be attributed to immobilization of these joints when the Anderson-Hutchin's method is employed. Moreover, it suggests the need to improve upon and ensure early postoperative rehabilitation of our patients.

Civilian gunshot which was a fairly common cause of injury in this study is known to adversely affect soft tissue as well as bone union. It has been associated with incidence of nonunion and chronic suppurative osteomyelitis according to a report from Germany.<sup>13</sup>

Our infection rate of 12.9% did not preclude satisfactory functional results as argued by Weise *et al.* who obtained similar infection rates and average bone healing times in a review of 475 open long bone fractures. In spite of a considerable rate of postoperative infections (11.4-22.2%) and average bone healing between 26 and 30 weeks, satisfactory functional results were obtained.<sup>14</sup> Templeman *et al.* asserted that despite aggressive treatment of open fractures, some will remain contaminated and infection inevitable.<sup>3</sup> The incidence of chronic osteomyelitis in our study may be slightly higher over a longer follow-up period but we could not ascertain this as our patients usually default from follow-up when they have no complaints. Poor follow-up rates and outdated, manual methods of filing case notes in our institution accounted for the fewer number with documented fracture union.

Our study has shown that an interval between injury and skeletal stabilization of up to one and half weeks may not prolong the time to healing.

In resource poor settings as occurs in developing countries, management of open fractures remains a daunting task but reasonable outcome can be achieved with a careful selection of the skeletal stabilization method after adequate wound care. In units where there are no plastic surgeons and the wounds are adjudged to require the services of one, initial wound management and prompt referral to an appropriate facility has been shown to improve outcome.<sup>15</sup>

## CONCLUSION

The safe choice of skeletal stabilization of open long bone fractures in developing or resource-poor countries remains external fixation. This is especially so when the

injuries are of the high-energy variety with attendant heavy contamination compounded by late presentation, factors which have been found to also delay fracture union. While infective complications are comparable to previous reports, the high incidence of joint stiffness calls for attention to early postoperative rehabilitation.

## ACKNOWLEDGMENTS

The authors wish to acknowledge all the consultant medical staff of the Department of Orthopaedics and Trauma, University College Hospital, Ibadan whose patients were recruited into this study. We thank Dr. (Mrs.) Joy Ifesanya who assisted in the statistical analysis and critically reviewed the manuscript.

## REFERENCES

1. Onuminya JE. The role of the traditional bonesetter in primary fracture care in Nigeria. *S Afr Med J* 2004;94:652-8.
2. Ifesanya AO, Omololu AB, Ogunlade SO, Alonge TO. The burden of open fractures of the tibia in a developing economy. *Nig J Plast Surg* 2010;6:32-9.
3. Templeman DC, Gulli B, Tsukayama DT, Gustilo RB. Update on the management of open fractures of the tibial shaft. *Clin Orthop Relat Res* 1998;350:18-25.
4. Alonge TO, Salawu SA, Adebisi AT, Fashina AN. The choice of antibiotic in open fractures in a teaching hospital in a developing country. *Int J Clin Pract* 2002;56:353-6.
5. Alonge TO, Ogunlade SO, Salawu SA, Adebisi AT. Management of open tibia fracture- Anderson and Hutchins technique re-visited. *Afr J Med Med Sci* 2003;32:131-4.
6. Gustilo RB, Mendoza RM, Williams DN. Problems in the management of type III (severe) open fractures. A new classification of type III open fractures. *J Trauma* 1984;24:742-6.
7. Patzakis MJ, Wilkins J, Moore TM. Use of antibiotics in open tibial fractures. *Clin Orthop Relat Res* 1983;178:31-5.
8. Fischer MD, Gustilo RB, Varecka TF. The timing of flap coverage, bone-grafting, and intramedullary nailing in patients who have a fracture of the tibial shaft with extensive soft-tissue injury. *J Bone Joint Surg Am* 1991;73:1316-22.
9. Ostermann PA, Seligson D, Henry SL. Local antibiotic therapy for severe open fractures: A review of 1085 consecutive cases. *J Bone Joint Surg Br* 1995;77:93-7.
10. Tornetta P 3<sup>rd</sup>, Bergman M, Watnik N, Berkowitz G, Steuer J. Treatment of grade-IIIb open tibial fractures. A prospective randomised comparison of external fixation and non-reamed locked nailing. *J Bone Joint Surg Br* 1993;76:13-9.
11. Kayali C, Agus H, Eren A, Ozlük S. How should open tibia fractures be treated? A retrospective comparative study between intramedullary nailing and biologic plating. *Ulus Travma Acil Cerrahi Derg* 2009;15:243-8.
12. Schmidt A, Rorabeck CH. Fractures of the tibia treated by flexible external fixation. *Clin Orthop Relat Res* 1983;178:162-72.
13. Ramez S, Strecker W, Suger G, Karim H. Primary treatment of gunshot and explosion injuries of the extremities with the Ilisarov ring fixator. *Unfallchirurg* 1993;96:438-42.
14. Weise K, Grosse B, Hoffmann J, Sauer N. Results of treatment of 475 second- and third-degree open fractures of long tubular bones 1974-1988. *Aktuelle Traumatol* 1993;23 Suppl 1:2-20.
15. Hou Z, Xu Z, Su Z. Experiences and lessons about soft-tissue flaps covering of severe open tibial fracture. *Chin J Traumatol* 2001;4:245-7.

**How to cite this article:** Ifesanya AO, Alonge TO. Operative stabilization of open long bone fractures: A tropical tertiary hospital experience. *Niger Med J* 2012;53:16-20.

**Source of Support:** Nil, **Conflict of Interest:** None declared.