

# Histological study of smoke extract of *Tobacco nicotiana* on the heart, liver, lungs, kidney, and testes of male Sprague-Dawley rats

Adekomi Damilare Adedayo, A. A. Tijani<sup>1</sup>, A. A. Musa, T. D. Adeniyi<sup>1</sup>

Department of Anatomy, Faculty of Basic Medical Sciences, University of Ilorin, Ilorin, <sup>1</sup>College of Health Sciences, Osun State University, Osogbo, Nigeria

## ABSTRACT

**Background:** Some of the effects of tobacco on man's health are well documented in many scientific reports. Whenever tobacco is used either in smoked or chewed form, nicotine is absorbed by the lungs and oral cavity and is spontaneously moved into the bloodstream where it is circulated throughout the body system. **Materials and Methods:** Ten male Sprague-Dawley rats were used for this investigation. The animals were randomly assigned into two groups, A and B, of five animals each. The animals in group B (treatment group) were exposed to smoke from a completely burnt 0.74 g leaf extract of *Tobacco nicotiana*, wrapped in 0.5 g of sterilized cotton wool for 5 minutes three times daily (7 am, 10 am, and 1 pm). The animals in group A (control group) were exposed to smoke from completely burnt 1.24 g of sterilized cotton wool with the same parameters as observed with the treatment groups. The duration of exposure was 5 days. Three hours after the last exposure, all the animals were killed by cervical dislocation. The heart, liver, lungs, kidney, and testes were carefully excised, blotted dry, and fixed in formol saline for histological analysis using Hematoxylin and Eosin stain. **Results:** Using the light microscope, it was observed that the histoarchitectural profiles of the studied organs in the sections obtained from the control animals were well preserved. Histopathological observations of the heart, liver, lungs, kidney, and testes in the treated animals showed a varying pattern of histological alterations, and distortions such as mild edema and occasional destruction of myocardial fibers, degeneration of the hepatocytes, reduction in the population of the germ cells, enlargement of the alveoli, alveolar hemorrhage, shrinkage of the glomerulus and glomerular hemorrhage were observed in the sections of the organs of the study of the animals in the treatment group when compared with the control group, hence showing that the smoke extract of *Tobacco nicotiana* has adverse and compromising effects on the heart, liver, lungs, kidney, and testes of male Sprague-Dawley rats. **Conclusion:** From these observations, it can be inferred that the exposure of male Sprague-Dawley rats to the smoke extract of *Tobacco nicotiana* may be associated with structural damage of some vital organs.

**Key words:** Cotton wool, histological deviations, kidney, liver, testes, *Tobacco nicotiana*

### Address for correspondence:

Prof. Adekomi Damilare Adedayo,  
Department of Anatomy, Faculty of  
Basic Medical Sciences,  
P. M. B. 1515, University of Ilorin,  
Ilorin, Nigeria.  
E-mail: alexquye@gmail.com

## INTRODUCTION

Exposure to tobacco smoke has been recognized as a significant contributor to mortality.<sup>1,2</sup> Out of the thousands of chemical components of tobacco smoke, nicotine is not the only one that can interfere with functions of the body system. Nonspecific components of smoke, such as the

particles emitted during the combustion process, may also interfere with several processes of the body system.<sup>3</sup>

The burning of tobacco generates approximately 4000 compounds. The smoke can be separated into gas and particulate phases. The composition of the smoke delivered to the smoker depends on the composition of tobacco and how densely it is packed, the length of the column of tobacco, the characteristics of the filter and the paper, the temperature at which the tobacco is burned.<sup>4</sup>

Among the gaseous phase components are carbon monoxide, carbon dioxide, nitrogen oxides, ammonia, volatile nitrosamines, hydrogen cyanide, volatile sulfur containing compounds, volatile hydrocarbons, alcohols and aldehydes and ketones.<sup>4</sup> Some of these compounds

### Access this article online

#### Quick Response Code:



#### Website:

www.nigeriamedj.com

#### DOI:

10.4103/0300-1652.93791

inhibit ciliary movement in the lungs. Tar is the compound in tobacco that remains after the moisture and nicotine are subtracted and consists of polycyclic aromatic hydrocarbons, which are carcinogens. Nonvolatile nitrosamines and aromatic amines play an etiologic role in bladder cancer. The actual content of nicotine in tobacco can vary from 0.2 to 5%.<sup>4</sup>

Nicotine is the most abundant of the volatile alkaloids in the tobacco leaf. Nicotine is a colorless and volatile liquid alkaloid found in smoking and smokeless tobacco which turns brown and acquires the odor of tobacco upon exposure to air.<sup>4</sup> The alkaloid is water-soluble and forms water-soluble salts. More than 24 billion packages of cigarettes are purchased annually in the United States and approximately 400,000 deaths are attributed to cigarette smoking.<sup>4</sup>

Tobacco use leads most commonly to diseases affecting the heart and lungs, with smoking being a major risk factor for heart attacks, strokes, chronic obstructive pulmonary disease (COPD), emphysema, and cancer (particularly lung cancer, cancers of the larynx and mouth, and pancreatic cancer).<sup>5</sup> It also causes peripheral vascular disease and hypertension, all developed due to the exposure time and the level of dosage of tobacco. Furthermore, the earlier and the higher level of tar content in the tobacco-filled cigarettes causes the greater risk of these diseases. Cigarettes sold in developing nations tend to have higher tar content, and are less likely to be filtered, potentially increasing vulnerability to tobacco-related disease in these regions.<sup>5</sup>

The world health organization (WHO) estimates that tobacco caused 5.4 million deaths in 2004<sup>6</sup> and 100 million deaths over the course of the 20th century.<sup>7</sup> Similarly, the United States *Centers for Disease Control and Prevention* describes tobacco use as "the single most important preventable risk to human health in developed countries and an important cause of premature death worldwide."<sup>8</sup> Incidence of impotence is approximately 85% higher in male smokers compared to nonsmokers<sup>9</sup> and is a key factor causing erectile dysfunction (ED).<sup>9-11</sup> With all of these deleterious effects as reported by the WHO and the United States Centers for Disease Control and Prevention, the aim of this study was to investigate some of the toxic effects of the smoke extract of *Tobacco nicotiana* on tissue histology as a marker of toxicity on the organs of study.

## MATERIALS AND METHODS

The sample of *Tobacco nicotiana* used was obtained from the Botanical Garden of the University of Ilorin, Ilorin, Kwara State, Nigeria. Botanical identification was done at the Department of Plant Science University of Ilorin, Nigeria. The leaves of the plant were air-dried under standard laboratory conditions. The dried plant material was weighed using Gallenkamp (FA2104A, England)

electronic weighing balance and 0.74 g of the plant sample was later wrapped with 0.5 g of refined and sterilized cotton wool.

This experimental investigation was done in accordance with the standard humane animal care as outlined in the "Guide for the care and use of Animals in research and teaching," as approved by the Institute of Laboratory Animal Resource, National Research Council, DHHS, Pub. No NIH 86-23.<sup>12</sup>

The study was carried out using 10 presumably healthy male Sprague-Dawley rats weighing between 115 and 135. All the animals were housed in clean cages of dimensions 33.0×20.5×19.0 cm placed in well-ventilated standard housing conditions (12 hours light and 12 hours darkness, temperature: 28–31°C; humidity: 50–55%).<sup>13</sup> Their cages were cleaned every day.

The rats were fed with standard rat chow at a recommended dose of 100 g/kg as advised by the International Centre of Diarrhoea Disease Research, Bangladesh (ICDDR, B) daily. Drinking water was supplied *ad libitum*.

The 10 male Sprague-Dawley rats were randomly assigned into two experimental groups; A and B. Animals in group B (treatment group) were exposed to smoke from a completely burnt 0.74 g leaf of *Tobacco nicotiana* wrapped with 0.5 g of refined and sterilized cotton wool for 5 minutes three times daily (7 am, 10 am, and 1 pm) respectively. The animals in group A (control group) were exposed to smoke from a completely burnt 1.24 g of cotton wool for 5 minutes three times daily (7 am, 10 am, and 1 pm). The duration of investigation was 5 days (5 d).

Three hours after the termination of investigation, the animals were killed by cervical dislocation.<sup>14</sup> The heart, liver, kidney and testes were carefully excised from the animals, rinsed in cold sucrose solution, and blotted dry with filter paper. The liver, lungs, and heart were fixed in separate specimen bottles containing 10% formal-saline while the kidney and testes were quickly transferred into a specimen bottle containing Bouin's fluid. Thereafter, the fixed specimens were removed from the fixatives in order to process for further histological analysis.

Histological studies on the heart, liver, lungs, kidney, and testes were done according to the procedures described by Disbrey and Rack<sup>15</sup> and Drury and Wellington<sup>16</sup> The sections were subjected to Hematoxylin and Eosin staining procedures and the histological examination was done with the aid of the Olympus binocular light research microscope (XSZ-107BN, No. 071771). The histological outline of each photomicrographs was conducted through a stereological grid in order to access the population of the cells in each organ. The permanent photomicrographs of each slide were recorded with a Kodak Digital Camera (Kodak Easyshare C183) for subsequent histological analysis.

## RESULTS

No morphological alterations were observed in the morphology of the heart, liver, lungs, kidney, and testes of the animals in both groups killed (3 hours) after the termination of experimental procedure. The excised heart, liver, lungs, kidney, and testes of the animals in both groups appeared morphologically normal.

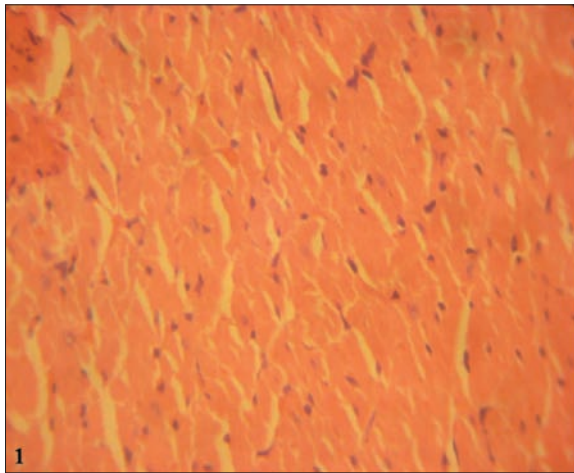
Histological assessment of the heart of the animals in the treatment group (B) showed significant alteration in the histological profile when compared with that of the animals in the control group. The histological alteration seen in the sections [Figure 1] of the heart in the treated group includes mild edema and occasional loss of myocardial fibers.

There was an alteration in the histological profile of the liver parenchyma of the animals in the treatment group. There were several patterns of vacuolation in the liver

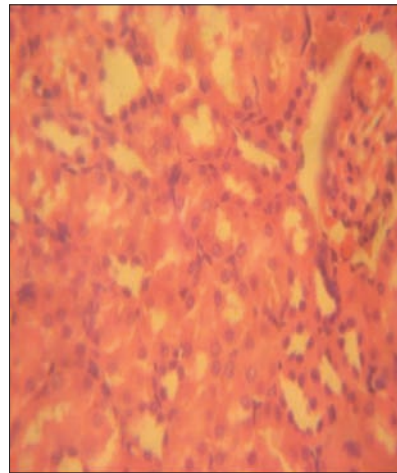
parenchyma. Also, using a stereological grid it was observed that there was gradual death of the hepatocytes, fewer populations of the sinusoidal lining cells, and degeneration of the cells lining the bile ducts [Figures 2 and 3].

The histological outline of the lungs of the animals in the treatment group revealed significant cytoarchitectural alterations [Figure 4]. Though the smooth muscle layer of the bronchi was preserved, yet the bronchi were occluded. There was also enlargement of the alveoli, the alveolar sacs, and alveolar hemorrhage.

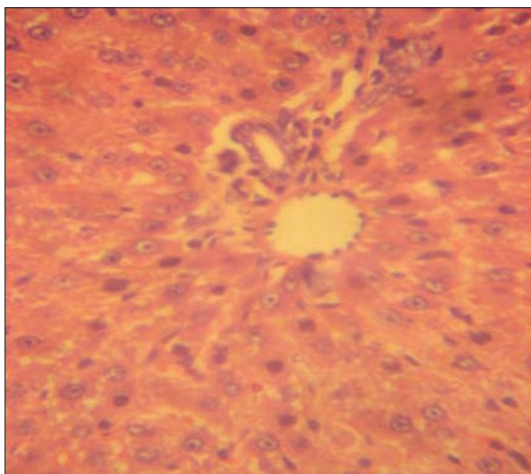
The histological profile of the kidney section [Figures 2 and 3] of the animals in the treated group exposed to the smoke extract of *Tobacco nicotiana* showed significant degenerative changes. In the renal cortex, the glomerulus was observed to consist of interstitial glomerular hemorrhage. There was also shrinkage of the glomerulus. Stereological assessment of the cells lining the tubular and



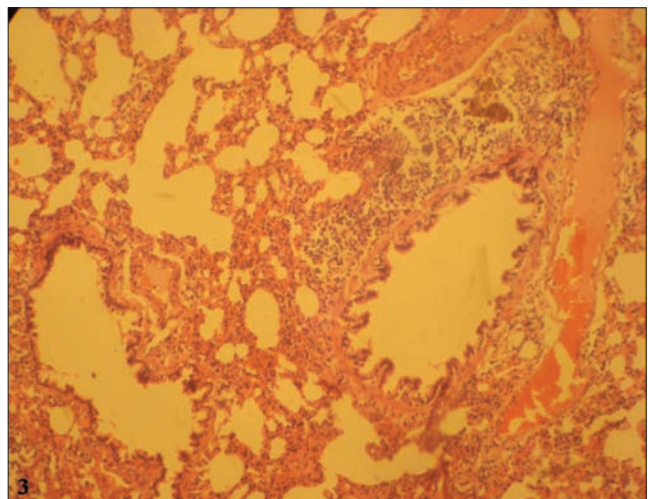
**Figure 1:** The section of the heart of the animals in the treated group with occasional destruction of myocardial fibers



**Figure 2:** The photomicrograph of the kidney section of the animals in the treated group with varying distortion of the renal cortex



**Figure 3:** The photomicrograph of the liver of the treated animals with degenerating hepatocytes with fewer population of the sinusoidal lining cells



**Figure 4:** The section of the lungs of the animals in the treated group with occlusion of the bronchi

collecting system of the kidney displayed degenerating cells.

Sections of the testes of the animals in the treatment group [Figure 5] revealed histological disruption and cellular derangement such as degeneration of the germ cells in the seminiferous tubules and also the degeneration of the leydig cells. Other effects such as cytoarchitectural distortions and vacuolations are evident in the section of the testes of the animals in the treatment group.

## DISCUSSION

Several findings from scientific investigation on the implications of Tobacco use on the brain of both man and laboratory animals,<sup>17-20</sup> have been published and a great deal of resources and man power have been invested in the eradication of the harmful effects of smoking on man's health. However there is dearth of scientific literature on the effects of smoke extract of *Tobacco nicotiana* on the histology of the heart, liver, lungs, kidney, and testes of male Sprague-Dawley rats as a marker of toxicity.

In this investigation, we examined some of the effects of the smoke extract of *Tobacco nicotiana* on the heart, liver, lungs, kidney, and testes of male Sprague-Dawley rats. From this investigation through the use of the Olympus binocular light microscope (XSZ-107BN, NO. 071771), it was observed that the smoke extract of *Tobacco nicotiana* has adverse and severe effects on the histology of the heart, liver, lungs, kidney, and testes of male Sprague-Dawley rats when compared with the control animals.

Effects of exposure of the treated animals to the smoke extract of *Tobacco nicotiana* on the lungs do not indicate any specific pattern of toxicity. The massive enlargement of the alveoli and alveolar hemorrhage could have occurred as a result of direct toxicity or could have resulted from transportation of toxic substances from other organs like the liver and kidneys to the lungs.

The section of the liver, kidney, and testes [Figures 2-5 respectively] obtained from the treatment group (B) has disrupted histological organization compared with the control group. Some of the deleterious effects seen in the section of the liver obtained from the treatment group following the use of a stereological grid include degeneration and disruption of the hepatocytes and also the degeneration of the cells lining the bile ducts. With these histological abnormalities, the functional integrity of the liver could be compromised. It is known that the hepatocytes play a vital role in the proper functioning of the liver as the hepatocytes are the main functional cells of the liver. The hepatocytes frequently contain glycogen and the hepatocytes maintain a steady level of blood glucose. This is one of the main sources of energy for use by the body.<sup>21,22</sup> A compromise in the integrity of the hepatocytes

could lead to improper functioning of the liver. The tubular structure of the renal cortex of the animals in the treatment group exposed to the smoke extract of *T. nicotiana* showed disruption in the histological makeup of the kidney. Varying patterns of cellular degeneration were seen in the proximal convoluted tubules which may compromise the functional integrity of the proximal convoluted tubules. This characteristic may lead to the retention of waste products of metabolism and persistence of such abnormalities may result in loss of the sensitive homeostatic mechanisms of the kidney.<sup>21</sup> The abnormal histological alterations seen in the testes of the animals in the treatment group include degeneration and disruption of the germ cells lining the seminiferous tubules and also the degeneration of the leydig cells. Following the use of stereological grid, it was observed that there was reduction in the population of the germ cells in the histological profile of the testes obtained from the treatment group compared with the control group. The implication of this is that there is a reduction of viable sperms which may lead to infertility.

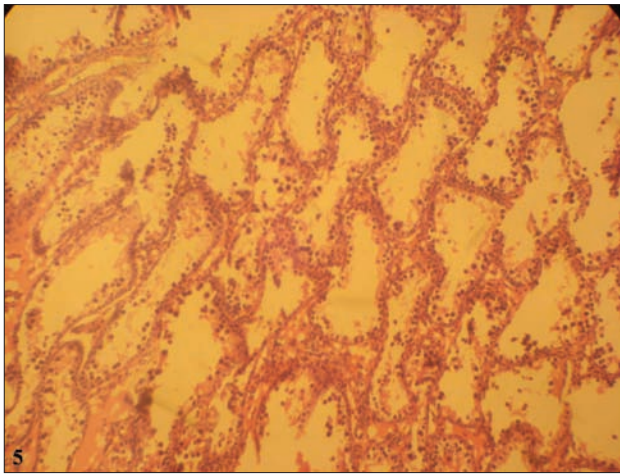
In this study, the smoke extract of *Tobacco nicotiana* may have acted indirectly through generation of high levels of ROS or directly as toxin to the heart, liver, lungs, kidney, and testes, thereby affecting their cellular and functional integrity. In cellular necrosis, the rate of progression depends on the severity of the insults. The greater the severity of the insults the more rapid the progression of the injury.<sup>23</sup> The principle holds true for toxicological insult to the brain and other organs.<sup>24</sup> Thus, it can be inferred from this result that the exposure of male Sprague-Dawley rats to the smoke extract of *Tobacco nicotiana* resulted in toxic effects on the studied organs.

This investigation confirmed that smoking *Tobacco nicotiana* 5 min three times daily for 5 days has toxic and disruptive interference on cellular integrity of the heart, liver, lungs, kidney, and testes of male Sprague-Dawley rats and by extension may adversely affect the functional integrity of these organs. The heart, liver, lungs, kidney, and testes of the animals in the control group (A) displayed better histological features [Figures 6-10 respectively]. There were no degenerative and/or disruptive changes, cellular hypertrophy in the sections of the heart, liver, lungs, kidney, and testes obtained from the animals in the control group.

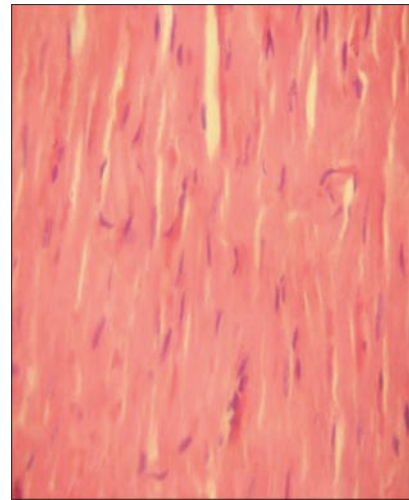
## CONCLUSION

The effects of smoking on human health are serious and in many cases, deadly. Smoking is associated with higher levels of chronic inflammation.

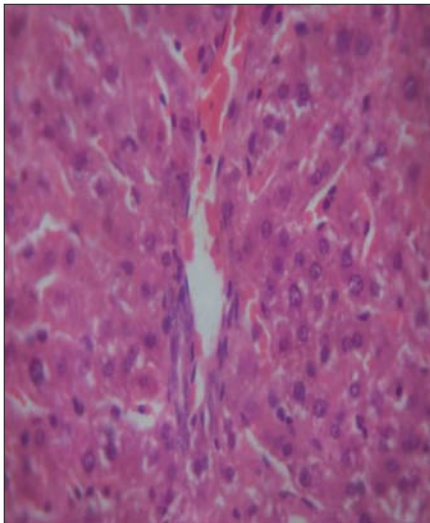
Data obtained from this study show that exposure to the smoke extract of *Tobacco nicotiana* on the heart, liver, lungs, kidney, and testes have deleterious effects on the cytoarchitecture of these organs in male Sprague-Dawley



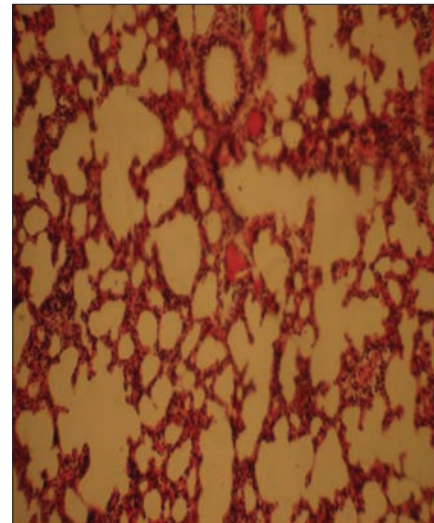
**Figure 5:** Distortion and gradual reduction in the population of the germ cells and the degeneration of the leydig cells in the seminiferous tubules of the animals in the treated group



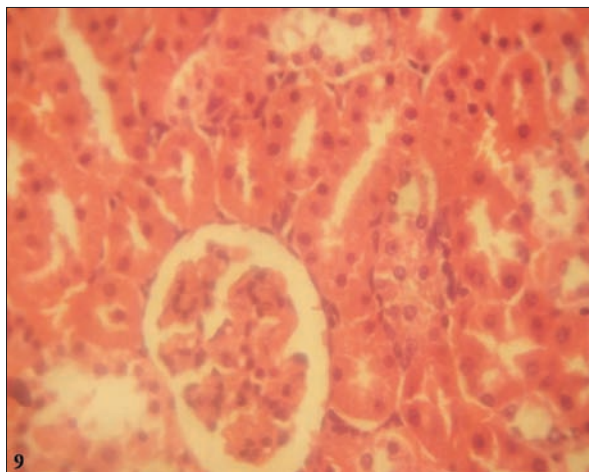
**Figure 6:** The photomicrograph of the lungs of the animals in the control group with a preserved histological profile



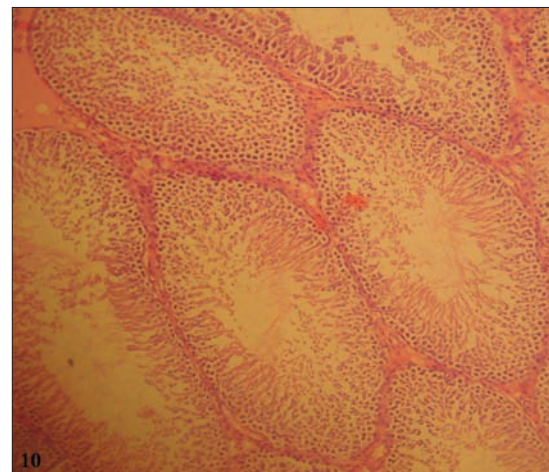
**Figure 7:** The well preserved histological outline of the liver of the animals in the control group



**Figure 8:** Photomicrograph of the lungs of the animals in the control group



**Figure 9:** The kidney of the animals in the control group with preserved histological outlines



**Figure 10:** Histological outline of the testes of the animals in the control group with a better histological outline

rats. It was observed in this investigation that the exposure of male Sprague-Dawley rats to the smoke extract of *Tobacco nicotiana* have the potentials of causing structural damage to the histological profile of some vital organs.

Considering some of the effects of the smoke extract of *Tobacco nicotiana* on the histological integrity of the heart, liver, lungs, kidney, and testes in male Sprague-Dawley rats, users (man) should be properly educated on the use of the plant considering the negative impact it conferred on the heart, lungs, kidney, liver, and testes in the treated animals in this investigation.

## REFERENCES

1. Wells AJ. Passive smoking as a cause of heart disease. *J Am Coll Cardiol* 1994;24:546-54
2. Kawachi I, Colditz GA, Speizer FE, Manson JE, Stampfer MJ, Willett WC, *et al.* A prospective study of passive smoking and coronary heart disease. *Circulation* 1997;95:2374-9.
3. Nurkiewicz TR, Porter DW, Barger M, Castranova V, Boegehold MA. Particulate matter exposure impairs systemic microvascular endothelium-dependent dilation. *Environ Health Perspect* 2004;112:1299-306.
4. Tobacco composition. Available from: <http://www.devilfinder.com>. [Last viewed 2010 Nov 25].
5. Nichter M, Cartwright E. Saving the children for the tobacco industry. *Medl Anthropol Quart* 1991;5:236-56.
6. Available from: [http://www.who.int/entity/healthinfo/global\\_burden\\_disease/GBD\\_report\\_2004\\_update/WHO\\_global\\_burden\\_of\\_disease\\_report\\_2008](http://www.who.int/entity/healthinfo/global_burden_disease/GBD_report_2004_update/WHO_global_burden_of_disease_report_2008). [Last accessed on 2010 Nov].
7. Available from: [http://www.who.int/entity/tobacco/mpower/mpower\\_report\\_prevalence\\_data](http://www.who.int/entity/tobacco/mpower/mpower_report_prevalence_data); WHO Report on the Global Tobacco Epidemic, 2008. [Last accessed on 2010 Nov].
8. Available from: [http://www.cdc.gov/tobacco/quit\\_smoking/you\\_can\\_quit/nicotine.htm](http://www.cdc.gov/tobacco/quit_smoking/you_can_quit/nicotine.htm); Nicotine: A Powerful Addiction." Centers for Disease Control and Prevention. [Last accessed on 2010 Nov].
9. Available from: <http://www.tobaccoprogramme.org/tobaccorefguide/ch12/ch12p1.htm>; The Tobacco Reference Guide. [Last retrieved on 2006 Aug 15].
10. Peate I. The effects of smoking on the reproductive health of men. *Br J Nurs* 2005;14:362-6.
11. Korenman SG. Epidemiology of erectile dysfunction. *Endocrine* 2004;23:87-91.
12. National Institutes of Health Guide for the Care and Use of Laboratory Animals: DHEW Publication (NIH), revised. Office of Science and Health Reports, DRR/NIH, Bethesda, USA; 1985.
13. Yakubu MT, Akanji MA, Oladiji AT, Olatinwo AO, Adesokan AA, Yakubu MO, *et al.* Effect of *Cnidioscolous aconitifolius* (Miller) I.M. Johnston leaf extract on reproductive hormones of female rats. *Iran J Reprod Med* 2008;6:149-55.
14. Adekomi DA. Madagascar periwinkle (*Catharanthus roseus*) Enhances Kidney and Liver Functions in Wistar Rats. *Int J Biomed Health Sci* 2010;6:245-54.
15. Disbrey BD, Rack JH. *Histological Laboratory Methods*. Edinburgh: Livingstone; 1970. p. 56-128. ISBN 0443006946.
16. Drury RA, Wallington EA. *Carleton's Histological Technique*. 4<sup>th</sup> ed. London: Oxford University Press; 1967. p. 120-3.
17. Otsuka R, Watanabe H, Hirata K, Tokai K, Muro T, Yoshiyama M, *et al.* Acute effects of passive smoking on the coronary circulation in healthy young adults. *JAMA* 2001; 286:436-41.
18. Talbot P, DiCarlantonio G, Knoll M, Gomez C. Identification of cigarette smoke components that alter functioning of hamster (*Mesocricetus auratus*) oviducts *in vitro*. *Biol Reprod* 1998;58:1047-53.
19. Benowitz NL, Hall SM, Herning RI, Jacob P 3rd, Jones RT, Osman AL. Smokers of low-yield cigarettes do not consume less nicotine. *N Engl J Med* 1983;309:139-42.
20. Blake J, Smith A. Effects of smoking and smoking deprivation on the articulatory loop of working memory. *Hum Psychopharmacol* 1997;12:259-64.
21. Stevens A, Lowe J. *Human Histology*, 3<sup>rd</sup> ed, Chapter 12. Philadelphia: Elsevier Mosby; 2005. p. 232. ISBN 0-3230-3663-5.
22. Junqueira LC, Carneiro J. *Basic Histology*. 10<sup>th</sup> ed, Lange ed, Chapter 16. New York: McGraw Hill; 2003. p. 340. ISBN 0-07-121565-4.
23. Ito U, Sparts M, Walker JR, Warzo I. Experimental cerebral ischemia in magolian gerbils (1), light microscope observations. *Acta Neuropathol USA* 2003;32:209-23.
24. Martins LJ, Al-Abdulla NA, Kirsh JR, Sieber FE, Portera-Cailliau C. Neurodegeneration in excitotoxicity, global cerebral ischaemia and target deprivation: A perspective on the contributions of apoptosis and necrosis. *Brain Res Bull* 1978;46:281-309.

**How to cite this article:** Adedayo AD, Tijani AA, Musa AA, Adeniyi TD. Histological study of smoke extract of *Tobacco nicotiana* on the heart, liver, lungs, kidney, and testes of male Sprague-Dawley rats. *Niger Med J* 2011;52:217-22.

**Source of Support:** Nil, **Conflict of Interest:** None declared.