

## A Review Of Pectoralis Major Musculocutaneous Island Flap In Head And Neck Reconstruction In Ibadan

O.M. Oluwatosin, F.O. Abikoye, V.O. Adegboye, A. I. Brimmo and J.T. Arotiba

*Department of Surgery, University College Hospital, Ibadan, Nigeria*

### ABSTRACT

Like microvascular free flaps, pectoralis major flaps can be transferred in a single stage and have largely replaced deltepectoral (Bakanjian) flap in head and neck reconstruction. This retrospective study was carried out to highlight the usefulness of this flap in different situations. Ten patients, aged six to 55 years operated on in a six-year period at the University College Hospital, Ibadan are presented. Indications for surgery were gun short trauma (2), pharyngocutaneous fistula (2), oesophageal stricture (2) and tumours (4). There was a 100% success rate. Neck web rate was 30% and these were revised at a second stage. Our modification to suit three-layer coverage is discussed. The pectoralis major muscle flap is a simple and reliable flap useful in head and neck reconstructions (*Nig J Surg Res 2000; 2: 16-20*)

*KEY WORDS: Pectoralis major musculocutaneous flap, osseomusculocutaneous flap; head and neck reconstruction*

### Introduction

When local tissue cannot close a head and neck defect, the surgeon has to resort to distant tissue reconstruction.<sup>1</sup> The choice lies between a pedicled and a free tissue transfer. Free tissue transfer involves microvascular anastomosis, which requires expertise, and facilities, which are not available in most centers in the West African sub region. Reconstructive surgeons, therefore, often have to settle for the use of pedicled flaps in the repair of defects in the head and neck.

The use of pectoralis major flap has been established since it was first described by Ariyan in 1979.<sup>2</sup> Its anatomy has been described by several authors.<sup>3-6</sup> Apart from segmental supply by perforators from intercostals and internal mammary vessels, the sternocostal portion of the muscle is supplied by the pectoral branch of the acromiothoracic axis. This branch emerges medial to the insertion of pectoralis minor and runs laterally and inferiorly for a short distance in fatty areolar tissue. It then enters the deep surface of the muscle to run along with lateral

pectoral nerve in an axis, which coincides with a line drawn from the tip of the shoulder to the xiphisternum. Based on the aforementioned vascular pedicles, the muscle can be transferred in different ways. For example, when detached from its origin, it can be turned over across the midline to cover a sternal defect such as that obtained after debridement for sternal osteomyelitis. The lower fibers of the muscle can be transferred with underlying rib (s) and a paddle of skin as a true island flap, which can be based on the pectoral branch of acromiothoracic vessel. This island of muscle and skin can be tunneled through chest and cervical tissues to reach its destination in the head and neck. Indications for this type of transfer are varied and this review presents such diversity as experienced in Ibadan in the reconstruction of head and neck defects.

---

*Reprint requests to: Dr. O.M. Oluwatosin, Department of Surgery University College Hospital, P.M.B.5116, Ibadan. Email. aoluwatosin@yahoo.com*

---

### Patients And Method

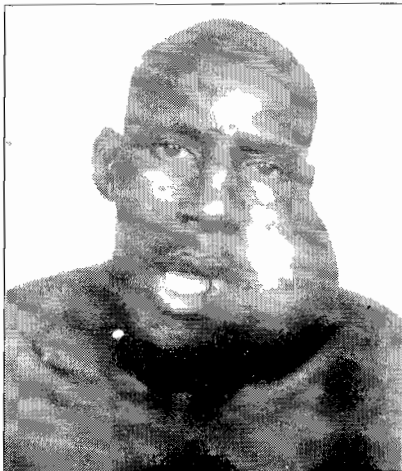
Patients who had head and neck effects and who were operated on by the Plastic surgery unit sometimes in collaboration with Cardiothoracic surgery unit Otorhinolaryngology and Maxillofacial surgery departments of University College Hospital, Ibadan between January 1993 and September 1999 form the basis of this review. Information obtained were; age, sex, lesion or diagnosis, defect size, flap choice, flap outcome and complications.

### Results

Ten patients had head and neck reconstruction with pectoralis major musculocutaneous and osseomucocutaneous pedicled flaps. Age range was 6 - 55 years and M:F ratio 1:1. The indications for surgery (Figure 1) were post tumour excision 4, trauma 2, pharyngocutaneous fistula 2 and oesophageal stricture 2.

All, except case 2 (Table 1) had defects, which were covered with musculocutaneous flaps. Case 2 had an oseomusculocutaneous flap incorporating the right fifth rib, which was used for mandibular reconstruction. Cases 1,3,4 and

*Figure 1: Patient With Mandibular Osteosarcoma With Extensive Oral Mucosal Involvement*



6, had the skin paddle used for oral lining. In these four cases, the muscle was covered with split skin graft harvested from the thigh. Both fistulae, after excision, and oesophageal stricture after release and excision, were lined by the skin component of the flap. The smallest defect was that obtained after excision of fistula and the largest, 9cm x 9cm, after excision of parotid adenecarcinoma.

Flaps that could be monitored through their skin paddles were seen to have developed no necrosis. There was excellent (>90%) graft take on those that were grafted. Cessation or absences of leakage in cases with pharyngoesopohageal defects are indications of complete flap survival. Thus there was 100% flap survival rate in this series. There were no wound infections. Three patients had obvious skin webbing (Figure 2) over the pedicle. This necessitated revision procedure in which the pedicle was excised and the web skin rearranged by Z - plasties at a period greater than two weeks post operation.

*Figure 2: After Excision Of 70% Of The Mandible Including Island Flap Transfer. The Skin Paddle Has Been Used For Oral Lining. Note The Web On The Left Side Of The Neck*

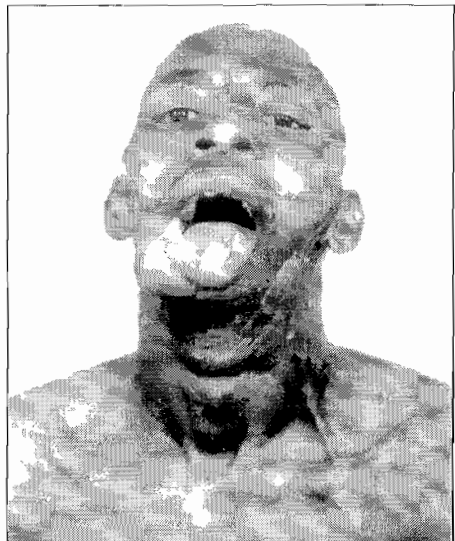


Table 1: Summary Of Cases That Had Head And Neck Reconstruction At Ibadan

Patient	Age	Sex	Diagnosis	Defect C	losure	Complication
1	12	F	Leiomyosarcoma of the right cheek	6cmx7cm	PMMCF+SSG	Sound dehiscence at oral commissure, lost to follow up
2	24	M	Gunshot Injury, lip and mandible	6cmx7cm	PMOMCF	Died on 5 <sup>th</sup> postoperative day from respiratory complication
3	32	M	Osteosarcoma, mandible	8cmx8cm	PMMCF-SSG	Skin web over pedicle, revised
4	55	F	Extensive left parotid adenocarcinoma	9x9cm	PMMCF+SSG	Dehiscence at oral commissure, web over pedicle; revised
5	55	F	Pharyngocutaneous fistula	4cmx5cm	PMMCF	Skin web over pedicle; revise
6	45	M	Gunshot injury, neck and mandible	4cmx7cm	PMMCF+SSG	Nil
7	50	F	Pharyngocutaneous fistula, post laryngectomy	6cmx3cm	PMMCF	Structure; responded to bouginage
8	40	F	Squamous cell carcinoma, lower lip and month	6cmx5cm	PMMCF	Died 3 weeks postoperative from chest secondaries
9	6	M	Oesophageal stricture after oesophagagastrotomy	5cmx4cm	PMMCF	Initial leakage of dye on 10 <sup>th</sup> day postoperative which stopped
10	8	M	Oesophageal stricture after oesophargastrotomy for corrosive stricture	5cmx4cm	PMMCF	Intestinal obstruction, sequela of previous operation

*PMMCF* = Pectoralis major musculocutaneous flap

*PMOMCF* = Pectoralis major osseomusculocutaneous flap

*SSG* = Split skin graft

All donor sites were closed by direct suture. However, they healed mostly with stretched scars, especially in those who had large defects to cover. Nipple/areolar distortion occurred in cases 4 and 5. The patient that had an osseomusculocutaneous flap elevation required closed thoracostomy tube drainage. Subcutaneous drains were left longer than usual,

approximately for five days. There were no subcutaneous collections or wound infection.

There was wound dehiscence at oral commissure in both cases that had extensive lip coverage. Some of the major complications were unrelated to the flap reconstruction. These included intestinal obstruction in one of the patients who had undergone

oesophagogastrostomy for stricture. Chest secondaries developed in a patient whose histology after excision revealed undifferentiated carcinoma.

## Discussion

Before free flaps became popular in reconstructive surgery the most widely used flap for repair of large head and neck defects was the pectoralis major flap.<sup>7</sup> It is conveniently located and simple to raise. Its use does not involve the expertise required for free microvascular transfer. Thus, it is a flap that can be utilized by non plastic surgeons. One of the flaps reported here was raised and transferred by a thoracic surgeon. The pectoralis major flap can be raised quickly and particularly within a few minutes in children who have little muscle bulk. The present report confirms that it usually results in successfully healed wounds with minimal flap complications. Like free flaps it can be transferred in a single stage and in this it differs from deltopectoral flap,<sup>8</sup> which was popular among head and neck surgeons before the development of muscle flaps. Some authors<sup>5,9,10</sup> have reported a modification of slitting the muscle longitudinally to carry double skin paddles oriented parallel to the muscle fibres. In this modification, while the medial paddle retains the blood supply from the pectoral branch of the acromiothoracic artery, the lateral paddle derives its supply from the lateral thoracic artery. This method, however, requires abundant skin for such double paddle. Large defects on the face like those in this report cannot be so treated. In such cases, therefore, the flap is lifted in the conventional way with one skin paddle, which is turned in for lining. The muscle component of the flap is then covered with skin graft. In this way, donor site disability is reduced and while at same time reducing the bulk, which may constitute a cosmetic problem in facial reconstruction.

Pectoralis major flap is most suited for head and neck defects that require bulk. In patients who have not had a neck dissection its passage through the neck sometimes produces a web, which usually requires a dissection and excision of the pedicle at a later date, at which time the flap may be inset. No such webbing was noticed in patients who had reconstruction in the neck like oesophageal and pharyngeal fistula closure. Transferring the pectoralis muscle as a true island flap with the skin paddle raised as far distally as possible produces an increased pedicle length and thus a greater arc of rotation, which in some of our patients reached the zygoma, and contralateral aspect of the lip at the same time.

In conclusion, we have highlighted the wide variety of indications for the use of pectoralis muscle flap in head and neck reconstruction. Some modifications based on local experience have also been discussed. Being a flap that is relatively easy to elevate and one that suffers minimal complications, it should be used more frequently in head and neck reconstruction, particularly where volume requirements are large as in many cases presenting in our environments.

## References

1. Palmer JH, Barchelor AG. The functional pectoralis major musculocutaneous island flap in head and neck reconstruction. *Plast Reconstr Surg* 1999; 85: 363-367
2. Ariyan S. The pectoralis major myocutaneous flap. A versatile flap for reconstruction in the head and neck. *Plast Reconstr Surg* 1979; 63: 73-81
3. Wei WI, Lam KH, Wong J. The true pectoralis major myocutaneous island flap: an anatomical study. *Br J Plast Surg* 1984; 37: 568-573

## PECTORALIS MAJOR MYOCUTANEOUS FLAP IN HEAD AND NECK RECONSTRUCTION

4. Reid CD, Taylor GL. The Vascular territory of the acromiothoracic axis. *Br J Plast Surg* 1984; 37: 194-212
5. Freeman JL, Walker RP. The vascular anatomy of the pectoralis major myocutaneous flap. *Br J Plast Surg* 1981; 34:3-10
6. Tobin GR. Pectoralis major segmental anatomy and segmentally split pectoralis major flaps. *Plast Reconstr Surg* 1985; 75: 814- 824
7. Kroll SS, Rescue GP, Miller MJ, Schustorman NA. Comparison of the rectus abdominis free flap with the pectoralis major myocutaneous flap for reconstruction in the head and neck. *Am J Surg* 1992; 164: 615-618
8. Bakamjian VU. A two-stage method for pharyngo-oesophageal reconstruction with a primary pectoral skin flap. *Plast Reconstr Surg* 1965; 36: 73-183
9. Tobin GR, Bland KI, Adock R. Surgical anatomy of the pectoralis major muscle and neurovascular supply. *Surg Forum* 1981; 32: 575.
10. Weaver AW. Modified bilocular (gemini) pectoralis major myocutaneous flap. *Am J Surg* 1982; 144: 489-493