

## Mediastinal teratomas: CT evaluation in 2 patients

M. O. Obajimi, C. O. Akinsanya and \*V. O. Adegboye

Departments of Radiology and \*Surgery, University College Hospital, Ibadan, Nigeria.

Reprint requests to: Dr. M. O. Obajimi..

### ABSTRACT

This is a report of 2 males aged 48 years and 50 years respectively presenting with persistent cough. Computed tomography showed posterior and anterior mediastinal masses respectively. Needle aspiration and cytology confirmed teratoma, with sarcomatous change in the first patient. Due to advanced disease only radiotherapy was offered but the patient died after a few courses. The other patient had excision of the mass, confirmed to be a benign teratoma. Computed tomography is invaluable in the diagnosis of mediastinal teratomas.

*Keywords: Teratoma, Mediastinal, CT scan*

### Introduction

Computed Tomography (CT) has transformed the imaging of several parts of the body including the chest. Mediastinal imaging has indeed received a boost from it.<sup>1, 2</sup> Its unique ability to characterise tissue densities is an asset in the diagnosis of teratomas.

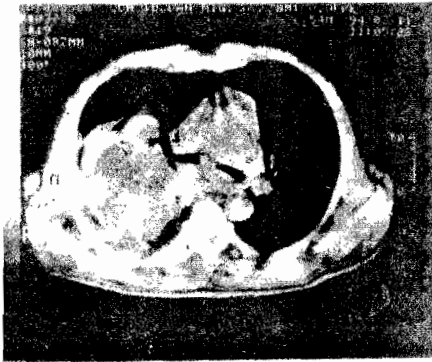
### Case reports

Case 1: A 48-year-old man was referred from another hospital with a 3-month history of cough, weight loss and haemoptysis. He had been given a diagnosis of pulmonary tuberculosis at that hospital after investigations and had

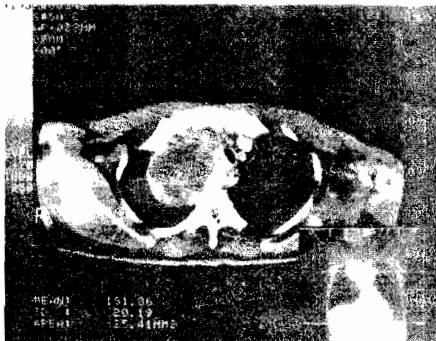
been commenced on anti tuberculous drugs. On completion of the drugs there was no radiological improvement. He was then referred to our hospital where further investigations were carried out; chest radiographs showed a huge lobulated opacity in the right hemithorax obliterating the ipsilateral mediastinum but sparing the hemidiaphragm. There were no calcifications and no destruction of overlying ribs. Lateral film showed most of the opacity to be in the posterior mediastinum. A computed tomography (CT) scan confirmed the above findings but the axial slices showed a lobulated mass in the right lung occupying its posterolateral aspect (Figure 1). This extended medially into the ipsilateral

mediastinum in the midline. There was also destruction of adjacent ribs and ipsilateral pleural reaction. There were hypodense areas of necrosis within the mass and the right main bronchus was elevated.

*Figure 1: Non-enhanced axial CT image of the chest showing a right posterior mediastinal mass. An area of central hypodensity is also noted.*



*Figure 2: A contrast enhanced CT axial image showing an enhanced border with a central hypodense lobulated area. The lesion is seen in the anterior mediastinum, displacing the trachea and vessels to the left.*



The advanced stage of the tumour precluded surgical intervention. A fine needle aspiration biopsy confirmed a teratoma with sarcomatous transformation. The patient was referred for radiotherapy but died after a few courses of radiotherapy.

**Case 2:** A 50-year-old man presented with an unresolving cough for 6 weeks. There was a 6 years history of previous post-primary tuberculosis for which he had treatment. The current episode of cough had been treated with antitussive drugs and antibiotics without improvement. The cough was posturally dependent and productive of copious purulent sputum but no haemoptysis or weight loss. Sputum was negative for acid-fast bacilli, and culture yielded bacteria sensitive to erythromycin. Plain chest radiographs showed an anterior mediastinal shadow with associated changes of pulmonary tuberculosis and bronchiectasis in the left upper lobe.

A CT scan of the chest showed an isodense mass in the right side of the anterior mediastinum. The mass showed a lateral convex border and was indistinguishable from the adjacent upper cardiac margin. It displaced the ascending part of the aorta to the left and had no calcifications. Left upper lobe fibrosis and bronchiectatic changes in the lung was confirmed in the axial slices. Atelectatic segments were noted in the left lung.

The patient had a median sternotomy and excision of the anterior mediastinal mass. Histology confirmed a benign teratoma. He was commenced also on rifampicin, isoniazid and streptomycin to counter reactivation of pulmonary tuberculosis. Postoperative recovery was uneventful and he has remained well.

## Discussion

Mediastinal imaging over the past years has changed significantly with a shift from conventional radiographic techniques to increased utilisation of computerised axial tomography, the interpretation of which requires a basic understanding of the axial relationships between the major structures in the mediastinum.<sup>1, 2</sup> Most mediastinal teratomas are located in the anterior aspect in the region of the cardiac base where the great vessels join the heart.<sup>3</sup> They are rarely located posteriorly as in the first patient in this report.

Though conventional radiographs could classify the location of the masses the serial CT images were also more precise as it actually showed the relationship of the tumour to the sternum, vertebral bodies, pedicles and ribs. The several slices through which the mass is demonstrated are also useful in determining the actual size of the mass. Due to the contents of a teratoma, the cross-sectional slice of the soft tissue mass exhibit components of muscle, water and fat densities, all seen in a non-homogenous fashion as earlier reported.<sup>5</sup> Frequently, amorphous calcifications may be scattered throughout the tumour, representing malformed teeth of bones. Calcification is said to occur in about 25% of the benign variety. The presence of calcification in teratomas may suggest their benign nature.<sup>4, 5</sup> Layering has also been reported as a result of the fat and fluid level within the cystic cavity.<sup>1, 5, 6</sup> These were not seen in our cases. When

chest wall invasion is present as evidenced by rib destruction as in our first patient, a CT diagnosis of malignancy can be made. Another criterion for malignancy is the invasion of contiguous mediastinal structures. CT scan is important in the diagnosis of mediastinal teratomas. However, if all the CT diagnostic criteria are not present in particular lesion, a high index of suspicion is required to make a diagnosis.

## References

1. Moore AV, Silverman PM, Putman CE. Current concepts in computerised tomography of the mediastinum. *Critical Reviews in Diagnostic Imaging* 1985; 24: 11 – 15.
2. Luk'ianchneko AB, Ogurtsova IN. CT in the diagnosis of mediastinal tumours and cysts. *Radiol* 1987; 4: 53 – 59.
3. Leigh TF, Weens HS. Roentgen aspect of mediastinal lesions. *Semin Roentgenol* 1969; 4: 59.
4. Weinberg B, Rose JS, Efremidis SC, Kirschner PA, Gribetz D. Posterior mediastinal teratoma (cystic dermoid). *Diagnosis by computed tomography. Chest* 1980; 77: 694.
5. Rebner M, Gross BH, Robertson JM et al. CT evaluation of mediastinal masses. *Radiol* 1987; 11: 103 – 110.
6. Suzuki M, Jakashima T, Itoh H et al. CT of mediastinal teratomas. *Journal of Computer Assisted Tomography* 1983; 7: 74 – 76.