

Repair of Extensive Composite Alar Defects with Single Stage Nasolabial Turnover Flap and Auricular Composite Graft

O.M. Oluwatosin

Department of Surgery, University College Hospital, Ibadan.

Reprint Requests to: Dr. O.M. Oluwatosin, Division of Plastic Surgery, Department of Surgery, University College Hospital, Ibadan, Nigeria.

ABSTRACT

Extensive and total (through and through) loss of ala or lobule of the nose as seen in severe traumas and neglected tumours should be replaced by the three anatomical layers of skin, cartilage and vestibular lining. A technique of nasolabial turnover flap transfer covered by a two layered auricular chondrocutaneous graft is described for reconstructing such total losses >1.5 cm. The method of survival of large volume chondrocutaneous grafts is described as well as the advantages of this technique over other alternatives.

KEY WORDS: Alar defects, Repair

Introduction

Auricular chondrocutaneous grafts are employed in the management of small through and through defects of the alar rim. Such a graft enables replacement of the two nasal skin surfaces lost as well as the cartilage to replace rigidity.¹ First described by Konig² in 1902, these grafts were popularized in Europe by Gilles³ and in the United States by Brown and Cannon.⁴

It is a known fact that the take of this graft tends to be less than complete.¹ This is because of the

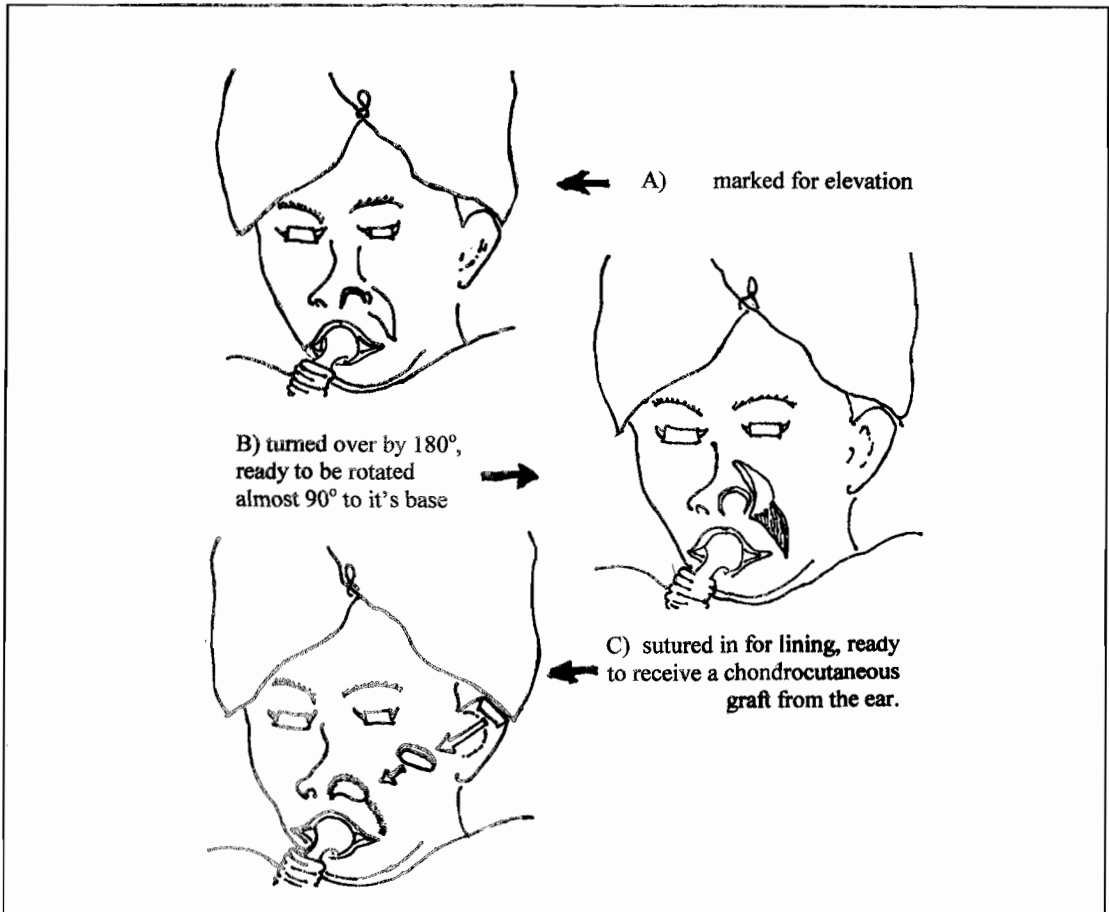
comparatively greater volume of the graft compared to the relatively smaller contact afforded by the dermal edges of the recipient site. Most surgeons believe that to ensure survival, the upper limit of the size of the graft should be a length of 1.5 cm.⁵

Cooling the composite graft to lower its metabolic rate and slow autolysis thereby protecting the graft until revascularisation occurs has been found to improve the take.⁶ Repair of a larger alar defect such as may be seen in major traumas however requires employment of another method of

closure. This is a report of a procedure in which the recipient contact surface is enlarged to accommodate and afford a

greater chance of survival for a much larger volume of composite graft.

Figure 1: Diagrammatic Representation of Alar Reconstruction with a Nasolabial Flap



Technique

Infiltration of both donor sites; ipsilateral nasolabial region, and ear with dilute adrenaline, 1:200,000 solution facilitates the dissection. The

nasolabial flap is elevated in a superficial subcutaneous plane based superiorly on the angular artery which connects the facial artery to the dorsal branch of the ophthalmic artery at the piriform aperture. This level of

dissection enables elevation of a thin flap. The flap is next turned over, as in turning the page of a book by almost 180°, and rotated 90° to its base⁷ towards the defect, figure 2. In this way, the skin surface is turned in and is sutured in place using 5/0 chromic catgut to provide lining for the nostril. At the same time, its raw subcutaneous part presents the subdermal plexus of vessels to nourish the composite graft. The flap donor site is closed directly (Figure 1).

A chondrocutaneous graft is taken from the helical margin of an ear. This is done such as to exclude skin on anterolateral aspect of the ear thus harvesting one cutaneous surface along with the cartilage. The level of separation is such as to include the perichondrion in the graft. Closure of the defect may be achieved by direct apposition or in the extreme case by helical advancement.

The graft is next laid on the flap with perichondrion in contact with the raw dermal surface of the flap. Care is taken in handling the graft which should not be held with dissecting forceps. Hand^d handling with saline moist gauze is desirable. Skin apposition should be meticulously carried out with atraumatic reverse cutting 6/0 nylon leaving a few areas through which a 5/0 vicryl or dixon may be passed to enable a tie over dressing application. This ensures better contact of the graft with the flap. The result of the use of this technique in two cases is given in the observation that follows.

Post operative clinical observation:

When tie over dressing and stitches were removed on 5th post operative day, the skin surface of the

graft showed more extensive epidermolysis than that often observed on full thickness skin grafts. Subsequent process of healing and consolidation was also slower (than that obtained in full thickness skin grafts). Colour observations were not possible because the surgery was performed on patients with pigmented skin and however tie over dressings were utilized in the first five days which were the days that were crucial for observation. The healed surface showed minimal scars hidden in the alar crease and nasolabial fold. Alar texture was also satisfactory. No obstruction of the nostril was observed and there was no collapse of the nasal cavity on breathing up to two years after repair in one patient while the other patient did not report for follow up for longer than about four months postoperatively.

Discussion

Neglected tumours and severe traumas causing extensive losses that involve the nasal lobule are occasionally treated in our unit. They pose a problem in treatment because of the complexity of arrangement of tissues around the tip of the nose. This complexity consists of paired alae overlying the membranous septum. Nasal ala shows internal keratinised skin that lies in close contact with alar cartilage.⁸ External to cartilage, there is a thin subcutaneous layer over which lies a skin cover which is about 2.4mm thick.⁹

In planning alar reconstruction, when one of the two epithelial surfaces is intact, support and cover can often be delivered reliably but if substantial amount of all three layer are lacking, the

reconstruction becomes more complex⁵. This is evidenced by the cases under review. When however a nasolabial flap is turned over, it provides the desired epithelial surface.

While "plasmatic imbibition" is a known factor in the survival of skin grafts¹⁰, its effect in nourishing larger composite graft is limited. McLaughlin¹¹ has suggested that composite ear grafts survive in the first few days by direct contact, - lumen to lumen - of many tiny vessels. The contact surface though limited furnishes several capillaries because of the extensive vascularity of the nasal region. Davis and Traut¹², who proved that anastomoses of capillaries occurred very early being noted within the first 22 hours after grafting, had demonstrated this idea earlier. This initial nutrition of composite grafts is enhanced through contact of capillaries of a nasolabial flap bed with those of an intact perichondrion in the composite graft. Greater survivals of large composite grafts are therefore ensured by inclusion of perichondrion on the cartilage side. There should be minimum handling of such surfaces. Scarring or irradiation should not have compromised surrounding vasculature.

Survival of these grafts after the first few days takes place through such connection by capillary budding into the graft which is known to occur from about third day after grafting. This reaches it's peak between days 10 and 12.¹³ The nasolabial turnover flap / composite graft combination which is hereby being reported combines the advantage of producing the three layers of the nostril with transfer in a single stage.

Alternatives to the use of this combination of composite graft over

nasolabial turnover flap for repair of large ala defects will next be mentioned. Each of them however has one disadvantage or the other that makes it less useful than the combination being reported. First of all a nasal or paranasal flap, for example, a superiorly based nasolabial flap,¹⁴ lined internally by auricular chondrocutaneous,¹⁵ nasal septal chondromucosal,¹⁶ or hard palatal mucosal¹⁷ graft is a possibility. The healing mechanism is similar to that enumerated above. Such nasolabial flap however sometimes have significant dog's ear that may require a second stage procedure.

Another alternative is the use of a superiorly based nasolabial flap whose distal tip may be folded in for lining. Most authors recommend a delay procedure for this method⁵. On a similar note, the nasolabial turnover flap elevated in a similar way as that in this paper can be folded on itself to provide external skin cover.⁷ In order to be folded over successfully this flap too requires a delay procedure thus adding the disadvantage of a second stage. Hunt's concept of using posterior auricular skin as a flap based on the anastomosis of superficial temporal artery and postauricular artery was refined by Washio¹⁸ and others. It provides thin auricular skin and thicker mastoid skin combined with ear cartilage. It however carries the disadvantage of requiring a second stage of division of flaps.

To avoid a second stage of the Washio flap reconstruction, the posterior auricular skin has been transferred as a free flap based on postauricular artery.¹⁹ Similarly the root of the helix can be transferred as a composite free flap based on superficial

temporal artery.²⁰ While both bear the advantage of being carried on relatively large vascular pedicles, the expertise and tools for microvascular transfer are required.

In conclusion, the combination of composite graft over nasolabial turnover flap is suitable for single stage repair of large alar defects. This is particularly useful in situations where the expertise for microvascular transfer is lacking and the patient is unfit for prolonged anaesthesia for free flap transfer as a result of chronic renal, pulmonary or hepatic disease.

References

1. MacGregor IA, MacGregor FM. Cancer of the face and mouth. Churchill Livingstone, Edingburg, 1986, pp 258-260.
2. Konig F. On filling defects of the nostril wall; cited in MacLaughlin CR. Composite ear grafts and their blood supply. Br J Plast Surg 1954; 7: 274-278.
3. Gilles HD. Plastic surgery of the face. London Oxford 1920.
4. Brown JB, Cannon B. Composite free grafts and cartilage from the ear. Surg Gynecol Obst 1946; 32: 253-255.
5. Barton FE.Jr. Nasal reconstruction (overview). Select Read Plast Surg 1991; 6: 1-31.
6. Rees TD et al. Composite free grafts. In: Transactions of third international congress of Plastic and Reconstructive Surgery. Washington excerpta medica, 1963.
7. Spear SL Kroll SS, Romm SA. New twist to to the nasolabial flap for reconstruction of lateral alar defects. Plastic Reconstr Surg 1987; 79: 915.
8. Natvig P, Sether LA, Dingman RO. Skin abuts skin at alar margins of the nose. Ann Plast Surg 1979; 2: 428-429.
9. Gonzales UM. Restoration of the face covering by means of selected skin in regional aesthetic units. Br J Plast Surg 1956; 9: 212-221.
10. Hinshaw JR, Miller FR. Histology of healing split thickness, full thickness autogenous skin grafts and donor sites. Arch Surg 1965; 91: 658.
11. McLaughlin CR. Composite ear grafts and their blood supply. Br J Plast Surg 1954; 7: 274-278.
12. Davis JS, Traut HF. Cited in Mclaughlin CR. Composite ear grafts and their blood supply. Br J Plast Surg 1954; 7: 274-278.
13. Hoopes JE. Pedicle flaps - an overview. In Krizek TJ, Hoopes JE (eds) Symposium on basic science in plastic surgery. Mosby, St. Louis, 1976, pp 241-259.
14. McLaren JR. Nasolabial flap repair for alar margin defects. Br J Plast Surg 1963; 16: 234- 238.
15. Texier M, Preaux J. Transposition of a skin flap from the nasolabial dorsum for repair of skin loss on the nasal wing. A propos of a clinical case. Ann de Chirurgie Plastique et Esthetique. 1996; 41: 319-331.
16. Guerrero Santos J, Dicksheet S. Nasolabial flap with simultaneous cartilage graft in alar reconstruction. Clin Plas Surg 1981; 8: 599-602.
17. Hatoko M Tada H and Shirai T. Usefulness of hard palate mucosa graft as nasal lining for reconst-

- ruction. *Plast Reconstr Surg* 1995; 95: 390-395.
18. Washio H. Retroauricular temporal flap. *Plast Reconstr Surg* 1969; 43: 162- 166.
19. Swartz WM. Microvascular approaches to nasal reconstruction. *Microsurg* 1988; 9: 150-153.
20. Shenaq SM, Dinh TA, Spira M. Nasal alar reconstruction with an ear helix free flap. *J Reconstr Microsurg* 1989; 5: 63-67.