

Triplication of Deciduous Teeth: A Rare Dental Anomaly

Suresh Yadav, Shallu Tyagi¹, Prince Kumar², Divya Sharma³

Departments of Oral and Maxillofacial Surgery and ¹Pedodontics and Preventive Dentistry, Kalka Dental College and Hospital, Meerut, ²Prosthodontics, Shree Bankey Bihari Dental College and Research Centre, Ghaziabad, Uttar Pradesh, ³Pedodontics and Preventive Dentistry, ITS Centre for Dental Studies and Research, Ghaziabad, India

ABSTRACT

Fusion of teeth is the union of two or more tooth germs, which are usually separated. Depending upon the stage of odontogenesis, it can be complete or incomplete. The present case describes fusion between the maxillary primary right central and lateral incisor with a supernumerary tooth. Clinical and radiographic examination revealed the presence of fused triple teeth. The fused teeth were extracted, sectioned and were visualized under stereomicroscope at three levels and the diagnosis of fusion of three teeth was confirmed histologically.

KEYWORDS: Fusion, primary teeth, supernumerary tooth, triple teeth

Address for correspondence:

Dr. Prince Kumar,
Department of Prosthodontics, Shree Bankey Bihari Dental College and Research Centre, Masuri, N.H. 24, Ghaziabad, Uttar Pradesh, India.
E-mail: princekumar@its.edu.in

Access this article online

Quick Response Code:



Website: www.nigerianjsurg.com

DOI:
10.4103/1117-6806.119244

INTRODUCTION

Fusion is defined as union between the dentine and/or enamel of two or more separate developing teeth. It can be complete with the formation of one abnormally large tooth or incomplete, with the fusion of crown or fusion of roots only. The prevalence of this anomaly is estimated as 0.5-2.5% in the primary dentition with a lower prevalence in the permanent dentition.^[1] Fusion of primary teeth can appear in several ways, usually involving two teeth, but occasionally three.^[2]

Triplication of primary teeth is a rarer phenomenon with prevalence of 0.02%.^[2] Primary triple teeth suggest an idiopathic abnormality in the distribution of the dental material originated very early in the dental development. It can be an early double fusion between three tooth germs, initially separate, but enclose proximity and developing synchronically.^[3]

Rarely supernumerary teeth may be fused to normal teeth in the arch, usually by medial or lateral fusion. Supernumerary teeth are seen in frequently in the primary dentition with the prevalence rate of 0.2-0.8%.^[4]

Problem associated with fused teeth includes esthetics, caries, periodontal disease, malocclusion, delayed exfoliation; impaction of their successor, other developmental and functional problems. This article reports the case of unusual

fusion of three teeth in a 10-year-old boy involving one supernumerary, maxillary right deciduous central and lateral incisor.

CASE REPORT

A 10-year-old boy reported to the dental clinic with the chief complaint of large tooth in the maxillary anterior region of the jaw. No other member of the family was affected with similar dental anomaly and patient was mentally challenged. Intraoral examination revealed that the patient was in mixed dentition phase along with fusion of the maxillary right primary central incisor and primary lateral incisor with an additional (supernumerary) tooth [Figure 1]. Dental caries was evident on the incisal edge and proximal surface of supernumerary tooth. The child's dentition revealed Angle's class 1 molar relation on both right and left side. Maxillary right permanent central incisor was erupted, but it was in cross-bite relationship. A mid line diastema was also noted in maxilla. Clinical examination revealed missing right permanent lateral incisor and there was no history of previous extraction, of this tooth. Further investigation included intraoral periapical radiograph of maxillary anterior region [Figure 2]. Based on clinical and radiographical findings, the provisional diagnosis of fused triple teeth was made.

The treatment plan was aimed at removal of fused teeth. Under sedation, fused teeth were carefully extracted [Figure 3]. Macroscopically, root resorption was evident on apical portion

of maxillary right primary lateral incisor. For histological examination, the extracted teeth were sectioned at three levels: The coronal, middle root and apical levels, respectively. These sections were visualized under a stereomicroscope at a magnification of $\times 50$. Histological view of the coronal section revealed three teeth fused with each other with confluent dentin without intervening cementum and with separate pulp

chambers [Figure 4]. The middle-third of the roots of three fused teeth also showed confluent dentin without intervening cementum [Figure 5]. The apical third of fused teeth showed merging of root canals of the fused teeth [Figure 6]. Based on these findings, a final diagnosis of incomplete fusion was confirmed.

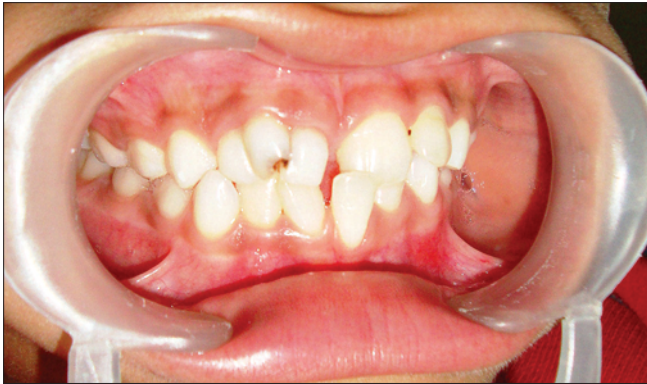

Figure 1: Pre-operative intraoral photograph

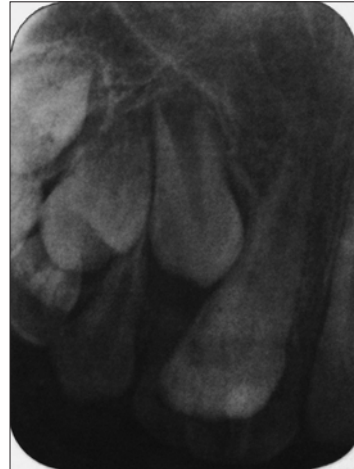

Figure 2: Pre-operative intraoral maxillary occlusal view depicting triple fusion

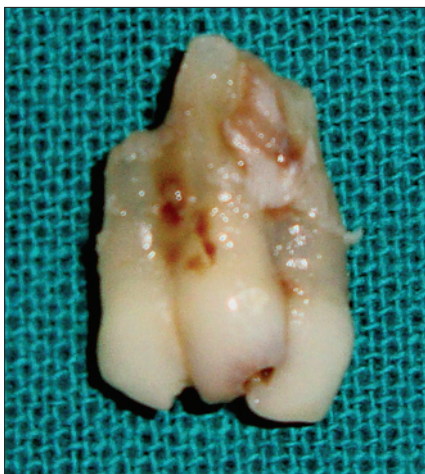

Figure 3: Extracted fused teeth

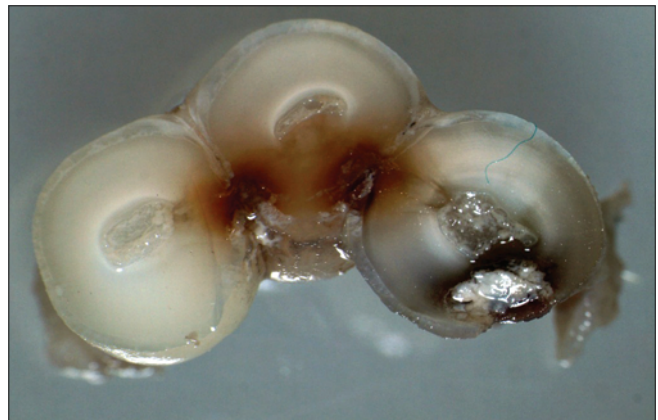


Figure 4: Coronal section of fused teeth showing confluent dentin without intervening Cementum and with separate pulp chambers

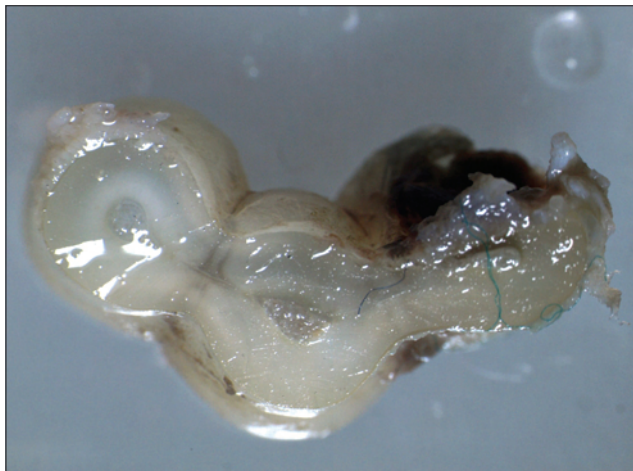


Figure 5: Middle-third of the roots of three fused teeth also showed confluent dentin without intervening cementum

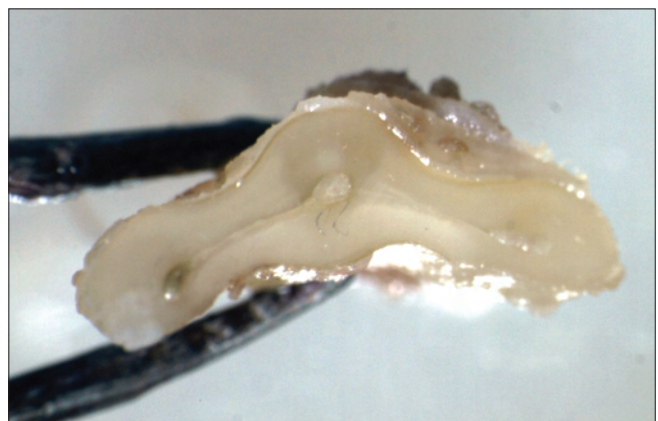


Figure 6: The apical third showing merging of root canals of the fused teeth

Further treatment plan involved thorough oral prophylaxis and correction of anterior cross-bite. After oral prophylaxis and pit and fissure sealant application, a removable Hawley's appliance with Z-spring was fabricated for the correction of the anterior tooth cross-bite, but as patient was mentally challenged, cooperation from him was poor as the child was not ready to wear the appliance. Again Catalan's appliance was made and cemented on the lower incisors, but the attempt for the correction of cross-bite failed because of insufficient compliance of the patient as he was not occluding his teeth.

DISCUSSION

Triple fusion is rarely encountered dental anomaly and is thought to be caused by pressure or force during development of adjacent roots. If the fusion begins before calcification, then the union will involve all components of the tooth, including enamel, dentin, cementum and pulp. If the union begins at later stage of tooth development, then the affected teeth may have separate crowns and fusion may be limited to the roots. The pulp canal may be either fused or separate. It can occur between normal teeth or between normal and supernumerary teeth.^[5]

In the present case, fusion was seen between maxillary right primary incisors and supernumerary teeth and teeth were incompletely fused involving dentin in coronal, middle and apical portion of the teeth with separate pulp canals.

The anomalies of the permanent dentition are strongly associated with anomalies in the primary dentition.^[6] The most common problem related to fused teeth is hypodontia of the permanent dentition.^[7] In the present case, the maxillary permanent lateral incisor on the affected side was missing. Fused teeth can also cause delayed resorption of roots, which may lead to delayed or ectopic eruption of permanent successor. In the present case, fused teeth showed minimal resorption of primary lateral incisor at the apical portion of the root. Maxillary right permanent central incisor was palatally erupted and was in cross-bite relationship.

The treatment of fused teeth depends upon the clinical situation. Esthetics of the child is usually the determining factor regarding the decision to retain or extract these teeth depending on the dentition stage either it is deciduous/mixed or permanent

dentition stage. In the present case, we decided to extract the fused teeth under conscious sedation since the permanent central incisor of that side was already erupted. As in this case, the child is mentally challenged fixed orthodontic treatment can be anticipated for the desirable occlusion relationship.

Importance of anomalies in the primary dentition is usually underestimated specially when they are asymptomatic. However, their presence may have marked effect on the permanent dentition as they can indicate future dental anomalies especially hypodontia in the permanent dentition. Thus, a radiographic examination should be performed in every case. Therefore, treatment of fused teeth is necessary by taking the phase of dentition period under consideration to intercept the ill-effects and improve the dental health of the child.

ACKNOWLEDGMENT

The authors would like to express gratitude to their colleagues in India, especially Dr. Prince Kumar, for help regarding preparation and editing of the manuscript.

REFERENCES

1. Mohapatra A, Prabhakar AR, Raju OS. An unusual triplication of primary teeth-A rare case report. *Quintessence Int* 2010;41:815-20.
2. Erdem GB, Uzamiş M, Olmez S, Sargon MF. Primary incisor triplication defect. *ASDC J Dent Child* 2001;68:322-5, 301.
3. Aguilo L, Catala M, Peydro A. Primary triple teeth: Histological and CT morphological study of two case reports. *J Clin Pediatr Dent* 2001;26:87-92.
4. Shah A, Gill DS, Tredwin C, Naini FB. Diagnosis and management of supernumerary teeth. *Dent Update* 2008;35:510-2, 514.
5. Scheid RC, Woelfel JB. *Woelfel's Dental Anatomy-Its Relevance to Dentistry*, 7thed. Philadelphia: Lippincott Williams and Wilkins; 2007. p. 403-31.
6. Nik-Hussein NN, Abdul Majid Z. Dental anomalies in the primary dentition: Distribution and correlation with the permanent dentition. *J Clin Pediatr Dent* 1996;21:15-9.
7. Gellin ME. The distribution of anomalies of primary anterior teeth and their effect on the permanent successors. *Dent Clin North Am* 1984;28:69-80.

How to cite this article: Yadav S, Tyagi S, Kumar P, Sharma D. Triplication of deciduous teeth: A rare dental anomaly. *Niger J Surg* 2013;19:85-7.

Source of Support: Nil. **Conflict of Interest:** None declared.