

Primary Peritoneal Hydatidosis in a 76-Year-Old Farmer: An Unusual form of a Common Disease

Mayank Baid, Manoranjan Kar, Santu Chejara¹, Mrityunjay Mukhopadhyay

Department of Surgery, Medical College, ¹Department of Surgery, Calcutta National Medical College, Kolkata, India

ABSTRACT

A 76-year-old farmer presented at our emergency unit with a history of gradual swelling of abdomen without fever, nausea, or urticaria. On examination there was symmetrical enlargement of abdomen with fluid thrill. Contrast-enhanced computed tomography scan showed that the entire peritoneal cavity was distended and occupied by multiloculated noncalcified content of mixed attenuations. Diagnosis of peritoneal seeding of hydatid cyst was made. At laparotomy, about 25 l of daughter cysts and a membrane was found in the peritoneal cavity without other organ involvement. Postoperative period was uneventful.

KEYWORDS: Echinococcosis, hydatid cyst, primary peritoneal hydatidosis

Address for correspondence:

Dr. Mayank Baid,
Department of Surgery, Medical College,
88 College Street, Kolkata, India.
E-mail: drmayankbaid@gmail.com

Access this article online

Quick Response Code:



Website: www.nigerianjsurg.com

DOI:
10.4103/1117-6806.103119

INTRODUCTION

Hydatid disease (HD) is caused by the larval stage of *Echinococcus*. Liver and lungs are most commonly affected organs. In most cases peritoneal involvement is related to contamination from previous surgery for hepatic hydatid cyst and in some, to traumatic rupture of hepatic or splenic hydatid cyst. Primary peritoneal involvement, without involvement of any other organ is extremely rare, reported in only 2% of all abdominal HD.^[1] A case of primary peritoneal hydatidosis is being reported here.

CASE REPORT

A 76-year-old farmer presented in the emergency unit of Medical College, Kolkata with hugely distended abdomen. He had history of gradual swelling of his abdomen with mild pain for 1 year. There was no history of fever, nausea or vomiting, loss of appetite, acute episodes of abdominal pain, and no previous abdominal operation. Bladder and bowel habits were normal. Patient lives in a remote village having frequent exposure to dogs and their faeces through vegetables and direct contact.

On examination, patient had mild pallor, moderate pedal edema, a pulse rate of 76/min, blood pressure of 140/80 mm of Hg, respiratory rate of 18/min, and normal body temperature. Abdomen was symmetrically distended [Figure 1a], with flushed

umbilicus. On palpation, no organomegaly was noted. Ascites was demonstrable by fluid thrill. On percussion, note was dull and shifting dullness could not be elicited. Other systems were normal. Clinical diagnosis of malignant ascites was made and further investigations were planned.

Investigations revealed a hemoglobin level of 8.5 gm/dl, total count of white blood cell 6500/cc, and eosinophil count of 8%. Ultrasonography showed ascites, no organomegaly and no lymphadenopathy. Adenosine diaminase level in ascitic fluid was normal and no malignant cell was found. Blood test for echinococcal antigen was also normal. Contrast-enhanced computed tomography (CECT) scan of abdomen [Figure 1b] showed the entire peritoneal cavity distended and occupied by multiloculated noncalcified content of mixed attenuations. There was no lesion in any organ except that small bowel loops were clustered together in the midline posteriorly. Differential diagnosis of pseudomyxoma peritonei or peritoneal seeding of hydatid disease was made. Enzyme-linked immune sorbent assay (ELISA) test for hydatid disease was negative.

The patient was transferred to the Surgery department. At exploratory laparotomy, peritoneal cavity was found filled with multiple daughter cysts and a membrane [Figure 1c]. About 25l of cysts and fluids were removed [Figure 1d]. Liver, spleen, mesentery, and gut loops were not involved. Postoperative period was uneventful. Histopathological examination confirmed the cysts being hydatid cyst. Patient was put on albendazole 400 mg twice daily for 4 weeks. Three cycles of albendazole was repeated with three weeks drug-free interval.

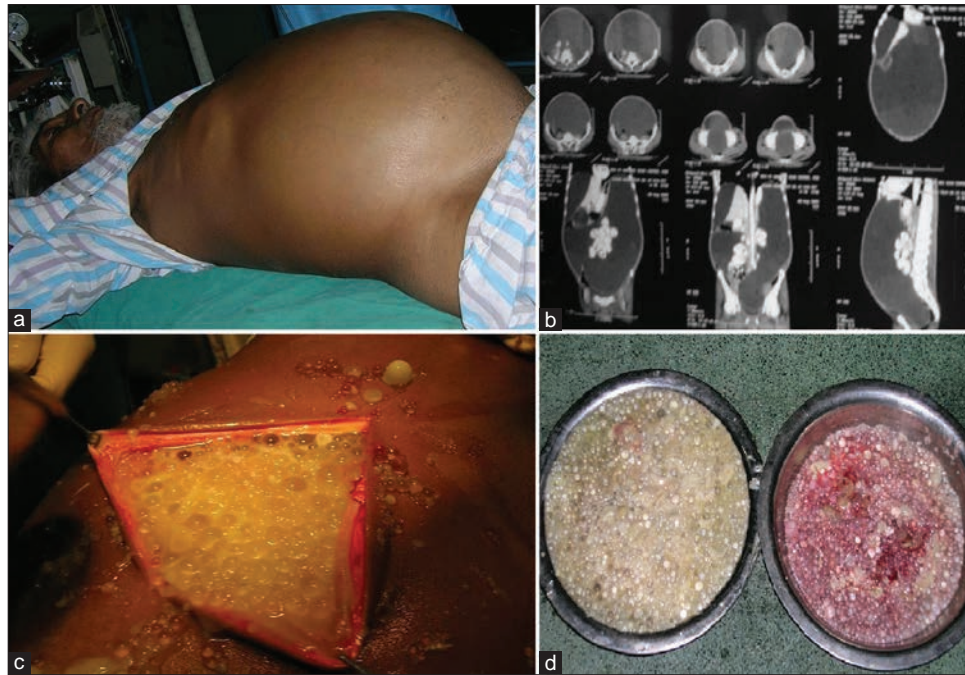


Figure 1: (a) Preoperative photograph of patient with symmetric enlargement of the abdomen, (b) Contrast-enhanced computed tomography (CECT) scan showing whole abdominal cavity occupied with multiloculated noncalcified content of mixed attenuation and small gut pushed posteriorly, (c) Intraoperative photograph showing abdomen filled with daughter cyst and membrane, (d) Part of the removed content of abdominal cavity

When reviewed 12 months after surgery, patient remained asymptomatic and ultrasonography was also unremarkable.

DISCUSSION

Hydatid cyst is a parasitic infection caused by the cestode *Echinococcus*. Dogs are definitive host and humans the accidental intermediate host get infected by contact with infested dogs or by consuming vegetables and/or water contaminated with hydatid ova.

Liver (75% of cases) and lungs (15% of cases) are the commonly involved organs. The frequency of peritoneal involvement is approximately 13%,^[2] more commonly related to secondary involvement from other organs.

Primary peritoneal hydatidosis has been reported in only 2% of all abdominal HD.^[1] The mechanism of primary peritoneal involvement is not clear, the dissemination may take via lymphatic or systemic circulation^[3] which might be the mode of spread in this case as well. In most cases, peritoneal hydatid cyst does not produce any symptoms and diagnosis is made when patient undergoes ultrasonography for an unrelated cause.

Diagnosis of HD is radiologically aided by serological testing. Ultrasonography, contrast-enhanced computed tomography (CECT) scan, and enzyme-linked immune sorbent assay (ELISA) are used.

Surgery is the mainstay of treatment. Laparotomy is the most common surgical approach.^[4] In cases suspected of having peritoneal spillage, antihelminthic drugs should be administered.

Through this case report we wish to emphasize the fact that, while dealing with patients at emergency presenting with huge abdominal distension and features suggestive of ascites even without any history of urticaria one must keep the diagnosis of hydatid disease in mind, particularly in people from countries where hydatid disease is endemic.

REFERENCES

1. Balik AA, Celebi F, Basoglu M, Oren D, Yildirgan I, Atamanalp SS. Intra abdominal extrahepatic echinococcosis. *Surg Today* 2001;31:881-4.
2. Karavias DD, Vagianos CE, Kakkos SK, Panagopoulos CM. Peritoneal echinococcosis. *World J Surg* 1996;20:337-40.
3. Astarcioglu H, Koidor MA, Toplak O, Terzi C, Sokmen S, Ozer E. Isolated mesosigmoid hydatid cyst as an unusual cause of colonic obstruction: Report of a case. *Surg Today* 2001;31:920-2.
4. Buttenschoen K, Carli Buttenschoen D. Echinococcus granulosus infection: The challenge of surgical treatment. *Langenbecks Arch Surg* 2003;4:218-30.

How to cite this article: Baid M, Kar M, Chejara S, Mukhopadhyay M. Primary peritoneal hydatidosis in a 76-year-old farmer: An unusual form of a common disease. *Niger J Surg* 2012;18:100-1.

Source of Support: Nil. **Conflict of Interest:** None declared.