

# Migratory Surgical Gossypiboma—Cause of Iatrogenic Perforation: Case Report with Review of Literature

**Mohinder Kumar Malhotra**

*Department of General Surgery, SGT Medical College, Hospital and Research Institute, Gurgaon, India*

## ABSTRACT

Forgotten foreign bodies, such as cotton sponges, gauze, or instruments, after any surgical procedure is considered a misadventure but avoidable complication. “Gossypiboma” denotes a mass of cotton that is accidentally retained in the body postoperatively. This study’s goal was to systematically review the literature on retained sponges to identify incidence, site of occurrence, time of discovery, methods for detection, pathogenesis for intraluminal migration and risk factors. Author is reporting this case in which a 45-year old woman presented with features of chronic pain abdomen following abdominal hysterectomy (first surgery) which lead to open cholecystectomy (second surgery) after two and half year of first surgery. As patients continued to have persistent abdominal pain in spite of second surgery patient went to medical gastroenterologist who advised her series of tests including colonoscopy examination. The whole colon was normal on examination but on examination of terminal portion of small bowel some intraluminal mass was visualized. Attempt to retrieve this mass lead to iatrogenic ileal perforation.

**KEYWORDS:** Gossypiboma, iatrogenic, ileal perforation, intraluminal migration

## INTRODUCTION

Gossypiboma is a serious iatrogenic but avoidable complication and it usually goes unreported because of its medico legal implications. Author has operated upon two such cases of migratory surgical gossypiboma in last 10 years but is only reporting the second such case. This case is being reported to highlight the need of keeping possibility of gossypiboma in case of unresolved postsurgical pain abdomen and need for proper counting of mops and pads after prolonged and difficult surgeries. These types of complications occur much more commonly in third world and developing countries where surgeries especially abdominal hysterectomies are carried out in less desirable and compromising conditions and fear of medico legal implications are much lesser.

## CASE REPORT

This 45-year-old patient was referred by gastroenterologist as surgical emergency with signs of perforative peritonitis following

### Address for correspondence:

Dr. Mohinder Kumar Malhotra  
Department of General Surgery, SGT Medical College, Hospital and Research Institute, Gurgaon, India.  
E-mail: malhotramsfrs@yahoo.co.in

### Access this article online

#### Quick Response Code:



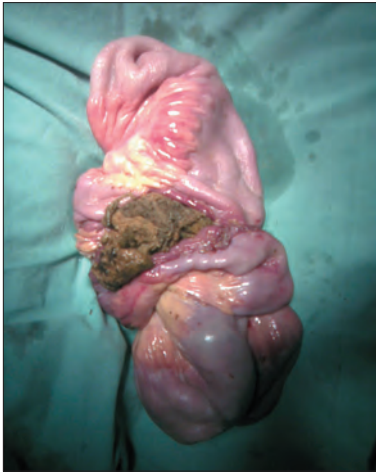Website: [www.nigerianjsurg.com](http://www.nigerianjsurg.com)

DOI:  
10.4103/1117-6806.95486

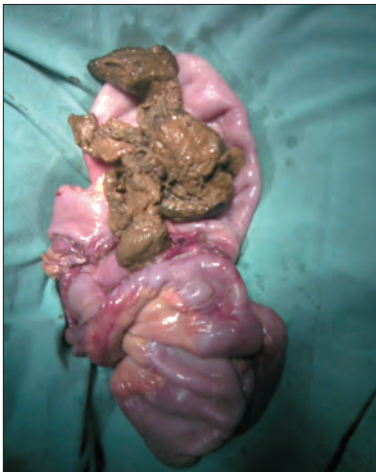
attempted colonoscopic retrieval of intra luminal ileal mass. The plain X-ray chest with both domes of diaphragm showed gas under right dome of diaphragm. Patient was resuscitated and taken up for emergency laparotomy. Preoperative abdominal examination showed two healed scar marks on in right sub costal region (open cholecystectomy scar) and lower abdomen pfannelstiel incision (Abdominal hysterectomy scar). On exploration about 500 ml of bile stained fluid was found and small bowel perforation was noticed about 20 cm from ileocecal junction. A large thick wall ileal loop with some unusual intra luminal mass was felt. Ileal mass was resected along with perforated site with end-to-end ileal–ileal anastomosis. Patient had postoperative wound infection which responded to the antibiotic and other supportive measures. On incision of resected ileal loop [Figures 1 and 2] abdominal sponge was retrieved [Figure 3].

## DISCUSSION

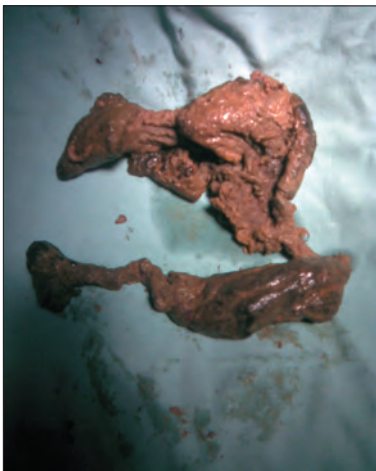One hundred seventy eight (178) reports from the period (1978–2011) were identified via the National Library of Medicine’s Medline. Review of literature and Medline search revealed 45 reported cases of trans mural migration of surgical sponges following abdominal surgery during period of 2000–2010.<sup>[1]</sup> Incidence of Retained surgical sponge or gossypiboma occurs at a one per 100–3000 operations;<sup>[2]</sup> however, surgeons may not report these events for fear of litigation and adverse publicity therefore true incidence will never be known. gossypiboma (mean patient age 49 years,



**Figure 1:** Abdominal sponge protruding out from incised ileal specimen



**Figure 2:** Resected ileal specimen with abdominal sponge



**Figure 3:** Abdominal sponge removed from resected ileum

range 6–92 years) were most commonly found in the abdomen (56%), pelvis (18%), and thorax (11%). Average discovery time equaled 6.9 years (SD 10.2 years) with a median (quartiles) of 2.2 years (0.3–8.4 years). The most common detection methods

were computed tomography (61%), radiography (35%), and ultrasound (34%). Pain/irritation (42%), palpable mass (27%), and fever (12%) were the leading signs and symptoms, but 6% of cases were asymptomatic. Complications included adhesion (31%), abscess (24%), and fistula (20%). Risk factors were case specific (e.g., emergency) or related to the surgical environment (e.g., poor communication) but most retained sponges, in fact, occur after “normal” swab counts, perhaps falling outside the human safeguards designed to prevent these types of errors.<sup>[3]</sup> The present case report and review of literature suggests that possibility of a retained foreign body should be in the differential diagnosis of any postoperative patient who presents with pain, infection, or palpable mass. Had this possibility was kept in mind the cholecystectomy (second surgery) might have been avoided in instant case. In the study conducted by Bani-Hani *et al.*, ten out of eleven (91%) patients required reoperation to remove the retained sponge and to manage the resulted complications, including bowel obstruction and fistulae.<sup>[4]</sup> If diagnosis is made early, laparoscopic retrieval may be feasible<sup>[5]</sup> and patient would have been saved of agony of undergoing two major surgical operations and its risk of associated morbidity and mortality. Pathologically, a retained sponge may lead to foreign body reactions of two types: Formation of foreign body granuloma due to aseptic fibrinous response, or exudative reaction leading to abscess formation,<sup>[6]</sup> Migration of retained sponge into bowel is rare compared to abscess formation and occurs as a result of inflammation in the intestinal wall that evolves to necrosis.<sup>[7]</sup> The intestinal loop closes after complete migration of sponge.<sup>[3,5]</sup> Peristaltic activity advanced the mop usually to stay in the terminal ileum, resulting in obstruction.<sup>[7,8]</sup> The universal guidelines should be strictly followed as stated by the American College of Surgeons in October 2005; only radio opaque sponges should be used, accurate sponge counts should be performed before the procedure, and before and after closure of the abdomen. Also, a meticulous examination of the abdomen should be done before closure.<sup>[6,9]</sup> An electronic article surveillance system which uses a tagged surgical sponge that can be identified electronically has been examined.<sup>[10]</sup> Bar codes can be applied to all sponges, and with the use of a bar code scanner the sponges can be counted on the back table.<sup>[11]</sup> The small sponges should not be used during laparotomy and compresses should only be used intraperitoneally, one at a time, mounted on forceps.<sup>[12]</sup> The most importantly is “Prevention of three “never events” in the operating room: Fires, gossypiboma, and wrong-site surgery”<sup>[13]</sup> Irrespective of the rarity of reports, operating teams should take care to count swabs used in all procedures. Surgeons should develop a habit of performing a brief but thorough routine postoperative wound and cavity exploration prior to wound closure.<sup>[14]</sup>

## REFERENCES

1. Akbulut S, Arikanoğlu Z, Yagmur Y, Basbug M. Gossypibomas mimicking a splenic hydatid cyst and ilealtumor: A case report and literature review. *J Gastrointest Surg* 2011;15:2101-7.
2. Patil KK, Patil SK, Gorad KP, Panchal AH, Arora SS, Gautam RP.

- Intraluminal migration of surgical sponge: Gossypiboma. Saudi J Gastroenterol 2010;16:221-2.
3. Dux M, Ganten M, Lubienski A, Grenacher L. Retained surgical sponge with migration into the duodenum and persistent duodenal fistula. Eur Radiol 2002;12(Suppl 3):S74-7.
  4. Bani-Hani KE, Gharaibeh KA, Yaghan RJ. Retained surgical sponges (gossypiboma). Asian J Surg 2005;28:109-15.
  5. Uranüs S, Schauer C, Pfeifer J, Dagcioglu A. Laparoscopic removal of a large laparotomy pad forgotten *in situ*. Surg Laparosc Endosc 1995;5:77-9.
  6. Choi BI, Kim SH, Yu ES, Chung HS, Han MC, Kim CW. Retained surgical sponge: Diagnosis with CT and sonography. AJR Am J Raentgenol 1988;150:1047-50.
  7. Silva CS, Caetano MR, Silva EA, Falco L, Murta EF. Complete migration of retained surgical sponge into ileum without sign of open intestinal wall. Arch Gynaecol Ostet 2001;265:103-4.
  8. Menteş BB, Yilmaz E, Sen M, Kayhan B, Gorgul A, Tatlicioglu E. Transgastric migration of surgical sponge. J Clin Gastroentrol 1997;24:55-7.
  9. American College of Surgeons. Statement on the prevention of retained foreign bodies after surgery. Bull Am Coll Surg 2005;90:15-6.
  10. Fabian CE. Electronic tagging of surgical sponges to prevent their accidental retention. Surgery 2005;137:298-301.
  11. Gibbs VC, Coakley FD, Reines HD. Preventable errors in the operating room: Retained foreign bodies after surgery-Part I. Curr Probl Surg 2007;44:261-337.
  12. Akbulut S, Sevinc MM, Basak F, Aksoy S, Cakabay B. Transmural migration of a surgical compress into the stomach after splenectomy: A case report. Cases J 2009;2:7975.
  13. Zahiri HR, Stromberg J, Skupsky H, Knepp EK, Folstein M, Silverman R, *et al*. Prevention of 3 "never events" in the operating room: Fires, gossypiboma, and wrong-site surgery. Surg Innov 2011;18:55-60.
  14. Asuquo ME, Ogbu N, Udosen J, Ekpo R, Agbor C, Ozinko M, *et al*. Acute abdomen from gossypiboma: A case series and review of literature. Niger J Surg Res 2006;8:174-6.

**How to cite this article:** Malhotra MK. Migratory surgical Gossypiboma-Cause of iatrogenic perforation: Case report with review of literature. Niger J Surg 2012;18:27-9.

**Source of Support:** Nil. **Conflict of Interest:** None declared.

#### Announcement

#### iPhone App



Download  
iPhone, iPad  
application

FREE

A free application to browse and search the journal's content is now available for iPhone/iPad. The application provides "Table of Contents" of the latest issues, which are stored on the device for future offline browsing. Internet connection is required to access the back issues and search facility. The application is Compatible with iPhone, iPod touch, and iPad and Requires iOS 3.1 or later. The application can be downloaded from <http://itunes.apple.com/us/app/medknow-journals/id458064375?ls=1&mt=8>. For suggestions and comments do write back to us.