

# Secondary Signet Ring Cell Carcinoma of Prostate

Kalyan Khan, Arghya Bandyopadhyay, Mimi Gangopadhyay, Subrata Chakraborty, Pranati Bera

Department of Pathology, North Bengal Medical College, Sushruta Nagar, Darjeeling, India

## ABSTRACT

True metastases to prostate from solid tumors are reported only in 0.2% of all surgical prostatic specimens and 2.9% of all male postmortems. Clinical context, morphological features, and immunohistochemical localization of prostate specific antigen (PSA) are supposed to clarify the differential diagnosis between a secondary and a primary tumor. We report an unusual and rare case of secondary signet ring cell carcinoma (SRCC) of prostate in which the clinical data and signet ring cell morphology pointed toward the diagnosis of a primary SRCC. Immunohistochemistry (IHC) for PSA not only proved the case to be a secondary SRCC but also initiated the process for diagnosis of the occult primary malignancy in the patient's stomach.

**KEYWORDS:** Prostate specific antigen, prostate, signet ring cell carcinoma

## INTRODUCTION

Metastases to the prostate are rare occurring mostly in cases of widespread metastatic disease.<sup>[1]</sup> True metastases from solid tumors in lung, skin (melanoma), gastrointestinal tract, kidney, testes, and endocrine glands are reported only in 0.2% of all surgical prostatic specimens and 2.9% of all male postmortems.<sup>[2]</sup> Lung is the most common primary site of metastases to the prostate.<sup>[2]</sup> In all series direct spread of bladder carcinoma is the most common secondary prostatic tumor.<sup>[2,3]</sup> Clinical context, morphological features, and immunohistochemical localization of prostate specific antigen (PSA) are supposed to clarify the differential diagnosis between a secondary and a primary tumor.<sup>[4]</sup> We report an unusual and rare case of secondary signet ring cell carcinoma (SRCC) of prostate in which the clinical data pointed toward the diagnosis of a primary SRCC. Signet ring cell morphology was also not helpful as incidence of primary SRCC was more than that of secondary SRCC in prostate. Immunohistochemistry (IHC) for PSA not only proved the case to be a secondary SRCC but also initiated the process for diagnosis of the occult primary malignancy in the patient's stomach.

## CASE REPORT

A 74-year-old male patient presented with frequency of micturition, dysuria, and features of urinary outlet obstruction developing progressively over a period of last 3 months. He was a smoker, occasional drinker, and complained of no

### Address for correspondence:

Dr. Kalyan Khan,  
Flat No. 11, Bela Apartment, Netaji Subhas Road, Subhaspally, Siliguri,  
Darjeeling - 734 001, India.  
E-mail: kkhan2001@gmail.com

### Access this article online

#### Quick Response Code:

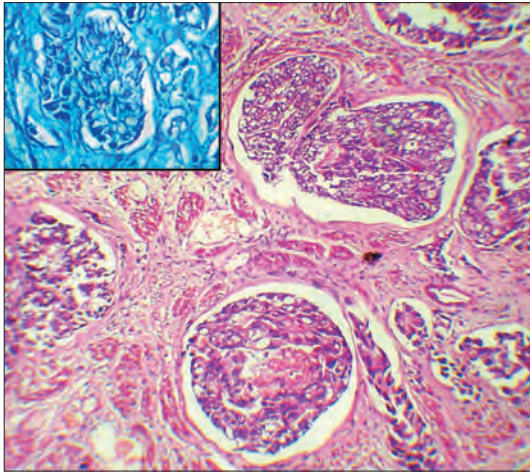


Website: [www.nigerianjsurg.com](http://www.nigerianjsurg.com)

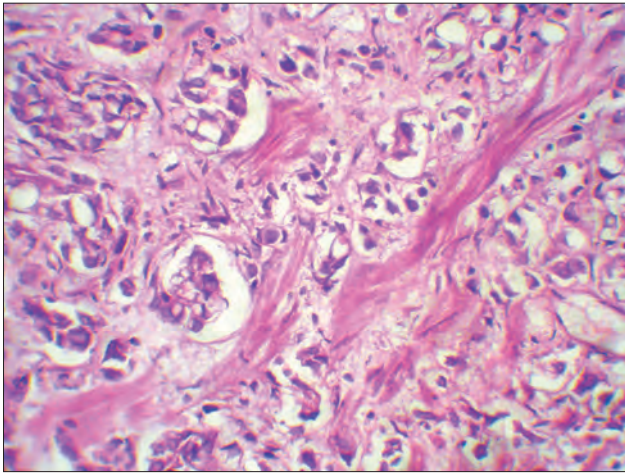
DOI:  
10.4103/1117-6806.95484

other features of clinical interest except infrequent dyspepsia. Transrectal ultrasonography showed Grade III prostatomegaly measuring 5.5x4.2x4.8cm (58g), with suspicious hypoechoic areas in the peripheral zone and residual urine of 80 ml. Serum total PSA level was 9.71 ng/ml and free-to-total PSA ratio was 10.8. On digital rectal examination the prostate was elastic, slightly hard, painless, and with prominent retroprostatic sulci. Blood examination showed microcytic hypochromic anemia and an elevated erythrocyte sedimentation rate. Chest X-ray revealed no abnormalities.

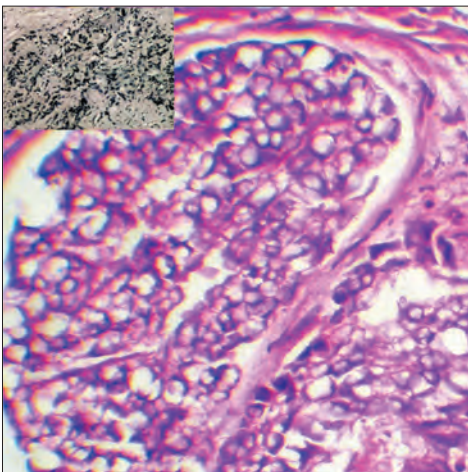
Cystoscopic examination found no primary abnormality of the bladder and extensive transurethral resection of prostate (TURP) was performed under anesthesia with resultant specimen measuring 45 g. Histopathology revealed nests and singly infiltrating poorly differentiated, hyperchromatic, pleomorphic adenocarcinoma cells majority of which were of signet ring morphology [Figures 1-3]. Individual cells and cell nests were seen lying haphazardly among bundles of smooth muscle fibers and also within lymphovascular spaces but no perineural invasion, mucinous fibroplasia or glomerulations were noted. Initial diagnosis of signet ring variant of invasive prostatic adenocarcinoma with Gleason score 4+5=9 was thought of but IHC for PSA [Figure 3 (inset)] and Carcinoembryonic Antigen (CEA) were simultaneously performed as primary prostatic signet ring cell adenocarcinoma is rare and it is mandatory to exclude other mucinous tumors of non-prostatic origin based on morphology and immunohistochemistry and if necessary using clinical information.<sup>[4]</sup> Both the immunostains showed negative results. The globoid optically clear cytoplasm of the signet ring cells were stained positively with Alcian blue at pH



**Figure 1:** Nests of malignant signet ring shaped adenocarcinoma cells in prostate. H and E;  $\times 100$ . (Inset: same signet ring cells with positive Alcian blue stain at pH 2.5.)



**Figure 2:** Signet ring cells lying haphazardly among bundles of smooth muscle fibers. H and E;  $\times 400$



**Figure 3:** Islands of signet ring cells. H and E;  $\times 400$ . (Inset: Tumour cells negative for PSA immunostain  $\times 100$ .)

2.5 confirming the contents as acid mucin [Figure 1 (inset)]. Gastric endoscopic biopsy was subsequently performed 2 weeks after TURP and histopathology showed infiltrating signet ring cell carcinoma of stomach. Computerized tomography showed no hepatic metastases and only enlarged regional lymph nodes. Radical gastrectomy was done and follow-up chemotherapy was instituted. The patient is doing well after 6 months of the initial prostatectomy.

## DISCUSSION

Some primary adenocarcinomas of the prostate will have a signet-ring-cell appearance, yet the vacuoles do not contain intracytoplasmic mucin.<sup>[5]</sup> These vacuolated cells may be present as singly invasive cells, in single glands, and in sheets. Only a few cases of prostate cancer have been reported with mucin positive signet ring cells.<sup>[6,7]</sup> One should exclude other mucinous tumors of nonprostatic origin based on morphology and immunohistochemistry and if necessary using clinical information.<sup>[4]</sup>

Immunohistochemical stain for PSA is diagnostically helpful in distinguishing prostatic adenocarcinomas from other neoplasms secondarily involving the prostate and establishing prostatic origin in metastatic carcinomas of unknown primary.<sup>[8,9]</sup> A minority of higher grade prostatic adenocarcinomas are PSA negative, although some of these tumors have been shown to express PSA mRNA. Some prostatic adenocarcinomas lose PSA immunoreactivity following androgen deprivation or radiation therapy.<sup>[4]</sup>

In gastric signet ring cell carcinoma (WHO classification)<sup>[10]</sup> more than 50% of the tumor consists of isolated or small groups of malignant cells containing intracytoplasmic acid mucin that stain with Alcian blue at pH 2.5.

The present case once again underlines the fact that metastatic SRC carcinoma although rare should be considered as a differential before diagnosing a primary SRC carcinoma of prostate. A detailed clinical examination and special attention to any prior history of mild symptoms like dyspepsia might lead to the performance of an upper gastrointestinal endoscopy which can help in much earlier detection of a primary gastric tumor. The most important feature for differentiation in this case with an occult primary was PSA immunostain supplemented by an Alcian blue stain at pH 2.5.

## ACKNOWLEDGMENT

Dr. Tapas Moitra, Associate Professor, Department of Urology, North Bengal Medical College, Sushrutanagar, Darjeeling.

## REFERENCES

1. Kendall A, Corbishley CM, Pandha HS. Signet ring cell carcinoma in the prostate. *Clin Oncol (R Coll Radiol)* 2004;16:105-7.
2. Bates AW, Baithun SI. Secondary solid neoplasms of the prostate: A clinicopathological series of 51 cases. *Virchows Arch* 2002;440:392-6.
3. Young RH, Srigley JR, Amin MB, Ulbright TM, Cubilla AL. Tumors of the Prostate Gland, Seminal Vesicles, Male Urethra and Penis (fascicle 28). 3<sup>rd</sup> ed. Washington, DC: AFIP; 2000.
4. Eble JN, Sauter G, Epstein JI, Sesterhenn IA. World Health Organization Classification of Tumours. Pathology and Genetics of Tumours of the Urinary System and Male Genital Organs. Lyon: IARC Press; 2004. p. 212-3.
5. Ro JY, el-Naggar A, Ayala AG, Mody DR, Ordonez NG. Signet-ring-cell carcinoma of the prostate. Electron-microscopic and immunohistochemical studies of eight cases. *Am J Surg Pathol* 1988;12:453-60.
6. Hejka AG, England DM. Signet ring cell carcinoma of prostate. Immunohistochemical and ultrastructural study of a case. *Urology* 1989;34:155-8.
7. Uchijima Y, Ito H, Takahashi M, Yamashina M. Prostate mucinous adenocarcinoma with signet ring cell. *Urology* 1990;36:267-8.
8. Epstein JI. PSA and PAP as immunohistochemical markers in prostate cancer. *Urol Clin North Am* 1999;20:757-70.
9. Nadji M, Tabei SZ, Castro A, Chu TM, Murphy GP, Wang MC, *et al.* Prostatic-specific antigen: An immunohistologic marker for prostatic neoplasms. *Cancer* 1981;48:1229-32.
10. Hamilton SR, Aaltonen LA. World Health Organization Classification of Tumours. Pathology and Genetics of Tumours of the Digestive System. Lyon: IARC Press; 2004. p. 35-65.

**How to cite this article:** Khan K, Bandyopadhyay A, Gangopadhyay M, Chakraborty S, Bera P. Secondary signet ring cell carcinoma of prostate. *Niger J Surg* 2012;18:24-6.

**Source of Support:** Nil. **Conflict of Interest:** None declared.

### New features on the journal's website

#### Optimized content for mobile and hand-held devices

HTML pages have been optimized for mobile and other hand-held devices (such as iPad, Kindle, iPod) for faster browsing speed.

Click on **[Mobile Full text]** from Table of Contents page.

This is simple HTML version for faster download on mobiles (if viewed on desktop, it will be automatically redirected to full HTML version)

#### E-Pub for hand-held devices

EPUB is an open e-book standard recommended by The International Digital Publishing Forum which is designed for reflowable content i.e. the text display can be optimized for a particular display device.

Click on **[EPub]** from Table of Contents page.

There are various e-Pub readers such as for Windows: Digital Editions, OS X: Calibre/Bookworm, iPhone/iPod Touch/iPad: Stanza, and Linux: Calibre/Bookworm.

#### E-Book for desktop

One can also see the entire issue as printed here in a 'flip book' version on desktops.

Links are available from Current Issue as well as Archives pages.

Click on  View as eBook