

# Primary Hydatid Cyst in Gastrocnemius Muscle

Saswata Bharati, Mrityunjay Pal

Departments of Anaesthesiology and Surgery, Midnapore Medical College, West Bengal, India

## ABSTRACT

Cystic echinococcosis, which is caused by the larval stages of *Echinococcus granulosus*, results from the presence of one or more massive cysts or hydatids, and can involve any organ, including the liver, lungs, heart, brain, kidneys, and long bones. Muscle hydatidosis is usually secondary in nature, resulting from spread of larval tissue from a primary site after spontaneous or trauma-induced cyst rupture or after release of viable parasite material during invasive treatment procedures. Primary muscle hydatidosis is extremely uncommon, because implantation at this site would require passage through the filters of the liver and lung. Intramuscular hydatid cyst can cause a variety of diagnostic problems, especially in the absence of typical radiologic findings. We present an unusual case of a primary hydatid cyst found in the popliteal fossa of the right knee of a 52-year-old woman, presenting as an enlarging soft-tissue tumor for 6 months associated with pain. The mass initially was diagnosed to be Backer's cyst by ultrasonography, but later it was confirmed postoperatively through histopathological studies to be due to hydatid disease. In regions where hydatidosis is endemic, hydatid cyst should be included in the differential diagnosis of any unusual muscular mass.

**KEYWORDS:** *Echinococcus*, muscle hydatidosis, popliteal fossa, primary hydatid cyst, scolical agent

## INTRODUCTION

Hydatid disease, which is a zoonotic infection caused by larval forms (metacestodes) of tapeworms of the genus *Echinococcus* found in the small intestine of carnivores, still remains an important health problem in endemic regions.<sup>[1,2]</sup> Two of the four recognized species of *Echinococcus*: *E. granulosus* and *E. multilocularis*, cause cystic echinococcosis (CE) and alveolar echinococcosis (AE) in humans, respectively. The eggs of these tapeworms excreted by carnivores may infect humans as natural intermediate host.<sup>[2]</sup> The disease results from the development of the larval or hydatid form in the body. Hydatid cysts, which generally involve the liver and the lungs, are uncommonly found in muscles; even in endemic zones.<sup>[2]</sup> Exclusive involvement of the muscles is extremely uncommon, because implantation at this site would require passage through the filters of the liver and lung. We describe a patient with a mass in the popliteal fossa of the knee for 6 months who was seen for pain and was found to have hydatid disease.

## Address for correspondence:

Dr. Mrityunjay Pal,  
Department of Surgery, Midnapore Medical College, West Bengal, India.  
E-mail: drmrityunjaypal@gmail.com

## Access this article online

### Quick Response Code:



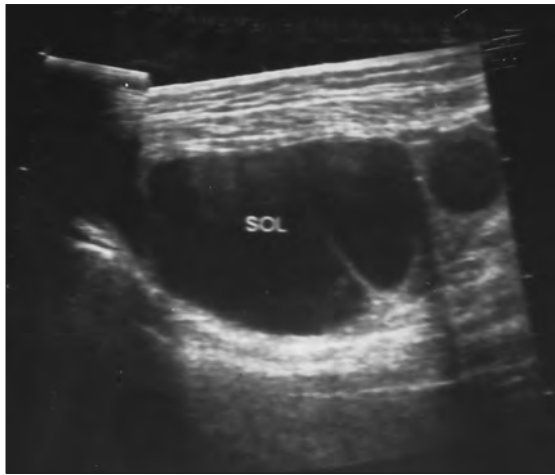
Website: [www.nigerianjsurg.c om](http://www.nigerianjsurg.c om)

DOI:  
10.4103/1117-6806.95479

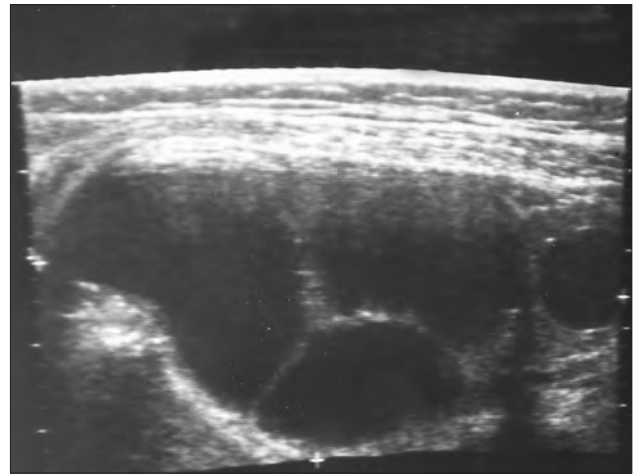
## CASE REPORT

A 52-year-old female patient presented to the surgical out patient department (OPD) with the chief complaints of swelling of the right calf region associated with pain for six months. The swelling was gradually increasing in size. The pain was aggravated on walking. On examination, no associated tenderness was found. The radius of the swelling was 10 cm. The cyst did not disappear or reduce on flexion of the knee joint. Illumination test was negative. Fluctuation was present. Skin over the swelling was normal. X-ray of knee joint did not reveal any abnormality. Ultrasonography (USG) suggested atypical Backer's cyst while color Doppler test did not detect any abnormality [Figures 1 and 2]. Routine blood tests (Hb%, total and differential leukocyte counts, serum creatinine and urea level, and fasting blood glucose) were found within normal limit. Chest X-ray (PA view) and electrocardiogram were also found within normal limit. She was planned for excision of cyst under spinal anesthesia.

She was explained with the nature of operation and anesthesia and a written consent was taken. She was given tab. alprazolam 0.25 mg at the night before the operation. On arrival to the operating room, an infusion of lactated Ringer's solution was established and was put with routine monitoring, viz., electrocardiogram, noninvasive blood pressure, and oxygen arterial saturation. She was prepared for spinal anesthesia after preloading with Ringer's Lactate at 10 ml/kg. Spinal anesthesia was given at sitting posture at L3-L4 inter-space using 25G Quincke spinal needle and 2.5 ml of 0.5% hyperbaric bupivacaine. The operation was done in prone position. Multiple lobular cysts were found within a large cystic cavity on opening of the calf muscle through longitudinal incision. She was given injection hydrocortisone 100 mg and injection chlorpromazine



**Figure 1:** Right upper calf muscle showing the cystic cavity



**Figure 2:** Lateral aspect of right upper calf muscle

intravenously on suspicion of hydatid cyst. Savlon<sup>®</sup> was used as scolicidal agent because of the risk of spillage. The cyst was excised totally which contained 22 daughter cysts. The diagnosis of muscular hydatidosis was confirmed by histopathologic examination. Later, USG of liver was done which did not reveal presence of any space occupying lesion suggestive of hydatid cyst.

The postoperative course was uneventful and she was discharged from hospital on postoperative day 4. The patient received adjuvant oral treatment with albendazole (400 mg twice daily; each course lasting 4 weeks, being interrupted by 2 weeks off therapy) for 6 months for prevention of recurrences. Total and differential leukocyte count (to diagnose leukopenia and eosinophilia) and serum transaminase levels were monitored during the therapy. The reports were found to be within normal limits. One year after the operation during follow-up visit she was found to be in good health and without any signs of recurrence.

## DISCUSSION

Muscle hydatidosis is uncommon, accounting only for 3–5% of all cases<sup>[3,4]</sup> and is usually secondary to hepatic or pulmonary disease. Most of the cases reported quadriceps,<sup>[3,5]</sup> gluteus,<sup>[6]</sup> trapezius,<sup>[7]</sup> psoas,<sup>[8]</sup> erector spinae,<sup>[9]</sup> biceps femoris,<sup>[3,10]</sup> adductor brevis,<sup>[11]</sup> infraspinatus,<sup>[3]</sup> biceps brachii,<sup>[6,12]</sup> and triceps brachii<sup>[3]</sup> as the muscles of involvement. Muscle hydatidosis involving gastrocnemius muscle in the popliteal fossa is very rare. Till now only two cases were reported.<sup>[3,13]</sup> Our case is different from them as it was diagnosed intraoperatively and managed accordingly.

Usually, intramuscular hydatid cysts are secondary, resulting either from the spread of cysts or viable larval tissue after spontaneous or trauma-induced cyst rupture or after operations for hydatidosis in distant regions.<sup>[1]</sup> Several factors would explain the exceptional nature of muscle localizations of hydatid cysts: Efficacy of the hepatic and pulmonary barriers, unfavorable muscle environment for the growth of hydatid larvae due to high lactic acid content and muscle's contractility which hinders intramuscular growth of

cysts.<sup>[4]</sup> The predominant localization in the proximal muscles of the lower limbs could be explained by the volume of the muscle mass and its rich blood supply.

It is important to establish the diagnosis preoperatively in order limit the risk of anaphylactic shock or dissemination of viable protoscolices in the event of puncture or accidental opening of the cyst during resection. Chest radiography, USG, computed tomography (CT), and magnetic resonance (MR) imaging are all can be used to depict hydatid cyst. However, the imaging method to be used depends on the organ involved and the growth stage of the cyst. Intramuscular hydatid disease can cause a variety of diagnostic problems, especially in the absence of typical radiologic findings. That happened in our case also, where the USG wrongly suggested the presence of Backer's cyst. Nevertheless, USG is the diagnostic tool of choice for the initial work-up and is particularly useful for detection of the floating membranes, daughter cysts, and hydatid sand in purely cystic lesions.<sup>[14]</sup> It is also used for staging and classification of *E. granulosus* infection.<sup>[15]</sup> CT is best for detecting cyst wall calcification and revealing the internal cystic structure posterior to calcification, and is the modality of choice in peritoneal seeding.<sup>[16]</sup> Both, CT and MR imaging can detect cyst wall defects as well as the complications such as rupture and infection of cysts.<sup>[16]</sup>

Immunodiagnosis can also play an important complementary role for primary diagnosis and also for follow-up of patients after surgical or pharmacological treatment. Detection of circulating *E. granulosus* antigens in sera is less sensitive than antibody detection, which remains the method of choice. The enzyme-linked immunosorbent assay (ELISA), the indirect immunofluorescence antibody test, immunoelectrophoresis (IEP), and immunoblotting (IB) are the routine laboratory tests used for serological diagnosis. The sensitivity and specificity of these tests vary according to the nature and source of the antigens used. In different studies when AgB was used as antigen, both ELISA and IB have shown specificity up to 100% and sensitivity up to 89% and 92%, respectively, in CE.<sup>[17]</sup>

Complete surgical treatment offers best hope for permanent cure

and should include excision of the primary lesion, the daughter cysts and the communicating fistulas as a whole specimen.<sup>[1]</sup> However, extension of cyst in different muscle layers through communicating fistulas involving different muscle groups may cause difficulty in complete excision and also spillage of daughter cysts resulting in recurrence. Concomitant drug treatment with antihelminthics such as albendazole or praziquantel reduces the risk of secondary echinococcosis and recurrence.<sup>[1,18]</sup> Prior injection of a scolicidal agent into the unopened cyst and mopping the operative field with sponges soaked in a scolicidal agent are the two most commonly employed measures. Hypertonic saline (15–20%), cetrimide (0.5%), chlorhexidine, hydrogen peroxide, and ethyl alcohol (70–95%) are some of the compounds used as scolicidal.<sup>[1]</sup> We used Savlon<sup>®</sup> as scolicidal agent because of its ready availability in the operation theatre. Also Savlon<sup>®</sup> has been proved to be the least concentration dependent and most effective scolicidal agent.<sup>[19]</sup>

Muscular hydatidosis is very rare and can cause difficulty in diagnosis, especially in the absence of typical radiological findings. The possibility of hydatid disease should always be kept in mind in the differential diagnosis of a cystic mass in the muscle, especially in endemic areas to avoid fine-needle biopsy and the consequences of spillage of cyst contents.

## ACKNOWLEDGEMENT

Debashree Golder, Assistant Professor, Department of Zoology, B.K.C College, Kolkata, India.

## REFERENCES

1. Guidelines for treatment of cystic and alveolar echinococcosis in humans. WHO Informal Working Group on Echinococcosis. Bull World Health Organ 1996;74:231-42.
2. Eckert J, Deplazes P. Biological, epidemiological, and clinical aspects of echinococcosis, a zoonosis of increasing concern. Clin Microbiol Rev 2004;17:107-35.
3. Gougoulas NE, Varitimidis SE, Bargiotas KA, Dovas TN, Karydakos G, Dailiana ZH. Skeletal muscle hydatid cysts presenting as soft tissue masses. Hippokratia 2010;14:126-30.
4. García-Alvarez F, Torcal J, Salinas JC, Navarro A, García-

- Alvarez I, Navarro-Zorraquino M, *et al.* Musculoskeletal hydatid disease: A report of 13 cases. Acta Orthop Scand 2002;73:227-31.
5. Ozkoç G, Akpınar S, Hersekli MA, Ozalay M, Tandoğan R. Primary hydatid disease of the quadriceps muscle: A rare localization. Arch Orthop Trauma Surg 2003;123:314-6.
6. Ates M, Karakaplan M. Hydatid cyst in the biceps and gluteus muscles: Case report. Surg Infect (Larchmt) 2007;8:475-8.
7. Calò PG, Tatti A, Tuveri M, Farris S, Nicolosi A. Hydatid cyst of trapezius muscle: An unusual localisation. Report of a case and review of the literature. Chir Ital 2007;59:873-6.
8. Bilanović D, Zdravković D, Randjelović T, Tosković B, Gacić J. Lesion of the femoral nerve caused by a hydatid cyst of the right psoas muscle. Srp Arh Celok Lek 2010;138:502-5.
9. Atalay F, Orug T, Arda K, Tosun O, Atalay F. An unusual case of hydatid disease located in the erector spinae muscle. JBR-BTR 2003;86:329-31
10. Hamdi MF, Touati B, Abid A. Primary hydatid cyst of the biceps femoris. Musculoskelet Surg 2010;94:59-61.
11. Acar A, Rodop O, Yenilmez E, Baylan O, Oncül O. Case report: Primary localization of a hydatid cyst in the adductor brevis muscle. Turkiye Parazitoloj Derg 2009;33:174-6.
12. Karapınar H, Yağdı S, Durmuş K, Sener M. Primary hydatid disease of the biceps brachii. J Shoulder Elbow Surg 2008;17:e6-8.
13. Seijas R, Catalán-Larracochea JM, Ares-Rodríguez O, Joshi N, de la Fuente JP, Pérez-Domínguez M. Primary hydatid cyst of skeletal muscle affecting the knee: A case report. Arch Orthop Trauma Surg 2009;129:39-41.
14. Turgut AT, Akhan O, Bhatt S, Dogra VS. Sonographic spectrum of hydatid disease. Ultrasound Q 2008;24:17-29.
15. WHO Informal Working Group. International classification of ultrasound images in cystic echinococcosis for application in clinical and field epidemiological settings. Acta Trop 2003;85:253-61.
16. Pedrosa I, Saíz A, Arrazola J, Ferreirós J, Pedrosa CS. Hydatid disease: Radiologic and pathologic features and complications. Radiographics 2000;20:795-817.
17. Zhang W, Li J, McManus DP. Concepts in immunology and diagnosis of hydatid disease. Clin Microbiol Rev 2003;16:18-36.
18. Shams-Ul-Bari, Arif SH, Malik AA, Khaja AR, Dass TA, Naikoo ZA. Role of albendazole in the management of hydatid cyst liver. Saudi J Gastroenterol 2011;17:343-7.
19. Besim H, Karayalçın K, Hamamci O, Güngör C, Korkmaz A. Scolicidal agents in hydatid cyst surgery. HPB Surg 1998;10:347-51.

**How to cite this article:** Bharati S, Pal M. Primary hydatid cyst in gastrocnemius muscle. Niger J Surg 2012;18:19-21.

**Source of Support:** Nil. **Conflict of Interest:** None declared.