

Case Report

A Self-Insertion of an Uncommon Urethrovesical Foreign Body for Autoerotism

Friday Emeakpor Ogbetere¹, Eshiobo Irekpita²

¹Department of Surgery, Edo University, Iyamho, Nigeria,

²Department of Surgery, Ambrose Alli University, Ekpoma, Nigeria

Submitted: 24-Jan-2020
Revised : 23-Jun-2020
Accepted: 05-Jul-2020
Published : 09-Mar-2021

ABSTRACT

Apart from iatrogenic causes, many of the foreign bodies in the bladder and urethra are self-inserted through the urethra as a result of psychiatric disturbances, sexual gratification, or erotic curiosity while intoxicated. Despite the reports on the presentation of urethrovesical foreign bodies in the medical literature, the insertion of foreign bodies through the urethra for the purpose of erotic satisfaction remains an enigma. Here, we report a case of a knotted earphone jack as an urethrovesical foreign body inserted for erotic reason by a 32-year-old man with no history of psychiatric disturbances. He could not retrieve it, and the bladder foreign body remained in this position for about 8 h. He was referred to the accident and emergency unit of our hospital, and open surgery was performed to retrieve it.

KEYWORDS: Earpiece, foreign bodies, urethra, urinary bladder

INTRODUCTION

Self-insertion of foreign bodies in the male urethra is a rare urologic emergency. A weird variety of objects self-inserted into the urinary tract have been reported and include electrical wires, batteries, glass, pencils, chopsticks, and telephone cables.^[1,2]

The insertion generally occurs during masturbation to produce erotic sensations and sexual gratification.^[2] These men are often under alcohol intoxication or are mentally challenged individuals. Rarely, insertion is by another person in order to relieve urinary complaints.^[3] The foreign body may be visible in the urethral meatus or disappear into the urethra. In rare cases, the lead point may disappear into the bladder.^[2]

Diagnosis of these foreign bodies can be done by clinical history, physical examination, and imaging studies of the patients. The treatment of the foreign bodies is determined by their size, position, shape, mobility, and the constituents of the foreign body.^[2,3] In most cases, minimally invasive and endoscopic removal is recommended to prevent bladder and urethral injuries. In some cases, however, surgical treatment should be recommended if the foreign body cannot be removed by endoscopic procedures.^[1,2]

CASE REPORT

A. O was a 32-year old unmarried male. He presented to a private hospital after 8 h of insertion of an earphone jack into his urethra for sexual gratification. He had used various objects such as needles and pen caps in the past for the same purpose. Attempts at its removal by himself and in a private facility failed necessitating his referral to our facility. He had no difficulty with urination. On physical examination, an earphone cord protruding out of the urethra [Figure 1] with minimal urethral bleeding was noted. There was no abdominal swelling or tenderness.

Urgent radiograph showed a transverse-lying earphone jack in the bladder [Figure 2].

Because it was a side connecting earphone jack, cystoscopic removal was avoided to prevent urethral injury. A suprapubic cystostomy approach was used. The knotted earphone jack was identified, transected, and removed, and the urethral component was pulled out antegrade [Figure 3]. Evaluation by the psychiatrist, using their psychometric analysis,

Address for correspondence: Dr. Friday Emeakpor Ogbetere, Department of Surgery, Edo University, Iyamho, Nigeria. E-mail: fridayemeakpor@gmail.com

This is an open access journal, and articles are distributed under the terms of the Creative Commons Attribution-NonCommercial-ShareAlike 4.0 License, which allows others to remix, tweak, and build upon the work non-commercially, as long as appropriate credit is given and the new creations are licensed under the identical terms.

For reprints contact: WKHLRPMedknow_reprints@wolterskluwer.com

How to cite this article: Ogbetere FE, Irekpita E. A self-insertion of an uncommon urethrovesical foreign body for autoerotism. *Niger J Surg* 2021;27:81-3.

Access this article online	
Quick Response Code: 	Website: www.nigerianjsurg.com
	DOI: 10.4103/njs.NJS_6_20

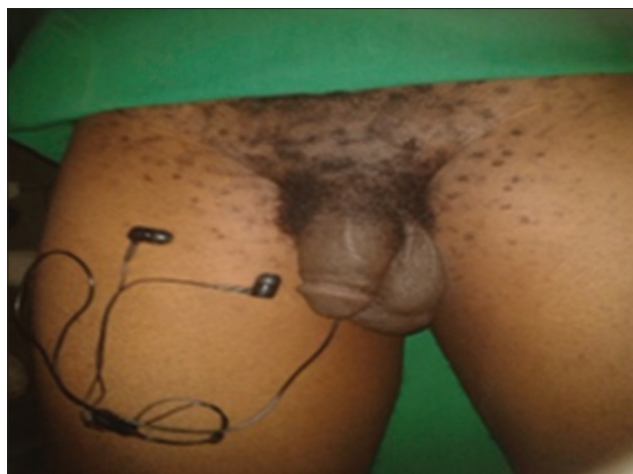


Figure 1: The earphone in situ

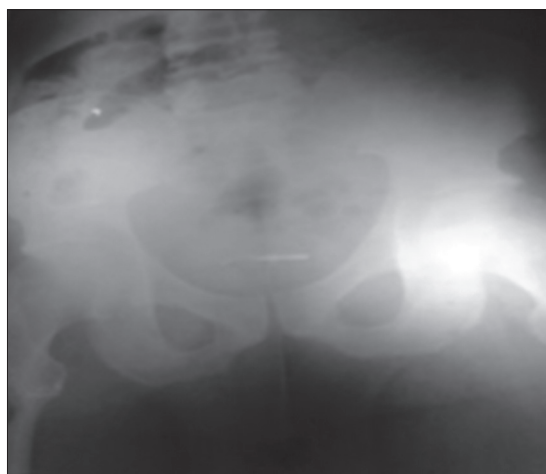


Figure 2: Plain X-ray showing transverse-lying earphone jack in the bladder



Figure 3: The transected earphone after removal

revealed no psychiatric disturbances. He was followed up in the urologic clinic for 6 months with no sequelae.

DISCUSSION

Foreign bodies reach the lumen of the bladder from accidental migration from surrounding structures, self-insertion for sexual gratification, or may be iatrogenic.^[3-5] When a wire is inserted into the urethra, the leading part may find its way into the bladder with a portion remaining in the urethra. The part of the wire in the bladder can form a loop or get knotted when the bladder contracts during micturition.^[6] This may make self-retrieval unsuccessful.

Most times, patients present only after failed attempt at self-removal or when they are symptomatic.^[6] Usually, they present with hematuria, urethritis, cystitis, or recurrent urinary tract infection.^[2] Clinical history, physical examination, and imaging studies (computed tomography and ultrasonography) of the patients usually help to clinch the diagnosis. Some authors have relied on cystoscopy for a definitive diagnosis.^[7,8]

Removal should be with minimal trauma. In most instances, urethrovessical foreign bodies are removed during cystoscopy.^[2] Where endoscopic removal is not possible because of the large size of the foreign body or when the foreign body is knotted, open suprapubic cystostomy is recommended.^[2,5,7]

Finally, psychiatric consultation should be done to prevent a recurrence.^[9] In our case, the patient underwent psychiatric evaluation and counseling.

Declaration of patient consent

The authors certify that they have all appropriate patient consent forms. In the form, the patient has given his consent for photographs, images, and other clinical information to be reported in the journal. The patient understands that his name and initials will not be published, and due effort will be made to conceal his identity.

Financial support and sponsorship

Nil.

Conflicts of interest

There are no conflicts of interest.

REFERENCES

1. Ghaly AF, Munishankar AR, Sultana SR, Nimmo M. Case report: Foreign body in male penile urethra. *Genitourin Med* 1996;72:67-8.
2. van Ophoven A, deKernion JB. Clinical management of foreign bodies of the genitourinary tract. *J Urol* 2000;164:274-87.
3. Sukkariet T, Smaldone M, Shah B. Multiple foreign bodies in the anterior and posterior urethra. *Int Braz J Urol* 2004;30:219-20.
4. Cho DS, Kim SJ, Choi JB. Foreign bodies in urethra and bladder by implements used during sex behavior.

- Korean J Urol 2003;44:1131-4.
5. Irekpita E, Imomoh P, Kesieme E, Onuora V. Intravesical foreign bodies: A case report and a review of the literature. *Int Med Case Rep J* 2011;4:35-9.
 6. Eckford SD, Persad RA, Brewster SF, Gingell JC. Intravesical foreign bodies: Five-year review. *Br J Urol* 1992;69:41-5.
 7. Datta B, Ghosh M, Biswas S. Foreign bodies in urinary bladders. *Saudi J Kidney Dis Transpl* 2011;22:302-5.
 8. Rafique M. Intravesical foreign bodies: Review and current management strategies. *Urol J* 2008;5:223-31.
 9. Rahman NU, Elliott SP, McAninch JW. Self-inflicted male urethral foreign body insertion: Endoscopic management and complications. *BJU Int* 2004;94:1051-3.