

## Case Report

# Left Paraduodenal Hernia: A Cause of Double Intestinal Obstruction

Isaac Assam Udo, Victor Obong

Department of Surgery,  
University of Uyo Teaching  
Hospital, Uyo, Nigeria

Submitted: 27-Apr-2020

Revised: 18-May-2020

Accepted: 05-Jun-2020

Published: 09-Mar-2021

### ABSTRACT

Paraduodenal hernias are of congenital origin and may present with symptoms and signs of small intestinal obstruction. These hernias are rare in our practice, and a definitive preoperative diagnosis is often not made as the symptoms are not specific. Early assessment and prompt and adequate resuscitation and surgery obviate the risk of strangulation and intestinal resection. This report highlights a rare cause of intestinal obstruction in a young male who presents with all the classical features of obstruction: colicky abdominal pain, distension, vomiting, and inability to pass stool or flatus. The diagnosis of paraduodenal hernia was made intraoperatively. We do not routinely request for barium examination or abdominal computed tomography scan in acute abdominal pain. These modalities can suggest a preoperative diagnosis.

**KEYWORDS:** *Congenital origin, intestinal obstruction, paraduodenal hernia*

## INTRODUCTION

Paraduodenal hernias (congenital mesocolic hernia, Tritze hernia, and retroperitoneal hernia) are a variety of internal hernias of congenital origin constituting 20%–50% of internal hernias.<sup>[1,2]</sup> The small intestine, partly or as a whole, herniates into a peritoneal pouch at the fourth part of the duodenum and may remain symptomless or culminate in an obstruction. Two types of paraduodenal hernias occur: the right (Waldeyer) and left (Lanzert). These hernias arise from malrotation of the mid-gut resulting in the formation of abnormal mesenteric pouches into which loops of small intestines can lodge. The free edge of the left pouch opening contains the inferior mesenteric artery and vein and the left colic artery.<sup>[3]</sup> Paraduodenal hernias are considered to be the most common cause of internal herniation.

Symptomatic hernias present with features of small intestinal obstruction (colicky abdominal pain, abdominal distension, vomiting, and inability to pass stool or flatus), but these are not specific clinical features that can suggest the diagnosis which is often made at laparotomy in centers where barium examination or computed tomography (CT) scans are not routinely requested for acute abdominal pain.

Prompt assessment of these patients is important to avert morbidity and mortality arising from intestinal

obstruction and strangulation. A detailed history of the abdominal pain, distension, vomiting, and constipation may only suggest intestinal obstruction without a specific cause. A plain abdominal radiogram and CT scan could suggest a definitive diagnosis of paraduodenal hernia. Adequate resuscitation and early surgery reduce the chances of intestinal resection and anastomosis on account of intestinal strangulation.

## CASE REPORT

A 33-year-old male presented in the emergency room with a 6-h history of sudden and progressively severe colicky abdominal pain associated with vomiting and abdominal distension. The pain originated in his left upper abdomen and became generalized over an hour with no aggravating or relieving factors. He had not passed feces or flatus throughout the course of the pain, and he vomited thrice and had no fever. There was no previous history of similar symptoms.

His temperature was 37.3°C, a pulse of 80/minute, and a respiratory rate of 22 cycles. His abdomen was grossly distended and tender. The bowel sounds were absent, and the digital rectal examination was unremarkable. An

*Address for correspondence:* Dr. Isaac Assam Udo, Department of Surgery, University of Uyo Teaching Hospital, Uyo, Nigeria.

E-mail: isaacudo@uniuyo.edu.ng

This is an open access journal, and articles are distributed under the terms of the Creative Commons Attribution-NonCommercial-ShareAlike 4.0 License, which allows others to remix, tweak, and build upon the work non-commercially, as long as appropriate credit is given and the new creations are licensed under the identical terms.

**For reprints contact:** WKHLRPMedknow\_reprints@wolterskluwer.com

**How to cite this article:** Udo IA, Obong V. Left paraduodenal hernia: A cause of double intestinal obstruction. *Niger J Surg* 2021;27:78-80.

### Access this article online

#### Quick Response Code:



**Website:** [www.nigerianjsurg.com](http://www.nigerianjsurg.com)

**DOI:** 10.4103/njs.NJS\_43\_20

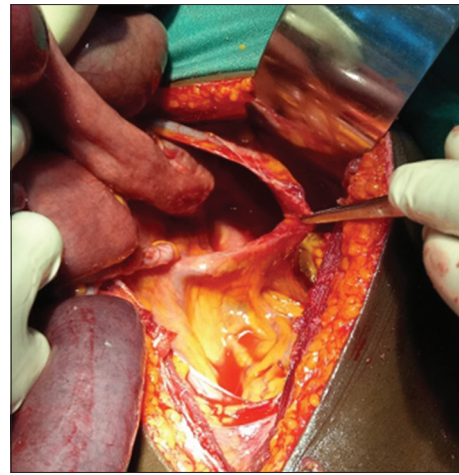
abdominal X-ray showed dilated small bowel loops with multiple air–fluid levels in the upper left quadrant. Blood chemistry and full blood count were normal. A clinical diagnosis of nonspecific abdominal pain was made.

He was resuscitated and underwent exploratory laparotomy with the findings of trapped twisted loops of the small bowel in a retroperitoneum pouch to the left of the duodenum opening and other loops of small intestines wrapped around itself in the peritoneal cavity (volvulus). The pouch had a 5–7 cm defect to the left of the duodenum along an avascular plane with vessels superior and inferior [Figure 1]. The dilated small intestinal loops (volvulus) were untorted, while the loops of intestines trapped in the peritoneal sac were reduced, appearing dusky red [Figure 2] but viable. The cecum and appendix were located in the right iliac fossa. The defect in the mesocolon was closed with silk sutures [Figure 3], ensuring that the vessels at its margins were not injured. The patient made a good recovery and was discharged in a week. He remains symptom free at 6 months of follow-up.

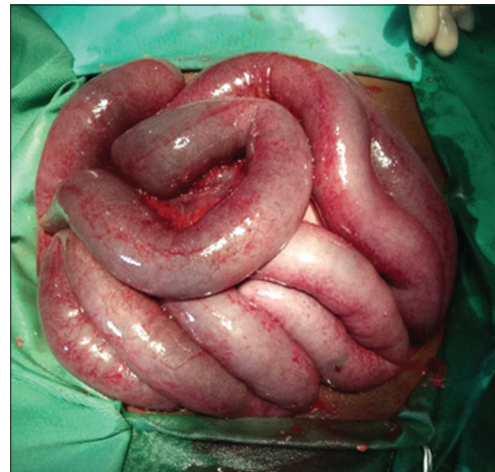## DISCUSSION

Paraduodenal hernias are of congenital origin. There is a wide anatomic variation in the pattern of the defect ranging from very subtle or inapparent to gross malrotation.<sup>[4]</sup> They are most common of the internal hernias which occur when an internal organ is trapped within the intra-abdominal compartment. Paraduodenal hernias form behind the mesocolon which failed to adhere to the posterior abdominal wall, a situation considered to arise from malrotation of the mid-gut. The left-sided hernias occur in the fourth part of the duodenum and make up 75% of cases of paraduodenal hernias.<sup>[5]</sup> The right-sided hernias occur through a defect in the mesentery of the first part of the jejunum.<sup>[6]</sup> Despite being congenital origin, in most cases, the disease manifests in adulthood with the highest incidence occurring in the 4<sup>th</sup>–6<sup>th</sup> decades of life<sup>[3]</sup> with a male preponderance. These hernias present with the typical features of small intestinal obstruction<sup>[7]</sup> but no specific diagnostic features to distinguish it, a situation which could lead to misdiagnosis,<sup>[8]</sup> delayed surgery, and possible complications. Recurrent abdominal pain and intestinal obstruction are features of left paraduodenal hernia.<sup>[9]</sup>

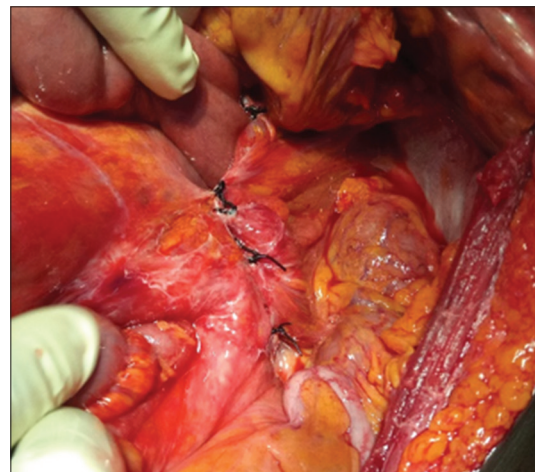
Radiographic imaging in left paraduodenal hernias shows small intestinal dilatation and multiple air–fluid levels on plain radiograph with a displacement of the small intestines to the left in barium meal. Multidetector CT shows a sac-like appearance in the left anterior pararenal space with clustering of dilated loops of the



**Figure 1:** Retroperitoneal pouch through which the small intestines were lodged. Notice the blood vessels at the edges of the defect



**Figure 2:** Dilated loops of dusky-red small intestines with petechiae reaction reduced from the pouch and freed from the torsion. The normal pink color returned in <5 min after reduction



**Figure 3:** Closure of the defect with interrupted silk sutures

small intestines,<sup>[10]</sup> and the inferior mesenteric vein lies anterior and medial to the opening of the sac and

displacement of the mesenteric vessels to the left in CT with intravenous contrast.<sup>[11]</sup> CT scan has superior diagnostic accuracy and sensitivity and can easily suggest the preoperative diagnosis of paraduodenal hernias, but we routinely request for plain X-rays in intestinal obstruction on account of cost, and so the specific diagnosis is only made intraoperatively.

Surgery is the treatment for paraduodenal hernias. The open procedure is still commonly practiced because most paraduodenal hernias are not diagnosed preoperatively. The obstruction is relieved by disimpacting the obstructed small intestinal loops from the mesocolon pouch and the opening closed; care must be taken not to injure the blood vessels at its margin,<sup>[2]</sup> as in the index case. Alternatively, the defect can be widened to prevent herniation of small intestines.<sup>[12]</sup> In strangulated cases, the affected loop of the intestine is resected and primary anastomosis is done; these subsets of patients have higher morbidity and mortality.<sup>[2,13]</sup> An increasing number of paraumbilical hernias are now diagnosed and treated laparoscopically.<sup>[14]</sup>

## CONCLUSION

Paraduodenal hernias are rare and present with nonspecific features of intestinal obstruction. They are frequently diagnosed intraoperatively, but modern imaging modalities can easily make a preoperative diagnosis. Early diagnosis and management limits the chances of strangulation.

## Declaration of patient consent

The authors certify that they have obtained all appropriate patient consent forms. In the form the patient(s) has/have given his/her/their consent for his/her/their images and other clinical information to be reported in the journal. The patients understand that their names and initials will not be published and due efforts will be made to conceal their identity, but anonymity cannot be guaranteed.

## Financial support and sponsorship

Nil.

## Conflicts of interest

There are no conflicts of interest.

## REFERENCES

1. Uchiyama S, Imamura N, Hidaka H, Maehara N, Nagaike K, Ikenaga N, *et al.* An unusual variant of a left paraduodenal hernia diagnosed and treated by laparoscopic surgery: Report of a case. *Surg Today* 2009;39:533-5.
2. Munir A, Saleem M, Hussain S. Paraduodenal hernia – A case report. *J Pak Med Assoc* 2014;54:162-3.
3. Zaz MA, Kawoosa U, Reyaz A, Jan I. Paraduodenal hernia: Case report of a rare internal hernia presenting as acute abdomen. *Trop Gastroenterol* 2011;32:74-6.
4. Kapfer SA, Rappold JF. Intestinal malrotation-not just the pediatric surgeon's problem. *J Am Coll Surg* 2004;199:628-35.
5. Kurachi K, Nakamura T, Hayashi T, Asai Y, Kashiwabara T, Nakajima A, *et al.* Left paraduodenal hernia in an adult complicated by ascending colon cancer: A case report. *World J Gastroenterol* 2006;12:1795-7.
6. Hassani K, Aggouri Y, Laalim S, Toughrai I, Mazaz K. Left para-duodenal hernia: A rare cause of acute abdomen. *Pan Afr Med J* 2014;17:230.
7. Yun MY, Choi YM, Choi SK, Kim SJ, Ahn SI, Kim KR. Left paraduodenal hernia presenting with atypical symptoms. *Yonsei Med J* 2010;51:787-9.
8. Lim CH, Ong HS, Eng A. A rare cause of abdominal pain. Left paraduodenal hernia. *Gastroenterology* 2015;149:551-2.
9. Wong Y, Lath N, Eng A, Navasivagum V. Clinical features of paraduodenal hernia. *Proc Singap Healthcare* 2018;27:139-42.
10. Shadhu K, Ramlaguna D, Ping X. Paraduodenal hernia: A report of five cases and review of literature. *BMC Surg* 2018;18:32.
11. Doishita S, Takeshita T, Uchima Y, Kawasaki M, Shimono T, Yamashita A, *et al.* Internal hernias in the era of multidetector CT: Correlation of imaging and surgical findings. *Radiographics* 2016;36:88-106.
12. Correia M, Amonkar D, Audi P, Vaz O, Samant D. Paraduodenal hernia: A case report and review of the literature. *Saudi Surg J* 2014;2:96-8.
13. Shi Y, Felsted AE, Masand PM, Mothner BA, Nuchtern JG, Rodriguez JR, *et al.* Congenital left paraduodenal hernia causing chronic abdominal pain and abdominal catastrophe. *Pediatrics* 2015;135:e1067-71.
14. Parmar BP, Parmar RS. Laparoscopic management of left paraduodenal hernia. *J Minim Access Surg* 2010;6:122-4.