

Case Report

Ectopic Kidney Mimicking Appendicular Abscess

Danny Darlington Carbin Joseph, Jagatheswaran Chinnathambi, Arunkumar Jamburaj

Department of Urology,
Pondicherry Institute
of Medical Sciences,
Pondicherry, India

Submitted: 21-Oct-2019
Revised: 04-Jul-2020
Accepted: 09-Jul-2020
Published: 09-Mar-2021

INTRODUCTION

Acute appendicitis is a commonly encountered surgical emergency caused by appendicular luminal obstruction leading to bacterial proliferation, inflammation, ischemia, and ultimately perforation of the appendix. An accurate clinical diagnosis is difficult in children and adolescents and 15%–40% of them undergoing appendectomy end up in having a normal appendix removed.^[1] Several congenital and acquired disorders of the genitourinary tract can mimic appendicular pathologies, and hence, surgeons must be aware of such conditions and have a high index of suspicion. Ectopic kidneys are abnormally located kidneys with an incidence of one in 500–3000 with left side more commonly affected than the right.^[1] These congenitally abnormal kidneys can develop hydronephrosis in 50% of the cases and give rise to symptoms depending on their location. Pain originating from an ectopic kidney can mimic acute appendicitis if the kidney is in the right iliac fossa.^[1] Moreover, both the conditions can present with fever and signs of peritonitis, further confusing the clinical picture. The genitourinary conditions can be managed in a delayed manner, while acute appendicitis generally requires emergency surgery. We present a case of right iliac fossa mass, which was initially mistaken for an appendicular abscess. The emergent presentation and absence of prior urological symptoms made the clinical diagnosis challenging. However, a complete radiological

ABSTRACT

Ectopic kidney is a congenital anomaly of renal position, which is commonly asymptomatic. Symptoms arising from pelvic kidneys can closely mimic pathological processes of nearby organs and vice versa. We report an 18-year-old girl who presented with acute onset of a painful lump in the right iliac fossa. Although the clinical features mimicked an appendicular abscess, the judicious use of cross-sectional imaging aided in the proper diagnosis. Pyonephrosis of a right-sided lumbar kidney was confirmed on further imaging and nephrectomy was performed. This case has been presented to highlight the significance of renal imaging in patients suspected of an appendicular abscess.

KEYWORDS: *Appendicular mass, ectopic kidney, pyonephrosis*

workup helped uncover the final diagnosis of an ectopic right kidney with pyonephrosis.

CASE REPORT

An 18-year-old girl presented to the emergency department with complaints of right iliac fossa pain, fever, and nonbilious vomiting of 1 day. The pain was dull aching and nonradiating, and she denied any previous similar pain episodes or urinary tract infections. She also denied any history of trauma, sexual intercourse, calculuria, or hematuria. She did not suffer from any comorbid illness and was not on any long-term medications.

Her vitals were within the normal limits except for a regular pulse rate of 120 beats/min and pyrexia of 102°F. Abdominal examination revealed a vague nonpulsatile lump in the right iliac fossa of size approximately 12 cm extending into the right lumbar region [Figure 1a]. Palpation confirmed the lump to be 15 cm × 10 cm sized, tender, firm, and not moving with respiration. There was no other palpable mass or organomegaly and the rest of the abdomen was soft. Auscultation revealed normal bowel sounds and the other systems were unremarkable on examination.

Address for correspondence: Dr. Danny Darlington Carbin

Joseph,
Department of Urology, Pondicherry Institute of Medical Sciences,
Pondicherry, India.
E-mail: dannycarbin2@gmail.com

Access this article online

Quick Response Code:



Website: www.nigerianjsurg.com

DOI: 10.4103/njs.NJS_49_19

This is an open access journal, and articles are distributed under the terms of the Creative Commons Attribution-NonCommercial-ShareAlike 4.0 License, which allows others to remix, tweak, and build upon the work non-commercially, as long as appropriate credit is given and the new creations are licensed under the identical terms.

For reprints contact: WKHLRPMedknow_reprints@wolterskluwer.com

How to cite this article: Joseph DD, Chinnathambi J, Jamburaj A. Ectopic kidney mimicking appendicular abscess. *Niger J Surg* 2021;27:63-5.

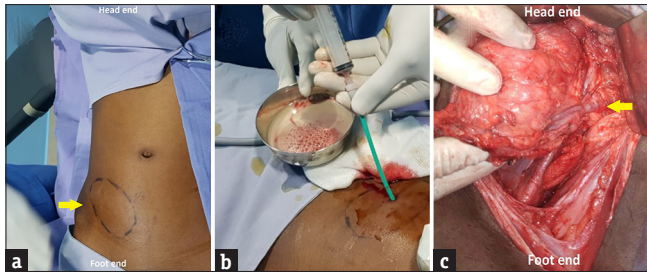


Figure 1: Clinical images showing the (a) right iliac fossa lump (arrow) (b) pus aspirated from the pyonephrotic kidney after a nephrostomy was inserted (c) intraoperative image depicting the anomalous origin of renal vessels from the common iliac vessels (arrow)

Her laboratory values such as serum creatinine, urea, electrolytes, and blood culture were normal. However, the hemogram showed leukocytosis (19,500 cells/mm³) with profound neutrophilia (82%) and a shift to the left. Urine analysis showed plenty of pus cells and the culture of urine grew colonies of *Escherichia coli*. An ultrasonogram was performed, which showed that the right iliac fossa was occupied by a large reniform mass of size 18 cm × 15 cm × 9 cm with a central large fluid and stone-filled area communicating with multiple peripheral areas laden with moving echoes and stones. The ultrasonogram, however, failed to identify kidney in the right renal fossa, raising the suspicion of an ectopic right kidney. A contrast-enhanced computed tomography (CECT) confirmed the lumbar position of the right kidney which was malrotated with thinned out parenchyma and an anteriorly facing renal pelvis [Figure 2a and b]. The collecting system was dilated with multiple pelvic and calyceal stones and extensive perinephric fat stranding. There was no uptake, excretion, or drainage of contrast in the ectopic right kidney [Figure 2c]. The contralateral kidney and rest of the abdomen, including the appendix, were normal.

The patient was empirically started on intravenous injections ceftriaxone 1 g twice daily and amikacin 400 mg once daily. In view of her toxic presentation, a percutaneous nephrostomy was inserted into the pyonephrotic kidney under ultrasound guidance, after informed consent by the girl and her parents. The nephrostomy drained 200 ml of pus, which grew *E. coli* on culture [Figure 1b]. The antibiotic regimen was switched over to intravenous injection of piperacillin-tazobactam 4.5 g thrice daily, based on the antibiotic sensitivity pattern. Persistently low nephrostomy output for more than a week prompted a nephrectomy, which was accomplished extra-peritoneally through a Modified Gibson incision after 2 weeks of conservative management. The peritoneum was medialized and the ureter was identified and ligated, followed by careful circumferential dissection of the kidney. The hilar vessels

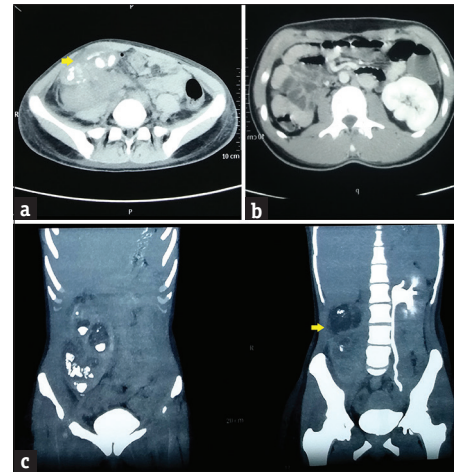


Figure 2: Right ectopic kidney seen on (a) Noncontrast computed tomography occupying the right iliac fossa with extensive perinephric stranding, anteriorly facing pelvis (arrow) filled with calculi and thinned out parenchyma (b) Contrast enhanced computed tomography showing the striking absence of kidney in right renal fossa (c) computed tomography urogram showing absence of contrast excretion in the dilated ectopic kidney (arrow) with normal drainage in contralateral kidney

of the grossly infected ectopic kidney were controlled as they originated from the common iliac vessels, and the kidney was delivered out in toto [Figure 1c]. The histopathological examination of the specimen revealed features of chronic pyelonephritis and the postoperative period was uneventful. The patient is symptom-free on follow-up after 5 months with normal urine output of 2L per day and serum creatinine of 1.0 mg/dl. Follow-up ultrasonogram performed at 5 months revealed normal contralateral kidney, ureter, and the bladder.

DISCUSSION

Ectopic kidneys are congenital anomalies of renal position with the kidneys positioned anywhere from the thorax to the pelvis. They are rarely symptomatic, which occurs when the malrotated and malascended kidneys get obstructed and infected.^[1] Around 50% of them show dilated collecting systems and 30% have vesicoureteric reflux.^[1] These conditions predispose to pyelonephritis, stone formation, and eventual loss of the renal unit.

Dalpia *et al.*, in their review of genitourinary anomalies presenting with appendicitis-like symptoms, point out that ectopic kidneys, nephroptosis, ectopic ureter, ureteric duplication, bladder diverticula, and ureteric obstruction can all mimic appendicular pathologies.^[2] However, pyonephrosis mimicking appendicular pathology has not been reported. On the other hand, appendicitis can itself be a manifestation of underlying genitourinary pathology. Acute appendicitis can also cause inflammation of the nearby organs such as adrenals, kidneys, ureters, bladder, prostate, scrotum, and penis producing symptoms pertaining to these organs.^[2] Pelvic kidney

with pyelonephritis mimicking acute appendicitis has been reported in the literature. Taylor and Steen report a case of pyelonephritis with ureteric calculus in an ectopic kidney presenting with right iliac fossa pain and rebound tenderness, thereby mimicking acute appendicitis.^[3] However, our case is an extremely rare presentation with no previous report of acute presentation of pyonephrosis of an ectopic kidney in the literature available. Although pyonephrosis is a chronic process, the patient surprisingly had no symptoms before the acute presentation.

While the management of appendicular mass is conservative, followed later by interval appendicectomy, nephrectomy is the treatment for pyonephrosis.^[2] This underlines the paramount importance in differentiating these two entities. A thorough history focusing on previous urological complaints supplemented by a focused clinical examination is the first step in arriving at the correct diagnosis. Although ultrasonogram with a sensitivity of 88% and specificity of 94% is sufficient to diagnose acute appendicitis, atypical presentation or suspicion of associated genitourinary pathologies warrants a contrast-enhanced computed tomography.^[4]

The management of pyonephrosis in the ectopic kidney is essentially the same as in normally placed kidneys. This essentially involves a simple nephrectomy which can be performed either by the open or laparoscopic method.^[5,6] The operative procedure of open simple nephrectomy differs in employing a Modified Gibson incision. The hilar vascular anatomy must be ascertained preoperatively from the angiographic phase of the CECT as the renal vessels are likely to arise from the iliac vessels, as in our case.^[7] In the present case, a percutaneous nephrostomy was inserted because of the acute presentation and the presence of systemic signs and symptoms. Open simple nephrectomy was performed after the systemic signs and symptoms improved, thereby reducing the morbidity.

CONCLUSION

This case has been presented for its rarity and to emphasize the fact that genitourinary diseases can

mimic abdominal emergencies and vice versa. Hence, surgeons must embark on surgically treating abdominal and pelvic emergencies only after complete radiological investigations, especially in the presence of suspicious imaging findings.

Declaration of patient consent

The authors certify that they have obtained all appropriate patient consent forms. In the form, the patient has given her consent for her images and other clinical information to be reported in the journal. The patient understands that name and initials will not be published and due efforts will be made to conceal identity, but anonymity cannot be guaranteed.

Financial support and sponsorship

Nil.

Conflicts of interest

There are no conflicts of interest.

REFERENCES

1. Lossius MN, Araya CE, Henry DD, Neiberger RE. Patient with an unusual cause right lower quadrant pain and vomiting: Pyelonephritis of an ectopic right kidney masquerading as acute appendicitis. *Case reports in medicine*; 2009. Available from: <https://www.hindawi.com/journals/crim/2009/638501/>. [Last accessed on 2019 Sep 16].
2. Dalpiaz A, Gandhi J, Smith NL, Dagur G, Schwamb R, Weissbart SJ, *et al.* Mimicry of appendicitis symptomatology in congenital anomalies and diseases of the genitourinary system and pregnancy. *Curr Urol* 2017;9:169-78.
3. Taylor D, Steen C. Unilateral ectopic kidney mimicking acute appendicitis: A case study. *ANZ J Surg* 2019;89:1520-1.
4. Demetrashvili Z, Kenchadze G, Pipia I, Ekaladze E, Kamkamidze G. Management of appendiceal mass and abscess. An 11-year experience. *Int Surg* 2015;100:1021-5.
5. Gupta R, Gupta S, Choudhary A, Basu S. Giant pyonephrosis due to ureteropelvic junction obstruction: A case report. *J Clin Diagn Res* 2017;11:PD17-8.
6. Arvind NK, Singh O, Gupta SS, Sahay S, Ali K, Dharaskar A. Laparoscopic nephrectomy for pyonephrosis during pregnancy: Case report and review of the literature. *Rev Urol* 2011;13:98-103.
7. Eid S, Iwanaga J, Loukas M, Oskouian RJ, Tubbs RS. Pelvic kidney: A review of the literature. *Cureus* 2018;10:e2775.