

Case Report

Anal Melanoma: A Case Report of a Rare and Lethal Malignancy in a Suburban Nigerian Teaching Hospital

Samuel Oluwafemi Fatudimu^{1,2}, Oladipo Omoseebi^{3,4}, Olakunle Fatai Babalola^{1,2}, Saheed Olatunde Akanni¹

¹Department of Surgery, Federal Teaching Hospital, Ido-Ekiti, Ekiti State, Nigeria,

²Department of Surgery, Afe-Babalola College of Medicine and Health Sciences, Ado-Ekiti, Ekiti State, Nigeria, ³Department of Histopathology, Federal Teaching Hospital, Ido-Ekiti, Ekiti State, Nigeria, ⁴Department of Anatomic Pathology, College of Medicine and Health Sciences, Afe-Babalola University, Ado-Ekiti, Ekiti State, Nigeria

Submitted: 06-Dec-2019

Accepted: 07-May-2020

Published: 09-Mar-2021

ABSTRACT

The aim of this report is to highlight the challenges involved in the diagnosis and treatment of anal melanoma in a tertiary hospital in Nigeria. It is a case report of an 84-year-old man who was managed for anal malignant melanoma. Despite inadequate investigative tools and less radical surgical treatment, the survival period of the index patient was comparable to the median survival quoted in the literature. Despite its rarity, mucosal melanomas also occur in the tropics. Prompt diagnosis, adequate imaging, and standardized treatment may improve its outlook in the nearest future.

KEYWORDS: Anal melanoma, lethal, rare

INTRODUCTION

Anal melanomas are the most common presentation of mucosal melanomas and they have a very poor prognosis, owing to their early spread to lymph nodes and advanced stage of the disease at diagnosis.^[1] Mucosal melanomas are rare and may occur in the anus, mouth, vagina, and the intestines. Melanomas can, however, affect other body structures, most commonly the skin (cutaneous) and the eye (ocular).^[1]

CASE REPORT

AS, an 84-year-old male farmer presented to our surgical outpatient department (SOPD) on August 10, 2016, with complaints of persistent anal pain, worse during the passage of stools and intermittent hemochezia of fresh blood streaking the feces for 4 months prior to presentation. He had associated anorexia and weight loss. There was occasional constipation, however, there was neither tenesmus nor

anal protrusion. There were no comorbid illnesses. Physical examination revealed a chronically ill-looking elderly man in mild painful distress. He was not pale, anicteric, and not dehydrated. There was no significant peripheral lymph node enlargement. His vital signs were within the normal limit. His chest was clinically clear and his cardiovascular status was grossly intact.

His abdominal examination revealed a flat nontender abdomen. His liver, spleen, and kidneys were not palpably enlarged. Ascites was not demonstrable and the bowel sounds were normoactive. Rectal examination revealed good perianal hygiene with a normal sphincteric tone. Digital examination revealed a sessile-like polyp about 2 cm × 2 cm, 1.5 cm above the anal verge, which

Address for correspondence: Dr. Samuel Oluwafemi Fatudimu, Department of Surgery, Federal Teaching Hospital Ido-Ekiti, Ekiti State, Nigeria.
E-mail: fatudimus@gmail.com

Access this article online

Quick Response Code:



Website: www.nigerianjsurg.com

DOI: 10.4103/njs.NJS_63_19

This is an open access journal, and articles are distributed under the terms of the Creative Commons Attribution-NonCommercial-ShareAlike 4.0 License, which allows others to remix, tweak, and build upon the work non-commercially, as long as appropriate credit is given and the new creations are licensed under the identical terms.

For reprints contact: WKHLRPMedknow_reprints@wolterskluwer.com

How to cite this article: Fatudimu SO, Omoseebi O, Babalola OF, Akanni SO. Anal melanoma: A case report of a rare and lethal malignancy in a suburban Nigerian Teaching Hospital. *Niger J Surg* 2021;27:59-62.



Figure 1: Photomicrograph showing poorly formed nests of epitheloid malignant melanocytic cells with intracellular and extracellular melanin production at $\times 10$

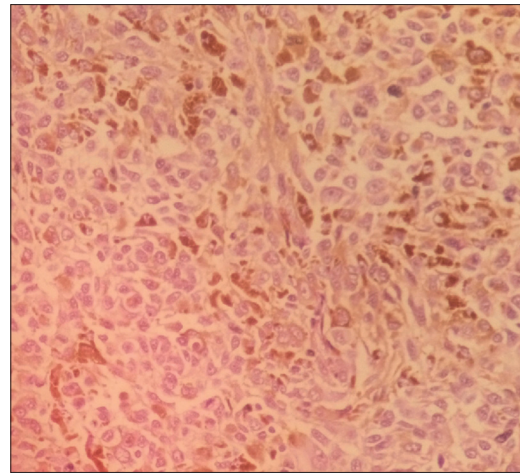


Figure 2: Photomicrograph showing poorly formed nests of epitheloid malignant melanocytic cells with intracellular and extracellular melanin production at $\times 40$

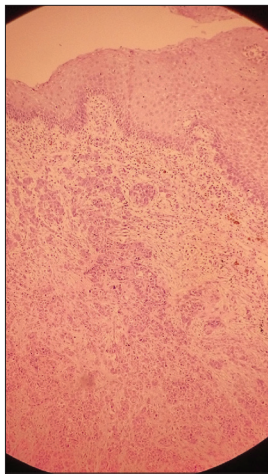


Figure 3: Photomicrograph showing malignant cells at the dermoepidermal junction and infiltrating into the deeper tissues

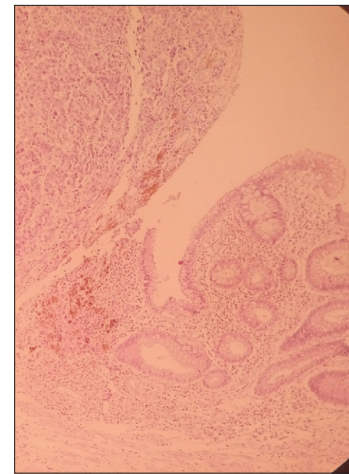


Figure 4: Photomicrograph showing malignant cells invading around benign intestinal glands of the upper anal area at $\times 10$

was excruciatingly tender and can be gotten above. It was slightly mobile on the rectal wall. Examining the finger was stained with fresh blood. The groin lymph nodes were not palpably enlarged. There was neither spinal tenderness nor deformity, and his extremities were normal. A clinical diagnosis of anal polyp to rule out malignancy was made. A plain radiograph of the chest showed normal findings. Abdominopelvic ultrasound also revealed normal findings. Pelvic magnetic resonance imaging and chest and abdominopelvic computed tomography scanning were not done due to the patient's financial constraint. His hemogram, urinalysis, electrolytes, and urea evaluations were within the normal limits. Informed consent was obtained and he was worked up for wide local excision (WLE) of the polypoidal lesion under subarachnoid block. Digital examination under anesthesia was done, and proctoscopy revealed a dark-bluish sessile mass 1.5 cm

from the anal verge at 4 O'clock position, measuring 2 cm \times 2.5 cm. Excision of the lesion was done with about 2 cm margin and the residual defect was apposed using vicryl 2/0 sutures. Histopathologic evaluation of the specimen showed anal melanoma. He was counseled for abdominoperineal resection (APR) with terminal colostomy, but he declined as he was not prepared to live with a stoma. There was a significant improvement with his symptoms. He was given hematinics without folate and stool softener and his residual anal pain was treated with topical anesthetic gel. He was discharged 4 days postoperatively and followed up in SOPD. Eleven months after the procedure, he presented at the SOPD with a left groin swelling which on clinical examination revealed features suspicious of malignant groin lymph nodes. The enlarged lymph nodes were subjected to fine-needle aspiration cytology which confirmed malignant cells. He was counseled for block lymph node

dissection and salvage chemotherapy, and he, however, declined due to financial constraints. He was last seen in the clinic, 12 months after the procedure. Contact with his relative revealed that he died approximately 16 months after the procedure in a private hospital as there was an industrial action in the health sector in the country during the period, hence could not present to the teaching hospital.

Histopathologic report

Macroscopic review of the specimen showed three fragments of brownish tissues cumulatively measuring 4.0 by 4.0 by 2.0 cm.

Microscopic sections showed poorly formed nests and singly disposed hyperchromatic and pleomorphic cells. The cells were epithelioid with irregular nuclei and prominent nucleoli with foci of intracellular and extracellular melanin pigment depositions. The cells were seen extending from the basal layer of the overlying stratified squamous epithelium and infiltrating into the subcutaneous tissue. There were areas consisting of intestinal glands lined by benign columnar epithelial cells. Frequent mitoses including atypical ones were also seen [Figures 1-4]. Features were in keeping with malignant melanoma.

DISCUSSION

Anal melanoma was first reported by Moore in 1857.^[2] Anorectal melanomas account for 1% of all melanomas and constitute 0.5%–2% of all anorectal malignancies.^[3] Anal melanomas typically present with nonspecific lower gastrointestinal symptoms such as rectal bleeding, anal pain, and anal mass and are often misdiagnosed as hemorrhoids, polyps, or rectal ulcers.^[3] It is said to be more common in Caucasians, corroborated by the paucity of case reports emanating from Africa. It is also said to occur more commonly in elderly females;^[4] however, an elderly male was affected in our case.

Due to its rarity, standardized management protocols have not been outlined based on randomized trials to achieve optimal treatment plans.^[5] Immunohistochemistry has been employed in its diagnosis including evaluation of S-100, melan A, HMB-45, and tyrosinase,^[6] but these are not yet readily available in most parts of Nigeria. Our patient's management was also hindered by poor staging facilities, inadequate health insurance schemes, and consequent low funds for care.

The extent of primary surgical intervention is not clear-cut; both WLE and APR of the rectum have been employed; however, APR has not demonstrated a significant survival advantage over WLE.^[7] Some newer

studies suggested WLE as initial surgical treatment, as more radical surgeries have not shown significant benefit.^[7] Majority of the patients progress to metastatic disease, regardless of initial treatment offered, as demonstrated also in our index case. However, the use of chemotherapy (intravenous dacarbazine) and interferon-gamma (immunotherapy) may improve overall survival and have been advocated in advanced cases.^[8] Locoregional metastasis to groin lymph nodes may occur. Common sites of distant metastasis are the liver and lungs.^[9] Radiation therapy may reduce local recurrence and probably enhance sphincter-saving procedures but does not improve survival.^[10] Most patients eventually succumb regardless of treatment offered due to the aggressive nature and rapid progression of the disease.^[11] The prognosis is poor with <20% 5-year survival and a median survival of 25 months,^[11] as our index patient also died approximately 20 months after the onset of his symptoms.

CONCLUSION

Anal melanoma also occurs in the tropics with its attending high mortality. Poor health-care support and inadequate investigative facilities in some African countries may make its diagnosis more difficult and its outcome grimmer.

Acknowledgment

We acknowledge Professor Olusoga Olusola Akute (Professor of Surgery) who assisted us in reviewing this case report.

Declaration of patient consent

The authors certify that they have obtained all appropriate consent from the patient and his relatives. The relatives gave their consent that his images and other clinical information can be reported in the journal. His relatives understand that his name will not be published and due effort will be made to conceal his identity, but anonymity cannot be guaranteed.

Financial support and sponsorship

Nil.

Conflicts of interest

There are no conflicts of interest.

REFERENCES

1. Bhattacharya K. Short cases in surgery. CBS Pub 2012;2:61-72.
2. Moore R. Recurrent melanosis of the rectum, after previous removal from the verge of the anus, in a man aged sixty-five. *Lancet* 1857;1:290.
3. Singer M, Mutch MG. Anal melanoma. *Clin Colon Rectal Surg* 2006;19:78-87.
4. McLaughlin CC, Wu XC, Jemal A, Martin HJ, Roche LM, Chen VW. Incidence of noncutaneous melanomas in the U.S.

- Cancer 2005;103:1000-7.
5. Weyandt GH, Eggert AO, Houf M, Raulf F, Bröcker EB, Becker JC. Anorectal melanoma: Surgical management guidelines according to tumour thickness. *Br J Cancer* 2003;89:2019-22.
 6. Chute DJ, Cousar JB, Mills SE. Anorectal malignant melanoma: Morphologic and immunohistochemical features. *Am J Clin Pathol* 2006;126:93-100.
 7. Zhou HT, Zhou ZX, Zhang HZ, Bi JJ, Zhao P. Wide local excision could be considered as the initial treatment of primary anorectal malignant melanoma. *Chin Med J (Engl)* 2010;123:585-8.
 8. Kim KB, Sanguino AM, Hodges C, Papadopoulos NE, Eton O, Camacho LH, *et al.* Biochemotherapy in patients with metastatic anorectal mucosal melanoma. *Cancer* 2004;100:1478-83.
 9. DeMatos P, Tyler DS, Seigler HF. Malignant melanoma of the mucous membranes: A review of 119 cases. *Ann Surg Oncol* 1998;5:733-42.
 10. Brady MS, Kavolius JP, Quan SH. Anorectal melanoma: A 64-year experience at Memorial Sloan-Kettering Cancer Center. *Dis Colon Rectum* 1995;38:146-51.
 11. Chang AE, Karnell LH, Menck HR. The National Cancer Data Base report on cutaneous and noncutaneous melanoma: A summary of 84,836 cases from the past decade. The American College of Surgeons Commission on Cancer and the American Cancer Society. *Cancer* 1998;83:1664-78.