

## Case Report

# Unilateral Hypoplastic Pelvic Ectopic Kidney Presenting as a Cold Abscess: A Case Report

Olalekan John Adepoju<sup>1</sup>, Michael Chukwugoziem Nweke<sup>2</sup>, Oluwafunmilayo Yewande Soneye<sup>1</sup>, Clement Abu Okolo<sup>3</sup>, Adegbolahan Jacob Fakoya<sup>1</sup>

<sup>1</sup>Department of Surgery, University College Hospital/ University of Ibadan, Ibadan, Nigeria, <sup>2</sup>Department of Pathology, University College Hospital, Ibadan, Nigeria, <sup>3</sup>Department of Pathology, University College Hospital/ University of Ibadan, Ibadan, Nigeria

Submitted: 17-Jun-2019  
Revised : 09-Jan-2020  
Accepted : 16-Aug-2020  
Published : 09-Mar-2021

### ABSTRACT

Renal ectopia, even though a benign condition, presents diagnostic challenges when its complications arise. Cold abscess in an abnormally sited kidney may, therefore, create a diagnostic conundrum for the clinician. We present the case of a 55-year-old male who had a suppurating ectopic kidney that mimicked an abdominal visceral mitotic lesion necessitating initial laparotomy, reviewed the literature, and highlighted the need to consider the differential diagnosis, especially in patients who have been referred from peripheral hospitals where generous antibiotic therapy has been instituted. We also recommend undertaking a preoperative split renal scintigraphy where available, especially when nephrectomy is considered.

**KEYWORDS:** Cold abscess, ectopic kidney, renal ectopia

## INTRODUCTION

Ectopic kidneys, usually a result of anomalies of ascent, are relatively uncommon with prevalence between 1:500 and 1:3000.<sup>[1-3]</sup> Even though not life-threatening, renal ectopia poses a diagnostic dilemma, especially when complications arise. For instance, acute pyelonephritis of a right pelvic kidney is known to mimic acute appendicitis or an appendix mass.<sup>[4]</sup>

Majority of patients are asymptomatic, however associated complications include vesicoureteric reflux (VUR), urolithiasis, hydronephrosis, and an increased risk of urinary tract infection.<sup>[3,4]</sup> It is believed that the ectopic kidney has no increased risk of malignancy.<sup>[1]</sup> Asymptomatic ectopic kidneys are usually incidental findings commonly during radiological investigations or surgical procedures undertaken for a typically unrelated indication. Therefore, the diagnostic conundrum produced by symptomatology of diseases of the ectopic kidney makes special evaluation and treatment considerations become necessary.<sup>[3]</sup>

Renal abscess, especially in a normally sited kidney typically results from hematogenous seeding of pyogenic organisms, tends to be unilateral, more common on the right, and constitutional symptoms – fever, chills, nausea, vomiting, malaise, anorexia, etc., – are present. Urinary

symptoms are uncommon, and urine culture may either be sterile<sup>[5]</sup> or positive – with yield up to 43% in some series.<sup>[6]</sup> The increased risk of retrograde upper urinary tract infection in a pelvic kidney due to VUR, therefore, worsens its predisposition to suppuration.

This report aims to illustrate an uncommon deceptive clinical presentation of a previously undiagnosed ectopic kidney mimicking a cachectic disease condition which necessitated urgent surgical care.

## CASE REPORT

We report the case of a 55-year-old male, who presented to the neurosurgical spine clinic before being referred to general surgery with a 6-week history of dull nonradiating low back pain worsened by ambulation. He had no paresthesia, sphincteric, or motor dysfunction.

He had experienced significant weight loss and progressive abdominal swelling in the preceding 10 months on account of which he had exploratory

**Address for correspondence:** Dr. Olalekan John Adepoju, Department of Surgery, University College Hospital, Ibadan, Nigeria.  
E-mail: olajohnadepoju@gmail.com

This is an open access journal, and articles are distributed under the terms of the Creative Commons Attribution-NonCommercial-ShareAlike 4.0 License, which allows others to remix, tweak, and build upon the work non-commercially, as long as appropriate credit is given and the new creations are licensed under the identical terms.

**For reprints contact:** WKHLRPMedknow\_reprints@wolterskluwer.com

**How to cite this article:** Adepoju OJ, Nweke MC, Soneye OY, Okolo CA, Fakoya AJ. Unilateral hypoplastic pelvic ectopic kidney presenting as a cold abscess: A case report. Niger J Surg 2021;27:55-8.

Access this article online	
<b>Quick Response Code:</b> 	<b>Website:</b> <a href="http://www.nigerianjsurg.com">www.nigerianjsurg.com</a>
	<b>DOI:</b> 10.4103/njs.NJS_27_19

laparotomy at a peripheral hospital. Neither details of surgery nor histology report was available. However, abdominal swelling recurred a few months after the operation. He was a hypertensive diabetic with optimal glycemic and blood pressure control. He had no fever.

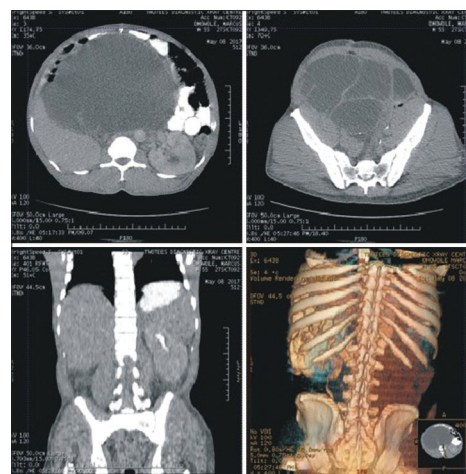
Physical examination revealed pallor, asthenia, multiple enlarged inguinal lymph nodes, midline abdominal scar, and a huge nontender, firm, nonpulsatile, bosselated intra-abdominal mass measuring about 32 cm × 28 cm, occupying the abdominal cavity sparing only the left iliac fossa. Digital rectal examination was unremarkable. A clinical diagnosis of visceral soft-tissue sarcoma was made.

Abdominopelvic ultrasonography showed a huge extensive thick-walled multiseptate cystic mass with cascading low-level internal echoes seen extending from the epigastric to the suprapubic area. The left kidney was normal in position, outline, and echogenicity, but the right kidney was not visualized. Baseline complete blood count showed anemia (hematocrit – 29.4%), normal total leukocyte count ( $6.61 \times 10^9/L$ ) with relative neutrophilia (73.4%), and monocytosis (10.9%). Serum electrolytes, urea, and creatinine were normal; serum carcinoembryonic antigen was within normal limits (2.2 ng/ml [0–3]), erythrocyte sedimentation rate (ESR) was raised (120 mm/h, Westergren method); inguinal lymph node biopsy for histology was reported to be reactive; ultrasound-guided aspiration, which yielded pus was negative for acid-fast bacillus (Ziehl–Neelsen and GeneXpert) and sterile on culture. Aspirate cytology was in keeping with suppurative inflammation. Retroviral screening with Determine<sup>®</sup> was nonreactive.

Contrast-enhanced computed tomography (CT) scan of the abdomen shows a normally sited left kidney and an abdominal mass with isodense septations separating hypodense areas [Figure 1].

A percutaneous celiostomy with a Foley's catheter drained about 7 L of pus over a 4-day period. At laparotomy, findings included copious purulent material and multiple dense interloop small bowel adhesions. A pelvic mass, extending to the right lumbar area (inside which the balloon of the Foley's catheter was seen); the superior pole of which was directly connected to the right renal vessels and ureter was seen. The mass was excised, and primary wound closure was done [Figure 2]. The patient did well postoperatively and was discharged home on the 7<sup>th</sup> postoperative day, has been followed up at the surgical outpatient clinic for 8 months with normal serum electrolytes and urea, and he is back to his pre-morbid health status.

Histology of the nephrectomy specimen shows marked



**Figure 1:** Computerized tomogram of the abdomen showing a normally sited left kidney and an abdominal mass with isodense septations separating hypodense areas

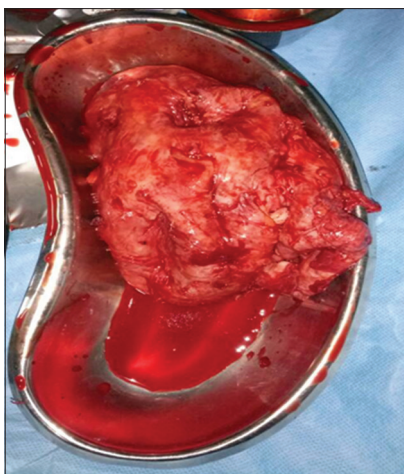
architectural distortion and replacement of kidney parenchyma by predominantly fibrous tissue, with only a small island of normal renal glomeruli and tubule were seen [Figure 3]. Micrographs obtained show dilated renal tubular lining forming cystic cavities containing eosinophilic secretions. The supporting fibrocollagenous stroma of the interstitium shows moderate infiltration by lymphocytes and plasma cells. A few of the tubules show thyroidization in keeping with chronic pyelonephritis [Figure 3a and 3b]. Micrograph [Figure 3c] shows extensive areas of fibrosis within the supporting stroma of the renal tissue, while micrograph [Figure 3d] shows areas of cyst formation containing eosinophilic secretions within the renal tissue bordered predominantly by fibrocollagenous stroma. No focus of malignant change was seen.

## DISCUSSION

A cold abscess is a defined collection of purulent exudates devoid of the cardinal signs of inflammation and the Gram stain of which yields leukocytes, but no bacteria.<sup>[7]</sup> Pyogenic bacteria are known causes, but tuberculosis, actinomycosis, and fungal infections are typically responsible.<sup>[8]</sup>

The clinical presentation of the index patient had led to a misdiagnosis of a mitotic lesion – weight loss, progressive abdominal swelling which recurred after surgery, low back pain, pallor, asthenia, inguinal lymphadenopathy, finding of a firm nontender abdominal mass, and absence of fever. He had neither voiding or storage urinary symptoms as the infection was confined to the upper tract.<sup>[5]</sup>

Even though minimal renal abscesses are known to resolve with antibiotics, a sterile abscess may persist following antibiotic therapy,<sup>[5,7]</sup> in which tell-tale



**Figure 2:** Excised mass

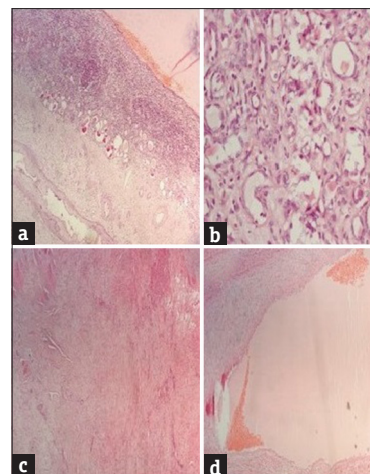
features of suppuration may be absent, as is in this case. However, cold abscesses from pyogenic organisms have been reported in otherwise immunocompetent hosts.<sup>[8]</sup>

Suboptimal glycemic control in a diabetic is known to constitute an immunocompromised state, thus increasing the risk of pyogenic infections. Before the onset of the illness, the glycemic profile of the patient was not available, but blood sugar readings were satisfactory at presentation and in the course of admission, with good control achieved with metformin and glibenclamide.

It would not be surprising that the patient had normal white cell count, since cold abscesses elicit very little or no systemic inflammatory response.<sup>[8]</sup> Furthermore, the relative neutrophilia was not alarming. The ESR was in keeping with an inflammatory condition while the reactive lymph node histology as well as the negative AFB workup made abdominal tuberculosis unlikely.

Needle aspiration for diagnostic purpose or percutaneous abscess drainage is undertaken with fluoroscopy, CT, or more-readily-available USS guidance, especially for unilocular collections.<sup>[7]</sup> Renal/perinephric abscesses may be amenable to percutaneous drainage, but some require surgical drainage or nephrectomy.<sup>[6,9]</sup> In a series, proportion of renal/perinephric abscesses amenable to percutaneous drainage, surgical drainage, and nephrectomy were 37.5%, 18.75%, and 37.5%, respectively.<sup>[7]</sup> In this case, pus drained unabated percutaneously for 4 days; however, it was unlikely such multiloculated purulence would have been effectively drained through a tube. The operation carried out prior referral was probably surgical drainage, with attendant recurrence. Complete excision of the abscess cavity necessitated a nephrectomy in the index case.

Although rare, a retroperitoneal sterile abscess should be kept in mind as a differential diagnosis of a recurrent



**Figure 3:** Photomicrographs from histology of the specimen. A few of the tubules show tyroidization in keeping with chronic pyelonephritis (a and b). Micrograph (c) shows extensive areas of fibrosis within the supporting stroma of the renal tissue, while micrograph (d) shows areas of cyst formation containing eosinophilic secretions within the renal tissue bordered predominantly by fibrocollagenous stroma

painless abdominal swelling, especially in patients referred to the tertiary center from peripheral hospitals where they have been hospitalized and have had generous antibiotic therapy.<sup>[7]</sup>

#### Declaration of patient consent

The authors certify that they have obtained all appropriate patient consent forms. In the form the patient(s) has/have given his/her/their consent for his/her/their images and other clinical information to be reported in the journal. The patients understand that their names and initials will not be published and due efforts will be made to conceal their identity, but anonymity cannot be guaranteed.

#### Financial support and sponsorship

Nil.

#### Conflicts of interest

There are no conflicts of interest.

#### REFERENCES

- Lossius MN, Araya CE, Henry DD, Neiberger RE. A patient with an unusual cause right lower quadrant pain and vomiting: Pyelonephritis of an ectopic right kidney masquerading as acute appendicitis. *Case Rep Med* 2009;2009:638501.
- Tsao YT, Lin SH, Lin YF, Chu P. Pelvic ectopic kidney with acute pyelonephritis: Wolf in sheep's clothing. *Am J Emerg Med* 2008;26:517.e3-4.
- Cinman NM, Okeke Z, Smith AD. Reviews in endourology pelvic kidney: Associated diseases and treatment. *J Endourol* 2007;21:836-42.
- Cheng Y, Lin H, Wu C. Acute pyelonephritis of an ectopic kidney mimicking acute appendicitis: Two unusual cases in an emergency department case reports. *Tzu Chi Med J* 2009;21:70-2.
- Doolittle KH, Taylor JN. Renal abscess in the differential

- diagnosis of mass in the kidney. *J Urol* 1963;89:649-51.
6. Coelho RF, Schneider-Monteiro ED, Mesquita JL, Mazzucchi E, Marmo Lucon A, Srougi M. Renal and perinephric abscesses: Analysis of 65 consecutive cases. *World J Surg* 2007;31:431-6.
  7. vanSonnenberg E, Wittich GR, Goodacre BW, Casola G, D'Agostino HB. Percutaneous abscess drainage: Update. *World J Surg* 2001;25:362-9.
  8. Das SK, Das A, Dey S. A rare case of staphylococcal cold abscess of anterior chest wall in an immunocompetent adult. *Ann Trop Med Public Heal* 2012;5:142-5.
  9. Wippermann CF, Schofer O, Beetz R, Schumacher R, Schweden F, Riedmiller H, *et al.* Renal abscess in childhood. Diagnostic and therapeutic progress. *Pediatr Infect Dis J* 1991;10:446-50. Doi: 10.1097/00006454-199106000-00006.