

Original Article

Management of Thyroglossal Cyst in Adults: A Single-Institution Experience

Chinedu Udochukwu Ndegbu¹, Olalekan Olasehinde^{1,2}, Adekunle Adeyemo^{3,4}, Olusegun I. Alatise^{1,2}, Yemisi B. Amusa^{3,4}

¹Department of Surgery, Obafemi Awolowo University Teaching Hospitals Complex, Ile-Ife, Nigeria, ²Department of Surgery, Obafemi Awolowo University, Ile-Ife, Nigeria, ³Department of Otorhinolaryngology, Obafemi Awolowo University, Ile-Ife, Nigeria, ⁴Department of Otorhinolaryngology, Obafemi Awolowo University Teaching Hospitals Complex, Ile-Ife, Nigeria

Submitted: 08-Mar-2020
Revised : 05-May-2020
Accepted : 01-Jun-2020
Published : 09-Mar-2021

INTRODUCTION

Thyroglossal duct cyst (TDC) is the most common congenital midline swelling of the neck arising from a persistent embryonic thyroglossal duct.^[1] Being a congenital anomaly, it is most commonly seen in children with only few cases seen in adults. Majority of data on the subject, therefore, focus on the management of the condition in children.^[2,3]

Sistrunk operation is recognized as the standard operation for the management of TDC globally.^[4] The procedure involves excision of the cyst, central portion of the hyoid bone, and the tract up to the foramen cecum. This is based on the knowledge of the natural course of the embryonic thyroglossal duct and its relationship with the hyoid bone.

Most of the experiences available on the management of thyroglossal cyst in children show very good outcomes

ABSTRACT

Objectives: Thyroglossal duct cyst (TDC) is the most common congenital anterior neck mass in clinical practice. Due to its congenital origin, presentation in adulthood is uncommon with only 7% of cases presenting in this age group. Data are therefore limited on the management of TDC in adults, particularly in Sub-Saharan Africa. This study describes the pattern of the presentation and treatment outcomes, following the management of TDC in a series of adults in a Nigerian tertiary hospital. **Subjects and Methods:** A retrospective review of all adult patients with TDCs over a 5-year period was carried out. Sociodemographic data, operative details, and postoperative outcomes were obtained and presented as descriptive statistics. **Results:** Seven adult patients, including five males and two females, were managed during the period. Their ages ranged from 19 to 60 years, with a mean of 37 ± 16.4 years. All the patients presented with anterior neck swellings which had been present for a median duration of 3 years. Cysts were located in the infrahyoid position in all instances, and all had Sistrunk operation over a mean operative time of 78 ± 16 min. There were no intraoperative complications. The mean duration of the postoperative stay was 2 days. There was no recurrence after a median follow-up period of 15 months. **Conclusion:** This study highlights the rarity of TDC in adults and describes a single institution's experience with the management of adult cases of TDC using the classical Sistrunk operation.

KEYWORDS: Adult, Sistrunk procedure, thyroglossal duct, thyroglossal duct cyst

following the Sistrunk procedure. Due to the rarity of this condition in adults, there are few reports on the management of TDC in adults. In a series of seven cases managed over a 5-year period, we describe our experience with the management of TDC in adults in a Nigerian tertiary hospital.

SUBJECTS AND METHODS

A retrospective review of adult cases (18 years and older) of TDC managed between January 2015 and January 2020 was performed. Details of their sociodemographic data (age, gender, occupation, and

Address for correspondence: Dr. Chinedu Udochukwu Ndegbu, Department of Surgery, Obafemi Awolowo University Teaching Hospitals Complex, Ile-ife, Nigeria.
E-mail: drndegbuchinedu@gmail.com

This is an open access journal, and articles are distributed under the terms of the Creative Commons Attribution-NonCommercial-ShareAlike 4.0 License, which allows others to remix, tweak, and build upon the work non-commercially, as long as appropriate credit is given and the new creations are licensed under the identical terms.

For reprints contact: WKHLRPMedknow_reprints@wolterskluwer.com

How to cite this article: Ndegbu CU, Olasehinde O, Adeyemo A, Alatise OI, Amusa YB. Management of thyroglossal cyst in adults: A single-institution experience. Niger J Surg 2021;27:38-41.

Access this article online	
Quick Response Code: 	Website: www.nigerianjsurg.com
	DOI: 10.4103/njs.NJS_25_20

level of education), clinical characteristics (duration of symptoms, presenting complaints, and associated symptoms), diagnostic workup (radiological and biochemical investigations), operative data (cadre of the surgeon, operative findings, surgical technique, and duration of the surgery), and postoperative outcome and histopathology were obtained. Data were analyzed using IBM SPSS version 21 and presented as descriptive statistics. Continuous variables were depicted as means and medians, while categorical variables were expressed as counts or frequencies.

RESULTS

There were seven adult patients managed for thyroglossal cyst over the period. There were five males and two females. Their ages range from 19 to 60 years with a median age of 38 years, the youngest being a 19-year-old female and the eldest a 60-year-old male.

All the patients presented with anterior neck swelling which had been noticed for a median duration of 3 years (range 3 weeks to 33 years). The mean size at presentation was 6.2 ± 2.6 cm (3.2–10.4 cm). Anterior neck swelling was the sole complaint in all but one patient who presented with pain and odynophagia as associated symptoms. The most common reason for seeking medical attention was a recent increase in the size of the lesion seen in four cases.

Regarding radiological workup, six patients had preoperative neck ultrasound. The predominant finding at ultrasound was that of hypoechoic cystic lesion in the anterior midline of the neck. Normal appearance and location of the thyroid gland lobes were documented for all the patients who had neck ultrasound done. Similarly, all patients had thyroid function test (TSH, T3, and T4) and were confirmed biochemically euthyroid. None of the patients had preoperative fine-needle aspiration cytology (FNAC) done.

The operations were carried out by consultant surgeons in all cases. All the cysts were located in the infrahyoid position; six of them were located in the midline while one was also laterally deviated. Sistrunk operation which entailed cystectomy, midline hyoidectomy, and proximal tract excision was performed in all cases [Figure 1]. The mean duration of the surgery was 78 ± 16 min. Two patients in the series had drain placement on account of extensive dissection owing to the size of the cysts, and drains were removed on the 2nd postoperative day. The mean \pm standard deviation duration of hospital stay was 2 ± 0.8 days. No recurrence was recorded at a median follow-up period of 15 months (range 2-54 months).

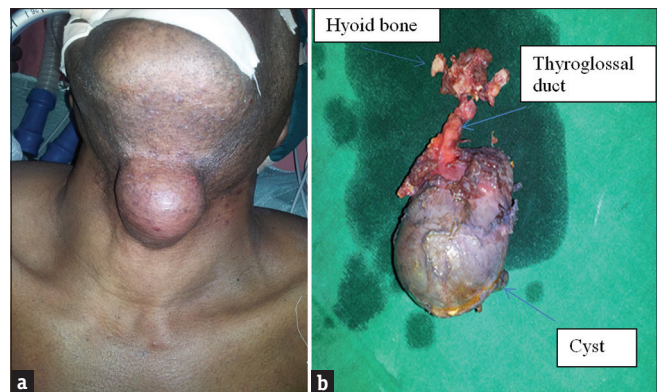


Figure 1: (a) Clinical picture of a 60-year-old male with thyroglossal duct cyst taken after induction of anesthesia. (b) Specimen of the Sistrunk procedure performed for the same patient demonstrating a thyroglossal duct tract terminating in a cyst distally, while the excised central hyoid bone is seen proximally

DISCUSSION

The rarity of TDCs in adults is the reason for the paucity of data on the subject in the adult population. Available data on adult presentation of the thyroglossal cyst in Nigeria are largely limited to isolated reports of one or two cases. This series, though limited to seven cases which further attests to the rarity of the condition, further enriches literature on the subject given the slightly higher number of cases than has been previously reported. The paucity of data on the subject and the limited number of cases presented in this series are indeed a testimony to the rarity of this pathology in adults.

The majority of patients in this series were males. This being a review of few cases, it is difficult to make definite assertions regarding gender distribution. Reports in the literature have, however, remained discordant with some reporting equal distribution,^[5-7] while others suggest male or female preponderance.^[8-10]

Painless anterior neck mass is recognized as the most frequent presentation of TDC in adult patients. The presence of other symptoms such as pain, odynophagia, dysphagia, and dyspnoea often indicates the presence of complications such as abscess formation.^[6,10] Only one of the six patients in this study presented with such symptoms. Most patients in this series rather presented with long-standing painless anterior neck masses, with the majority presenting due to an increase in the size of the mass. The mean size of 6.2 cm reported in our series is slightly higher than what has been reported in Caucasians (1–4 cm, an average of 2.5 cm)^[3] but similar to the findings from other parts of Sub-Saharan Africa (SSA).^[11] This may be attributed to the delayed presentation which is typical of many parts of SSA.

The location of TDC in the neck and its relation to the hyoid bone is variable. While midline position is the

dominant location in both children and adults, the lateral deviation has been associated with adult presentation.^[6,10] In relation to the hyoid bone, cysts may be located above, over, or below the hyoid. In the literature, infrahyoid cysts are generally the most common. This has also been reported for adult patients presenting with TDC.^[9,10] All the patients in this series had infrahyoid cysts.

The surgical management of TDC has evolved over time. With earlier treatment options, such as incision and drainage or simple excision associated with an unacceptable high recurrence rates, Schlange in 1893 suggested excision of the cyst and mid-portion of the hyoid bone while omitting the proximal tract – a technique with a reported recurrence rate of up to 30%.^[6] It was not until 1920 that Walter Ellis Sistrunk reported the classical Sistrunk procedure which significantly improved postoperative outcomes^[6] and has since remained the gold standard to date.^[3,5,12] All the patients in this series had Sistrunk operation with excellent outcomes attesting to its efficacy. Recent approaches to TDC surgery such as robot-assisted or endoscope-assisted transoral, retroauricular, and axillary approaches have been described for adult patients.^[13-16] These approaches promise better cosmesis by avoiding anterior neck incision, but their efficacy compared to the traditional Sistrunk procedure remains a subject of further research.

Recurrence is by far the most important postoperative outcome following the Sistrunk procedure, with a reported rate of 3%–6%.^[5,6,17] This is often a result of technical failures such as incomplete excision of the duct or the presence of multiple ducts, which were unrecognized at the surgery.^[18] It has been suggested that most recurrences occur within the first 6 months after the surgery.^[10] Our patients were followed up for a median duration of 15 months during which no recurrence was found. Another possible complication is damage to the hypoglossal nerve. The close relationship between the hyoid bone and the hypoglossal nerve can potentially endanger the hypoglossal nerve during the excision of the mid-portion of the hyoid bone; it is avoidable by careful and meticulous dissection and preservation of the superior horn of the hyoid bone. This complication was not encountered in any of the patients in this series, further highlighting its safety in adult patients as reported in the pediatric age group.^[1,4]

TDCs are known to rarely harbor malignant focus. In <1% of cases, malignant cells, commonly from papillary thyroid carcinoma, may be found within the specimen.^[19,20] For this reason, preoperative FNAC has been advocated by some to rule out papillary carcinoma

and to determine the appropriate surgical treatment to be offered.^[20,21] Some authors have, however, highlighted the limitation of FNAC in satisfactorily determining the presence or absence of malignancy, especially since most occult malignancies are detected after definitive pathologic examination of the excised specimen.^[20] More so, other histopathological forms of carcinoma may arise within the cyst.^[22] Based on the absence of evidence-based practice guidelines, none of our patients had preoperative FNAC. None of the patients in this series had any occult malignancy reported from the histopathological evaluation of the excised cysts. It is noteworthy however that one of the resected specimens contained few areas of underlining thyroid follicles. This finding is not surprising given the reports of ectopic thyroid tissue in up to 60% of TDCs.^[20]

Besides being a rare site for malignant focus, TDCs are the second-most common site for ectopic thyroid tissue after lingual thyroid.^[23] Most ectopic thyroid tissue within TDCs presents in conjunction with a normally located and developed thyroid gland.^[24] The majority of these are often euthyroid, while about a third may be hypothyroid at presentation.^[25] This justifies the inclusion of routine thyroid ultrasound and thyroid function tests in the evaluation process.

The few number of cases in this series, though an improvement over earlier reports, limits the generalizability of our findings. For a condition this uncommon, a multi-institutional review may provide robust data for a more comprehensive overview.

CONCLUSION

This study highlights the rarity of TDC in adults and provides data on the pattern of presentation and the management of this condition in a Nigerian population. It also describes a single institution's experience with the management of TDC in adults using the classical Sistrunk operation.

Financial support and sponsorship

Self funded.

Conflicts of interest

There are no conflicts of interest.

REFERENCES

- Gioacchini FM, Alicandri-Ciufelli M, Kaleci S, Magliulo G, Presutti L, Re M. Clinical presentation and treatment outcomes of thyroglossal duct cysts: A systematic review. *Int J Oral Maxillofac Surg* 2015;44:119-26.
- Al-Thani H, El-Menyar A, Sulaiti MA, El-Mabrok J, Hajaji K, Elgohary H, *et al.* Presentation, management, and outcome of thyroglossal duct cysts in adult and pediatric populations: A 14-year single center experience. *Oman Med J* 2016;31:276-83.

3. Dedivitis RA, Camargo DL, Peixoto GL, Weissman L, Guimarães AV. Thyroglossal duct: A review of 55 cases. *J Am Coll Surg* 2002;194:274-7.
4. Anderson JL, Vu K, Haidar YM, Kuan EC, Tjoa T. Risks and complications of thyroglossal duct cyst removal. *Laryngoscope* 2020;130:381-4.
5. Lin ST, Tseng FY, Hsu CJ, Yeh TH, Chen YS. Thyroglossal duct cyst: A comparison between children and adults. *Am J Otolaryngol* 2008;29:83-7.
6. Brousseau VJ, Solares CA, Xu M, Krakovitz P, Koltai PJ. Thyroglossal duct cysts: Presentation and management in children versus adults. *Int J Pediatr Otorhinolaryngol* 2003;67:1285-90.
7. Allard RH. The thyroglossal cyst. *Head Neck Surg* 1982;5:134-46.
8. Hsieh YY, Hsueh S, Hsueh C, Lin JN, Luo CC, Lai JY, *et al.* Pathological analysis of congenital cervical cysts in children: 20 years of experience at Chang Gung Memorial Hospital. *Chang Gung Med J* 2003;26:107-13.
9. Türkyılmaz Z, Sönmez K, Karabulut R, Demirgöullari B, Sezer C, Basaklar AC, *et al.* Management of thyroglossal duct cysts in children. *Pediatr Int* 2004;46:77-80.
10. Zaman SU, Ikram M, Awan MS, Hassan NH. A decade of experience of management of thyroglossal duct cyst in a tertiary care hospital: Differentiation between children and adults. *Indian J Otolaryngol Head Neck Surg* 2017;69:97-101.
11. Aliyu D, Amutta BS, Abdullahi M, Many C, Solomon J, Abdullah K. Thyroglossal duct cyst in adult Nigerians: A report of two cases. *Orient J of Med* 2016;28:44-8.
12. Mohan PS, Chokshi RA, Moser RL, Razvi SA. Thyroglossal duct cysts: A consideration in adults. *Am Surg* 2005;71:508-11.
13. Kim CH, Byeon HK, Shin YS, Koh YW, Choi EC. Robot-assisted Sistrunk operation via a retroauricular approach for thyroglossal duct cyst. *Head Neck* 2014;36:456-8.
14. Lee DW, Tae K. Robot-assisted excision of thyroglossal duct cyst by a postauricular face lift approach. *Videosurgery MiniInv* 2020;15:245.
15. Paek SH, Choi JY, Lee KE, Youn YK. Bilateral axillo-breast approach (BABA) endoscopic Sistrunk operation in patients with thyroglossal duct cyst: Technical report of the novel endoscopic Sistrunk operation. *Surg Laparosc Endosc Percutan Tech* 2014;24:e95-8.
16. So YK, Jeong JI, Youm HY, Jeong HS. Endoscope-assisted intra-oral resection of the external thyroglossal duct cyst. *Am J Otolaryngol* 2011;32:71-4.
17. Yazdi AK, Sazgar AA, Noviri BB, Mahboubi H, Mojtahed M. The role of pre-operative infection in the recurrence of thyroglossal duct cyst. *B-ENT* 2011;7:169-71.
18. Hussain K, Henney S, Tzifa K. A ten-year experience of thyroglossal duct cyst surgery in children. *Eur Arch Otorhinolaryngol* 2013;270:2959-61.
19. Luna-Ortiz K, Hurtado-Lopez LM, Valderrama-Landaeta JL, Ruiz-Vega A. Thyroglossal duct cyst with papillary carcinoma: What must be done? *Thyroid* 2004;14:363-6.
20. Carter Y, Yeutter N, Mazeh H. Thyroglossal duct remnant carcinoma: Beyond the Sistrunk procedure. *Surg Oncol* 2014;23:161-6.
21. Plaza CP, López ME, Carrasco CE, Meseguer LM, Perucho Ade L. Management of well-differentiated thyroglossal remnant thyroid carcinoma: Time to close the debate? Report of five new cases and proposal of a definitive algorithm for treatment. *Ann Surg Oncol* 2006;13:745-52.
22. Deshpande A, Bobhate SK. Squamous cell carcinoma in thyroglossal duct cyst. *J Laryngol Otol* 1995;109:1001-4.
23. Lilley JS, Lomenick JP. Delayed diagnosis of hypothyroidism following excision of a thyroglossal duct cyst. *J Pediatr* 2013;162:427-8.
24. Massine RE, Durning SJ, Koroscil TM. Lingual thyroid carcinoma: A case report and review of the literature. *Thyroid* 2001;11:1191-6.
25. Radkowski D, Arnold J, Healy GB, McGill T, Treves ST, Paltiel H, *et al.* Thyroglossal duct remnants. Preoperative evaluation and management. *Arch Otolaryngol Head Neck Surg* 1991;117:1378-81.