

## Case Report

# Cavernous Hemangioma of the Adrenal Gland: A Rare Adrenal Incidentaloma

Amit Gupta<sup>1</sup>, Ashish Gupta<sup>1</sup>, Sweety Gupta<sup>2</sup>, Prashant Durgapal<sup>3</sup>, Rohik Anjum T Sideek<sup>1</sup>, Shashank Verma<sup>1</sup>

<sup>1</sup>Department of Surgery, AIIMS, Rishikesh, Uttarakhand, India,

<sup>2</sup>Department of Radiation Oncology, AIIMS, Rishikesh, Uttarakhand, India,

<sup>3</sup>Department of Pathology, AIIMS, Rishikesh, Uttarakhand, India

Submitted: 08-Mar-2019

Revised : 08-Apr-2019

Accepted : 17-May-2019

Published : 27-Jul-2020

ABSTRACT

Cavernous hemangiomas of the adrenal gland are rare, benign, endocrinologically inactive tumors. They present as adrenal incidentalomas, mostly asymptomatic, but patients may have abdominal pain. Surgery is the mainstay of treatment.

**KEYWORDS:** Adrenal, cavernous, hemangioma, incidentaloma

## INTRODUCTION

Cavernous hemangiomas of the adrenal gland are rare, benign, endocrinologically inactive tumors. Johnson and Jeppesen published the first report of adrenal hemangioma in 1955,<sup>[1]</sup> and today, there are about 90 cases documented in the literature. They present as adrenal incidentalomas, mostly asymptomatic, but patients may have abdominal pain. There have been rare cases of consumptive coagulopathy or hypovolemic shock due to hemorrhage in these hemangiomas.

## CASE REPORT

A 79-year-old male presented with a complaint of right flank pain, intermittent, dull aching, nonradiating, nonshifting, nonaggravating factor, relieved on oral medications, for 1 year. There was no history of fever, weakness, loss of weight or appetite, headaches, anxiety, palpitations, passage of red-colored urine or painful urination, jaundice, and altered bowel habits. On examination, his vital signs were stable, no lymphadenopathy was present, and abdomen was soft, nontender, and nondistended, no organomegaly was present, no palpable lump was present, digital rectal examination was normal, and systemic examination was within normal limits. Routine blood investigations were

within normal limits. Urine examination showed the presence of pus cells. Culture sensitivity was sterile after 24 h of aerobic incubation. Urinary metanephrine levels were normal.

Contrast computed tomographic scan revealed large circumferential, round, heterogeneous soft tissue attenuation retroperitoneal mass lesion in the region of the right adrenal gland with peripheral enhancement and central necrosis and punctate calcifications with washout of contrast [Figure 1]. Contrast-enhanced magnetic resonance imaging of the abdomen was suggestive of large heterogeneous mass with central necrosis in the right suprarenal region (6.7 cm ×6.9 cm), with peripheral enhancement. No fat component/hemorrhage and dilated vessels were seen in the mass. Inferior vena cava and renal vein were normal. Normal potassium levels and lack of hypertension ruled out aldosterone-secreting tumor. Normal levels of urinary metanephrine excluded pheochromocytoma. Right adrenalectomy was done and the specimen was sent for histopathological examination. Intraoperatively, an 8 cm ×7 cm mass

**Address for correspondence:** Dr. Amit Gupta,

Department of Surgery, 5<sup>th</sup> Floor Medical College Block, AIIMS, Rishikesh - 249 203, Uttarakhand, India.

E-mail: [dramit2411@gmail.com](mailto:dramit2411@gmail.com)

### Access this article online

#### Quick Response Code:



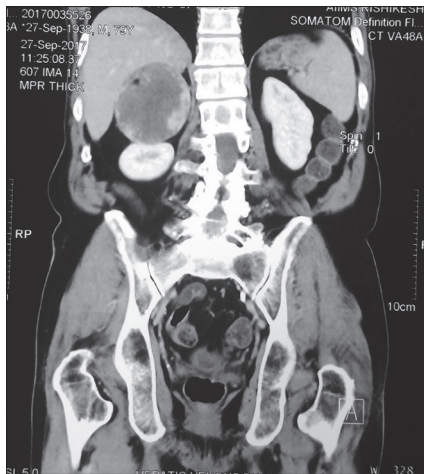
Website: [www.nigerianjsurg.com](http://www.nigerianjsurg.com)

DOI: 10.4103/njs.NJS\_12\_19


This is an open access journal, and articles are distributed under the terms of the Creative Commons Attribution-NonCommercial-ShareAlike 4.0 License, which allows others to remix, tweak, and build upon the work non-commercially, as long as appropriate credit is given and the new creations are licensed under the identical terms.

For reprints contact: [WKHLRPMedknow\\_reprints@wolterskluwer.com](mailto:WKHLRPMedknow_reprints@wolterskluwer.com)

**How to cite this article:** Gupta A, Gupta A, Gupta S, Durgapal P, Sideek RA, Verma S. Cavernous hemangioma of the adrenal gland: A rare adrenal incidentaloma. *Niger J Surg* 2020;26:159-61.



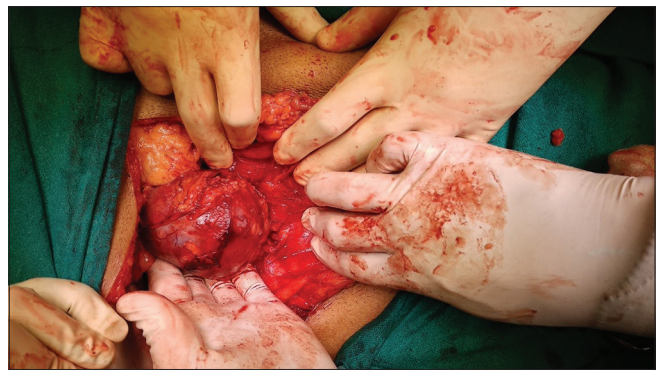**Figure 1:** Computed tomographic scan showing soft tissue attenuation mass lesion in retroperitoneum in the region of right adrenal gland with peripheral enhancement



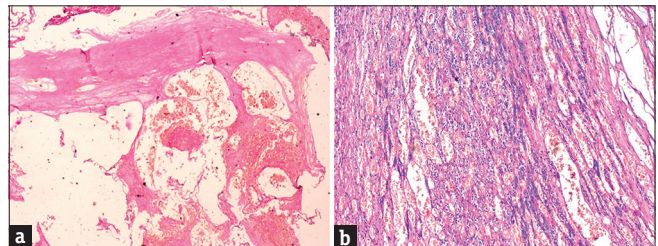
**Figure 3:** Grossly, an 8 cm × 7 cm × 3.5 cm globular mass, cut surface being brownish with hemorrhagic and cystic areas

was found in the right suprarenal region involving right adrenal gland [Figure 2]. No intra-abdominal metastases were noted and other organs were normal. Postoperative period was uneventful.

Grossly size of lesion was 8 cm × 7 cm × 3.5 cm globular with cut surface being brownish with hemorrhagic and cystic areas [Figure 3]. Microscopically the lesion was well capsulated with central necrosis, large area of hemorrhage and areas of hyalinization, Also variable sized blood vessels were visualized with fibrous septa and part of normal adrenocortical tissue was seen in periphery and was intersected by thin-walled capillaries [Figure 4]. Large area of hemorrhage and areas of hyalinization were seen. No atypia or mitoses in the endothelium were present. Hence, diagnosis of right adrenal cavernous hemangioma confirmed.



**Figure 2:** Mass in the right suprarenal region involving right adrenal gland



**Figure 4:** (a) Microscopic photograph showing large area of hemorrhage and areas of hyalinization and (b) microscopic examination showing variably sized blood vessels with fibrous septa

## DISCUSSION

Adrenal hemangiomas are rare. The first case of adrenal hemangioma was surgically removed in 1955. Etiology of these tumors is unknown, and mainly, these are congenital with the involvement of hereditary factors and ectasia of blood vessels.<sup>[2]</sup> They tend to be unilateral, with only two cases of bilateral cavernous hemangiomas of the adrenal gland reported in the literature. The size of the mass and functionality are the main considerations for further action. Imaging studies do help but are not enough to determine the likely nature of the mass as is the presence of hypertension, potassium levels, and urinary metanephrine. Presentation is usually nonspecific. Cortisol suppression tests and hormonal levels (especially for adrenocortical cancers) are necessary for diagnosis, preoperative preparation for surgery and for management postoperatively in the event of a functionally active mass. It is only at histology that the nature of the mass be determined. Ultrasonography is not considered helpful to differentiate it from other adrenal lesions. Radiological findings of adrenal hemangioma on CT scan include a heterogeneous, hypodense lesion with variable calcification due to phleboliths within the dilated vascular spaces of the lesion.<sup>[3]</sup> Mass size is the main surgical indication. Surgical removal is the mainstay of management. Resection is necessary for mass >6 cm due to risk of malignancy (35%–98%) and

propensity to bleed.<sup>[4]</sup> For sizes of 4–6 cm, functionality of tumor, history of extra-adrenal malignancy, patient's age, and physical condition are to be considered to take a decision. Treatment for smaller and asymptomatic cavernous hemangiomas is conservative with periodic follow-up.<sup>[5]</sup> Surgical resection is therefore required to exclude malignancy, relieve pressure-related symptoms, and prevent hemorrhage.<sup>[6]</sup> Since there are no or minimal symptoms suggestive of a particular cause or type, most cases are diagnosed postoperatively. There is a report of simultaneous existence with malignant adrenal hemangioendothelioma; hence, surgical resection is a must even when diagnosis is made. Immunohistochemical staining for CD31, CD34, and podoplanin/D2-40 confirms the diagnosis. There are still no optimal diagnostic or treatment guidelines.

## CONCLUSION

Although adrenal cavernous hemangiomas are rare, they should be considered as a part of the differential diagnosis of adrenal neoplasms. Mainstay of treatment is surgical excision due to the risk of spontaneous tumor rupture and difficulty of ruling out malignancy.

## Declaration of patient consent

The authors certify that they have obtained all appropriate patient consent forms. In the form the

patient(s) has/have given his/her/their consent for his/her/their images and other clinical information to be reported in the journal. The patients understand that their names and initials will not be published and due efforts will be made to conceal their identity, but anonymity cannot be guaranteed.

## Financial support and sponsorship

Nil.

## Conflicts of interest

There are no conflicts of interest.

## REFERENCES

1. Johnson CC, Jeppesen FB. Hemangioma of the adrenal. *J Urol* 1955;74:573-7.
2. Noh JJ, Choi SH, Hwang HK, Kang CM, Lee WJ. Adrenal cavernous hemangioma: A case report with review of the literature. *JOP* 2014;15:254-7.
3. Auh YH, Anand J, Zirinsky K, Kazam E. Adrenal hemangioma: A case report. *J Comput Tomogr* 1986;10:57-9.
4. Edwards JP, Stuart HC, Urbanski SJ, Pasiaka JL. A rare cavernous hemangioma of the adrenal gland. *Int J Surg Case Rep* 2014;5:52-5.
5. Agrusa A, Romano G, Salamone G, Orlando E, Di Buono G, Chianetta D, *et al.* Large cavernous hemangioma of the adrenal gland: Laparoscopic treatment. Report of a case. *Int J Surg Case Rep* 2015;16:150-3.
6. Tadić B, Grubor N, Milosavljević V, Matić S, Grubor N, Ignjatović I. Giant Cavernous Hemangioma of the Adrenal Gland: Case Report and Review of the Literature. *J Clin Case Rep* 2017;7:1063.