

## Original Article

# A Comparative Study of Fine-Needle Aspiration and Nonaspiration Cytology Diagnosis in Thyroid Lesions

Elangovan Archana<sup>1</sup>, Chellappa Vijayakumar<sup>1</sup>, Nagarajan Raj Kumar<sup>1</sup>, Gopal Balasubramanian<sup>1</sup>, Krishnamachari Srinivasan<sup>1</sup>, G. S. Sreenath<sup>1</sup>, N. Siddaraju<sup>2</sup>

<sup>1</sup>Department of Surgery, Jawaharlal Institute of Postgraduation Medical Education and Research, Puducherry, India,  
<sup>2</sup>Department of Pathology, Jawaharlal Institute of Postgraduation Medical Education and Research, Puducherry, India

Submitted: 21-Mar-2020  
Revised : 06-May-2020  
Accepted : 11-May-2020  
Published : 27-Jul-2020

## INTRODUCTION

Fine-needle aspiration cytology (FNAC) is one of the first-line diagnostic tests in the evaluation of thyroid malignancies.<sup>[1]</sup> Application of suction in a highly vascular organ like thyroid leads to an increase in hemorrhagic smears and an increase in cell trauma.<sup>[2]</sup> Hence, it often results in nondiagnostic or indeterminate smears, leading to the repetition of smears, thus causing a delay in diagnosis and treatment. To overcome these difficulties, fine-needle nonaspiration cytology (FNNAC) was introduced, wherein suction pressure was not applied. Capillary action draws the cells into the hub

### ABSTRACT

**Background:** Aspiration cytology is one of the first-line diagnostic tests in thyroid malignancies. Fine-needle aspiration cytology (FNAC) in thyroid lesions causes hemorrhagic smear and cell trauma, often leading to the repetition of smear and delay in diagnosis. This study was conducted to identify the diagnostically superior technique with regard to thyroid swelling and to assess the quality of smears obtained from FNAC and fine-needle nonaspiration cytology (FNNAC). **Methodology:** This was a prospective diagnostic study carried out for 2 years in a tertiary care center from South India. All patients with complaints of thyroid swellings, after examination, underwent FNNAC, followed by FNAC of the lesion. They underwent thyroidectomy when indicated. The final postoperative biopsy reports were compared with the preoperative reports of these two techniques (FNNAC and FNAC). The quality of smears was compared using Mair's score. **Results:** The sensitivity, specificity, positive predictive value, negative predictive value, and accuracy in diagnosing malignancy were 93.4%, 100%, 100%, 98.78%, and 98.96% for FNNAC and 94.12%, 100%, 100%, 98.82%, and 99% for FNAC, respectively, which were comparable. Regarding the quality of smears, FNNAC had more smears with less blood in the background. FNAC had more smears with adequate cellularity. The difference in overall Mair's score between the two techniques was not significant ( $P = 0.28$ ). **Conclusion:** No difference was found in the accuracy of FNAC and FNNAC in diagnosing thyroid lesions. Furthermore, the smear quality of both techniques was comparable. Hence, either can be used based on the operator's preference and experience.

**KEYWORDS:** *Aspiration cytology, fine-needle aspiration cytology, Mair's score, nonaspiration, thyroid carcinoma*

of the needle, which is then smeared onto a slide and studied. Many studies were conducted comparing both techniques in various organs. Few studies favored FNNAC, and few studies concluded that the techniques were comparable.<sup>[1-3]</sup> This study was done to compare the efficacy of FNAC and FNNAC with respect to thyroid malignancies and also the quality of the smears.

**Address for correspondence:** Dr. Gopal Balasubramanian, Department of Surgery, Jawaharlal Institute of Postgraduation Medical Education and Research, Puducherry - 605 006, India.  
E-mail: drbala18@gmail.com

This is an open access journal, and articles are distributed under the terms of the Creative Commons Attribution-NonCommercial-ShareAlike 4.0 License, which allows others to remix, tweak, and build upon the work non-commercially, as long as appropriate credit is given and the new creations are licensed under the identical terms.

For reprints contact: WKHLRPMedknow\_reprints@wolterskluwer.com

**How to cite this article:** Archana E, Vijayakumar C, Raj Kumar NR, Balasubramanian G, Srinivasan K, Sreenath GS, et al. A comparative study of fine-needle aspiration and nonaspiration cytology diagnosis in thyroid lesions. *Niger J Surg* 2020;26:147-52.

Access this article online	
Quick Response Code: 	Website: <a href="http://www.nigerianjsurg.com">www.nigerianjsurg.com</a>
	DOI: 10.4103/njs.NJS_29_20

## METHODOLOGY

This was a prospective study done in a tertiary care center from South India for 2 years. The Institute Human Ethics Committee approval was obtained. All patients presenting to the general surgery outpatient department with complaints of thyroid swelling and age more than 18 years were included in the study after obtaining written consent. A thorough history was taken, and physical examination was done. Thyroid function tests and an ultrasound scan of the neck were done, followed by the cytodiagnostic study. If the patient had hyperthyroidism, FNAC and FNNAC were done after the treatment of hyperthyroidism.

The participants were made to lie supine with a wedge placed between the shoulder blades to extend the neck. The thyroid region was cleaned with spirit and let to air dry. The swelling was fixed with left hand and FNNAC was performed with a 23 G needle held between the forefinger and thumb of the right hand. The needle was inserted and multiple passages in different direction were done. The materials collected in the hub of the needle were expressed onto a slide and immediately fixed with Giemsa and Pap stain. FNAC was then performed similarly except that suction was applied with a 10-ml syringe attached to the needle on entering the swelling. Nonaspiration cytology was always performed first, followed by aspiration cytology. The slides were randomly labeled as A and B to blind the interpreting cytologist. The patients were worked up by the corresponding units in surgery and underwent thyroidectomy when indicated. The patients who did not undergo thyroidectomy were excluded from the analysis of the comparison of the accuracy of the techniques. However, they were included for comparison of Mair's scoring of the two techniques. The final histopathological reports of the operated patients were collated.

The smears were studied by the cytotechnologist and investigator. Cytotechnologists performed an initial and primary evaluation, and then, all the slides were referred to the investigator (cytopathologist) for final interpretation.

Based on Mair's total scores, the specimen was categorized as follows [Table 1]:<sup>[4]</sup>

1. Unsuitable for diagnosis (0–2)
2. Diagnostically adequate (3–6)
3. Diagnostically superior (7–10).

In the end, the following was noted.

- Diagnosis of both the A and B slides based on the Bethesda category
- Quality of the A and B slides based on Mair's scoring [Figures 1 and 2].

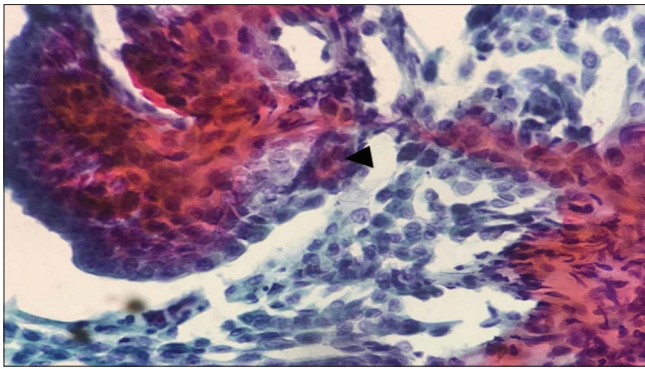
**Table 1: Mair's scoring system to classify the quality of cytological aspirate**

Criteria	Description	Score
Background blood or clot	Large amount	0
	Compromises diagnosis	
	Moderate amount	1
Amount of cellular material	Diagnosis possible	
	Minimal amount	2
	Diagnosis easy	
Degree of cellular degeneration	Minimal to absent	0
	Diagnosis not possible	
	Moderate	1
	Sufficient for diagnosis	
Degree of cellular trauma	Abundant	2
	Diagnosis of simple	
	Marked	0
	Diagnosis impossible	
Retention of appropriate architecture	Moderate	1
	Diagnosis possible	
	Minimal	2
	Diagnosis of easy	
Retention of appropriate architecture	Marked	0
	Diagnosis not possible	
	Moderate	1
	Diagnosis possible	
	Minimal	2
Retention of appropriate architecture	Diagnosis obvious	
	Minimal	0
	Nondiagnostic	
	Moderate	1
	Some preservation of cell pattern	
Retention of appropriate architecture	Excellent	2
	Diagnosis obvious	

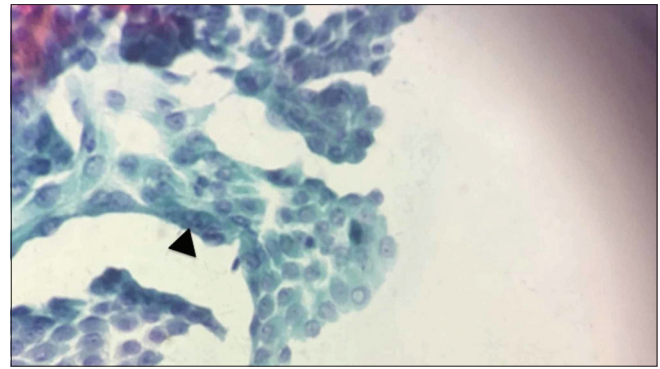
All the slides were reviewed again by the cytopathologist, and the reports were correlated with the final histopathological report.

### Statistical analysis

The data were entered in Redcap (version 6.11.1) and exported in Excel sheet, and SPSS software (IBM Corp. Released 2016. IBM SPSS Statistics for Windows, Version 24.0. Armonk, NY: IBM Corp) was used for analyzing the data. FNAC and FNNAC reports were compared with the histopathological diagnosis to determine the sensitivity, specificity, positive predictive value (PPV), and negative predictive value (NPV) in diagnosing malignancy. The quality of slides of both techniques was compared using Mair's scoring. Categorical variables such as FNNAC reports, FNAC reports, and Mair's scoring were calculated in terms of percentages. Pearson's



**Figure 1:** Fine-needle aspiration cytology smear from a case of conventional papillary thyroid carcinoma showing the well-preserved diagnostic papillary fragment with fibrovascular core (black arrowhead) (Pap,  $\times 400$ )



**Figure 2:** Nonaspiration smear of the same case showing classic intranuclear cytoplasmic inclusions, with well-preserved morphology (black arrowhead) (Pap,  $\times 400$ )

Chi-square test was used to determine the association of Mair's scoring with histopathological findings. Statistical significance was set at  $P < 0.05$ .

## RESULTS

A total of 125 patients who presented with thyroid swelling underwent both FNNAC and FNAC diagnostic tests. Among them, 104 patients were operated. Both FNAC and FNNAC details were taken into account for the diagnostic accuracy in malignancy specimens. Results of FNAC, FNNAC, and final biopsy reports were compared among the study patients [Table 2].

All 125 cases who had both FNAC and FNNAC slides were included for comparison of Mair's scoring [Table 3].

### Precise diagnosis of the nature of the lesion

FNAC and FNNAC reports were assessed in terms of the possibility of a precise diagnosis of the nature of the lesion. In this assessment, nondiagnostic and follicular neoplasm cases were taken as the absence of a precise diagnosis of the nature of the lesion. This was because the Bethesda-4 lesion does not explicitly confirm that such lesions are benign or malignant. Nondiagnostic cases required repeat cytology, as no opinion was possible on the same. Benign and malignant reports of FNNAC and FNAC were taken as a precise diagnosis of the nature of the lesion. Among FNNAC reports, seven reports (6.7%) did not give a precise diagnosis of the nature of the lesion. Among FNAC reports, in three cases (2.8%), a precise diagnosis of the nature of the lesion was not obtained.

### Mair's scoring

All the 125 slides prepared using both the techniques were compared in terms of each component of Mair's score and categorized [Tables 4 and 5].

The amount of background blood or clots was significantly less in FNNAC than FNAC. The amount

of cellular material was significantly more in FNAC than FNNAC. Among other parameters, no significant difference was found. This study had used a scoring method which was purely subjective analysis.

## DISCUSSION

In the present study, FNAC diagnosed more benign cases. Follicular neoplasm and nondiagnostic cases were more in FNNAC. Compared to nonaspiration cytology, follicular neoplasm and nondiagnostic cases were less in aspiration cytology (4.8% and 1.9% vs. 1.9% and 0.9%). This is similar to findings observed in studies conducted by Sinna and Ezzat, Kasper *et al.*, and Hirachand *et al.*<sup>[1-3]</sup> In a study conducted by Carvalho *et al.*, they found that FNAC and FNNAC provided similar cytological diagnosis, respectively (malignant: 3.8% vs. 3.8%,  $P = 0.871$ ; suspicious: 10.4% vs. 10.8%,  $P = 0.913$ ; and nondiagnostic: 10.0% vs. 11.2%,  $P = 0.598$ ).<sup>[5]</sup> However, as in our study, the follicular neoplasm and nondiagnostic cases were more in nonaspiration cytology than in aspiration cytology. In a study conducted by Hirachand *et al.*, the nondiagnostic smears were more (2.6%) in FNAC, but the percentage of colloid goiter (72.53%) and papillary carcinoma (4.76%) was similar to this study.<sup>[3]</sup>

The most common diagnosis in aspiration and nonaspiration cytology was colloid and nodular goiter (82% and 77%), respectively. The most common malignancy was papillary carcinoma. This is similar to the study conducted by Hirachand *et al.*, according to which the most common diagnosis in thyroid lesions was colloid goiter (72.53%) and the most common malignancy was papillary carcinoma (4.76%).<sup>[3]</sup>

### Nondiagnostic cases

Among the nondiagnostic cases in FNNAC, one was benign and another was malignant by FNAC. Nondiagnostic smear could be due to sampling from

**Table 2: Results of fine-needle aspiration cytology, fine-needle nonaspiration cytology, and final biopsy report among study patients**

Bethesda system		FNNAC		FNAC	
Category	Cytological diagnosis	Number of cases (n=125), n (%)	Operated cases with similar final report (n=104), n (%)	Number of cases (n=125), n (%)	Operated cases with similar final report (n=104), n (%)
1	Nondiagnostic/unsatisfactory	3	2 (1.9)	1	1 (0.9)
2	Benign-colloid/nodular goiter/lymphocytic/Hashimoto thyroiditis	100	82 (78.8)	103	85 (81.73)
3	Atypia/follicular lesion of undetermined significance	2	0	3	0
4	Follicular neoplasm	5	5 (4.8)	2	2 (1.9)
5	Suspicious for malignancy	5	5 (4.8)	6	6 (5.76)
6	Papillary carcinoma	8	8 (7.6)	8	8 (7.6)
	Medullary carcinoma	2	2 (1.9)	2	2 (1.9)

FNNAC: Fine-needle nonaspiration cytology, FNAC: Fine-needle aspiration cytology

**Table 3: Results showing the diagnostic accuracy of both final needle cytology tests**

Type	Sensitivity (%)	Specificity (%)	PPV (%)	NPV (%)	Accuracy (%)	FP (%)	FN (%)
FNNAC	93.75	100	100	98.78	98.96	0	1
FNAC	94.12	100	100	98.82	99	0	0.9

FNNAC: Fine-needle nonaspiration cytology, FNAC: Fine-needle aspiration cytology, PPV: Positive predictive value, NPV: Negative predictive value, FP: False positive, FN: False negative

**Table 4: Mair's score in fine-needle nonaspiration cytology and fine-needle aspiration cytology in study patients**

Mair's score	Background blood or clot, n (%)		Cellular material, n (%)		Cellular degeneration, n (%)		Cellular trauma, n (%)		Retention of appropriate architecture, n (%)	
	FNNAC	FNAC	FNNAC	FNAC	FNNAC	FNAC	FNNAC	FNAC	FNNAC	FNAC
Score 0	3 (2.4)	1 (0.8)	3 (2.4)	1 (0.8)	3 (2.4)	1 (0.8)	3 (2.4)	1 (0.8)	3 (2.4)	1 (0.8)
Score 1	17 (13.6)	39 (31.2)	46 (36.8)	19 (15.2)	12 (9.6)	9 (7.2)	22 (17.6)	21 (16.8)	0	0
Score 2	105 (84)	85 (68)	76 (60.8)	105 (84)	110 (88)	115 (92)	100 (80)	103 (82.4)	122 (97.6)	124 (99.2)
P	0.003		<0.001		0.4		0.627		0.622	

FNNAC: Fine-needle nonaspiration cytology, FNAC: Fine-needle aspiration cytology

a nonrepresentative area, or it could also result from a poor technique. To reduce the incidence of sampling from the nonrepresentative area, the technique could have been done under ultrasound (USG) guidance. If we had performed only FNNAC, a malignancy case could have been missed, or the surgery plan would have been delayed, as we had to repeat FNAC. In FNAC, one case was nondiagnostic which was follicular neoplasm by FNNAC. This was due to increased blood in the smear, which obscured the diagnosis.

### Follicular neoplasm cases

There were five cases diagnosed as follicular neoplasm by FNNAC. Among them, three cases were multinodular goiter, one was follicular adenoma, and one was follicular carcinoma by histology. Follicular carcinoma could not be diagnosed by cytology, as it needs the presence of capsular and vascular invasion, which can only be demonstrated in thyroidectomy specimens. Differentiating colloid goiter and follicular neoplasm

cytologically is often difficult. As we aspirate from the hypercellular areas at times, it leads to an overestimation of the diagnosis.<sup>[1]</sup> Again, this can be corrected by doing a USG-guided aspiration. Furthermore, multiple punctures can be done from various parts of the swelling. Aspiration cytology picks up colloid goiter more than nonaspiration cytology, as aspiration helps in sucking in colloid, which gets smeared liberally on the slide and helps in diagnosis. In FNAC, two cases were follicular neoplasm and the corresponding FNNAC reports were the same.

### False-positive and false-negative cases

The false-positive (FP) rate in the present study is 0%. Similar FP rates were obtained in the meta-analysis conducted by Gharib and Goellner which pooled data from seven series of similar studies in thyroid lesions.<sup>[6]</sup> In a study conducted by Sinna and Ezzat and Thanigaimai *et al.*, the false positive rate for aspiration cytology in thyroid lesions (7.2% and 66.6%) was

**Table 5: Mair's category in fine-needle nonaspiration cytology and fine-needle aspiration cytology in study patients**

Mair's category	FNNAC (%)	FNAC (%)
Unsuitable for diagnosis (0-2)	3 (2.4)	1 (0.8)
Diagnostically adequate (3-6)	2 (1.6)	1 (0.8)
Diagnostically superior (7-10)	120 (96)	123 (98.4)

FNNAC: Fine-needle nonaspiration cytology, FNAC: Fine-needle aspiration cytology

higher than the present study.<sup>[1,7]</sup> Zero FP was achieved because all the slides were reviewed by the experienced investigator and as such malignancy cases were also very less in this study.

The false-negative (FN) rate indicated benign cytology, which turns out to be malignant on histopathology. There was one FN case in both techniques. The FN rate was 1% in FNNAC and 0.9% in FNAC. In the case of lymphocytic thyroiditis, postsurgery was found to have lymphoma. The error was due to missing of lymphomatous focus while sampling. Again, a USG-guided FNAC/FNNAC would have helped to prevent the FN rate. Furthermore, in cases where there is suspicion of lymphoma, flow cytometry on the smears would have helped in diagnosis, without resorting to surgery.

Similar rates were obtained for aspiration cytology in thyroid lesions in studies conducted by Gharib and Goellner and Sinna and Ezzat.<sup>[1,6]</sup> In contrast to this study, the study conducted by Thanigaimai *et al.* found that the FN rate of aspiration cytology in thyroid lesions was higher than in the present study.<sup>[6]</sup> From the present study, it can be concluded that FP and FN rates were comparable in aspiration and nonaspiration cytology.

### Sensitivity and specificity

In a few studies like Sinna and Ezzat, indeterminate (Bethesda 3 and 4) and unsatisfactory smears were not included in the calculation of the efficacy of the technique.<sup>[1]</sup> However, in the study conducted by Kasper *et al.*, smears with indeterminate cells were included in the benign category and smears with suspicious for malignancy were included in the malignant category.<sup>[2]</sup> This leads to an underestimation of the accuracy of the technique. In the present study, follicular neoplasm and nondiagnostic cases were excluded from analysis for estimation of accuracy of the technique.

In this study, the specificity and PPV of FNNAC and FNAC are comparable (100%). The sensitivity and NPV varied marginally. A similar result was obtained in a study conducted by Rodrigues and Sindhu, wherein no difference was found in the diagnostic accuracy of the two techniques in thyroid lesions.<sup>[8]</sup>

This is, in contrast, to study conducted by Carvalho *et al.*, comparing FNAC and FNNAC among thyroid lesion in 58 patients who underwent surgery.<sup>[5]</sup> They found that the sensitivity of FNAC was less than FNNAC. However, there was no statistically significant difference, and they concluded that either test could be used based on the operator's preference and experience. In contrast to present study, Mahajan and Sharma *et al.*, concluded that FNAC had more diagnostic accuracy than FNNAC.<sup>[9]</sup>

### Mair's scoring

In this study, no significant difference was found between FNNAC and FNAC in terms of the quality of the slides. Similar to this study, the studies conducted by Maurya *et al.* and Carvalho *et al.* found that the quality of smears was slightly better in nonaspiration cytology compared to aspiration cytology, though there was no significant difference.<sup>[5,10]</sup> The study conducted by Mahajan and Sharma, comparing the two techniques in thyroid lesions, also found that there was no difference in the adequacy of the two techniques.<sup>[9]</sup> Also they concluded, FNNAC had significantly better retention of architecture and less blood clots in the background when compared to FNAC.<sup>[9]</sup>

In contrast to the present study, the study conducted by Ramachandra *et al.* found that FNNAC gives more diagnostically superior specimens.<sup>[11]</sup> They also found that the number of unsuitable smears was more in FNAC, whereas in this study, the number of unsuitable smears was more in FNNAC. Similarly, studies conducted by Storch *et al.* and Romitelli *et al.* also concluded that FNNAC gave more diagnostically superior results in contrast to this study, wherein there was no difference between the diagnostic superiority of FNNAC and FNAC.<sup>[12,13]</sup> Haddadi-Nezhad *et al.* found that the overall quality of smears was better in nonaspiration cytology than aspiration cytology in thyroid lesion with  $P < 0.001$ .<sup>[14]</sup>

The limitation of the present study was that it is a single-center study. Furthermore, all samples were collected by blind sampling. If sampling were done under USG guidance, the nondiagnostic and follicular neoplasm rate would have decreased. Accuracy was a high and perfect agreement between the two techniques while comparing FNNAC and FNAC in terms of the possibility of a precise diagnosis. Exclusion of follicular neoplasm and nondiagnostic cases shows a falsely high value of sensitivity, specificity, and accuracy.

### CONCLUSION

There was no difference found in the accuracy of FNAC and FNNAC in diagnosing thyroid lesions,

as sensitivity, specificity, PPV, NPV, and accuracy of both the techniques were comparable. Regarding the quality of smears, FNNAC had more cases with less blood in background paving the way for an adequate diagnosis than FNAC. FNAC had more cases with adequate cellularity than FNNAC. Among the rest of the parameters (cellular degeneration, cellular trauma, and retention of architecture), there was not much difference between the two techniques. No significant difference was found in the quality of smears of both the techniques.

#### Financial support and sponsorship

Nil.

#### Conflicts of interest

There are no conflicts of interest.

#### REFERENCES

1. Sinna EA, Ezzat N. Diagnostic accuracy of fine needle aspiration cytology in thyroid lesions. *J Egypt Natl Cancer Inst* 2012;24:63-70.
2. Kasper KA, Stewart J, Das K. Fine-needle aspiration cytology of thyroid nodules with hürthle cells: Cytomorphologic predictors for neoplasms, improving diagnostic accuracy and overcoming pitfalls. *Acta Cytologica* 2014;58:248-52.
3. Hirachand S, Maharjan M, Lakhey M, Thapa R, Kafle S. Accuracy of fine needle aspiration cytology in diagnosis of thyroid swelling. *J Pathol* 2013;3:433-36.
4. Mair S, Dunbar F, Becker PJ, Du Plessis W. Fine needle cytology-is aspiration suction necessary? A study of 100 masses in various sites. *Acta Cytol* 1989;33:809-13.
5. Carvalho GA de, Paz-Filho G, Cavalcanti TC, Graf H. Adequacy and diagnostic accuracy of aspiration vs. capillary fine needle thyroid biopsies. *Endocr Pathol* 2009;20:204-8.
6. Gharib H, Goellner JR. Fine-needle aspiration biopsy of the thyroid: An appraisal. *Ann Intern Med* 1993;118:282-9.
7. Thanigaimani D, Murali P. FNAC and cell block study in thyroid lesions. *Scholars J Appl Med Sci* 2016;4:2070-73.
8. Rodrigues W, Sindhu S. Diagnostic importance of fine needle non-aspiration and fine needle aspiration cytology in thyroid lesions. *Int J Sci Stud* 2017;4:18-21.
9. Mahajan P, Sharma PR. Fine-needle aspiration versus non aspiration technique of cytodiagnosis in thyroid lesions. *JK Sci* 2010;12:120-22.
10. Maurya AK, Mehta A, Mani NS, Nijhawan VS, Batra R. Comparison of aspiration vs non-aspiration techniques in fine-needle cytology of thyroid lesions. *J Cytol Indian Acad Cytol* 2010;27:51-4.
11. Ramachandra L, Kudva R, Rao BH, Agrawal S. A comparative study of fine needle aspiration cytology (FNAC) and fine needle non-aspiration cytology (FNNAC) technique in lesions of thyroid gland. *Indian J Surg* 2011;73:287-90.
12. Storch IM, Sussman DA, Jorda M, Ribeiro A. Evaluation of fine needle aspiration vs. fine needle capillary sampling on specimen quality and diagnostic accuracy in endoscopic ultrasound-guided biopsy. *Acta Cytol* 2007;51:837-42.
13. Romitelli F, Di Stasio E, Santoro C, Iozzino M, Orsini A, Cesareo R. A comparative study of fine needle aspiration and fine needle non-aspiration biopsy on suspected thyroid nodules. *Endocr Pathol* 2009;20:108-13.
14. Haddadi-Nezhad S, Larijani B, Tavangar SM, Nouraei SM. Comparison of fine-needle-nonaspiration with fine-needle-aspiration technique in the cytologic studies of thyroid nodules. *Endocr Pathol* 2003;14:369-73.