

## Case Report

# Resilient Customized Hollow Vaginal Stent for the Treatment of Vaginal Agenesis in Mayer–Rokitansky–Kuster–Hauser Syndrome

Manu Rathee<sup>1</sup>, Savita Rani Singhal<sup>2</sup>, Sanju Malik<sup>1</sup>, Gunjan Gupta<sup>1</sup>

<sup>1</sup>Department of Prosthodontics, Post Graduate Institute of Dental Sciences, Pt. B. D. Sharma University of Health Sciences, Rohtak, Haryana, India, <sup>2</sup>Department of Obstetrics and Gynaecology, Post Graduate Institute of Medical Sciences, Pt. B. D. Sharma University of Health Sciences, Rohtak, Haryana, India

Received : 01-11-2018  
Revision : 20-06-2019  
Accepted : 13-07-2019  
Published : 10-02-2020

### ABSTRACT

Vaginal agenesis is a common congenital anomaly in females and is most commonly associated with Mayer–Rokitansky–Kuster–Hauser (MRKH) syndrome. These patients can be treated with both surgical and nonsurgical procedures. Prefabricated as well as customized vaginal stents are used for the reconstruction and maintenance of neovagina. This case report explains the fabrication of customized tissue conditioner-reinforced acrylic vaginal stent for the treatment of a 20-year-old female having vaginal agenesis associated with MRKH syndrome. This vaginal stent with resilient surface provides a relatively easy, simple, and cost-effective alternative for the treatment of vaginal agenesis. It is also associated with increased compliance and comfort to the patient.

**KEYWORDS:** *Abbe–McIndoe operation, Mayer–Rokitansky–Kuster–Hauser syndrome, vaginal agenesis, vaginal stent*

## INTRODUCTION

The Mayer–Rokitansky–Kuster–Hauser (MRKH) syndrome is a congenital anomaly of female genital tract characterized by congenital aplasia of the uterus and upper part of the vagina in women, showing normal development of secondary sexual characteristics and a normal XX karyotype.<sup>[1]</sup> It is mainly sporadic; however, a subset of patients may have MRKH as an inherited disorder. It has autosomal dominant mode of inheritance with incomplete penetrance and variable expressivity.<sup>[2]</sup> One in every 4500 female births can suffer from this syndrome.<sup>[2]</sup> The etiology remains obscure although many genetic or environmental factors can be attributed as contributing factors.<sup>[3]</sup>

These patients are treated with surgical and nonsurgical procedures. Abbe–McIndoe operation is a common surgical and Franck’s dilator is a common nonsurgical method for the creation of neovagina.<sup>[4]</sup> This article presents the fabrication of a customized resilient acrylic stent for a young female patient with MRKH syndrome

treated surgically for creating a neovagina using amnion membrane over the stent as a graft for vaginoplasty.

## CASE REPORT

A 20-year-old unmarried female patient was referred to the Department of Prosthodontics, from the department of Gynaecology for the fabrication of vaginal stent. She gave a history of primary amenorrhea. On clinical examination, she had well-developed secondary sexual characteristics, class 5 as per Tanner staging. A simple blind vaginal depression was found. Sagittal view magnetic resonance imaging (MRI) revealed the absence of uterus and most part of the vagina. Axial images confirmed the presence of both the ovaries, absence of vaginal tissue, and unremarkable presence of left kidney. An intravenous urogram revealed

**Address for correspondence:** Dr. Sanju Malik, Department of Prosthodontics Post Graduate Institute of Dental Sciences, Pt. B. D. Sharma University of Health Sciences, Rohtak - 124 001, Haryana, India. E-mail: [smsanju2011@gmail.com](mailto:smsanju2011@gmail.com)

### Access this article online

#### Quick Response Code:



Website: [www.nigerianjsurg.com](http://www.nigerianjsurg.com)

DOI: 10.4103/njs.NJS\_43\_18

This is an open access journal, and articles are distributed under the terms of the Creative Commons Attribution-NonCommercial-ShareAlike 4.0 License, which allows others to remix, tweak, and build upon the work non-commercially, as long as appropriate credit is given and the new creations are licensed under the identical terms.

For reprints contact: [reprints@medknow.com](mailto:reprints@medknow.com)

**How to cite this article:** Rathee M, Singhal SR, Malik S, Gupta G. Resilient customized hollow vaginal stent for the treatment of vaginal agenesis in mayer–Rokitansky–Kuster–hauser syndrome. *Niger J Surg* 2020;26:88-91.

agenesis of the left kidney. No other abnormalities were identified. The patient was diagnosed as a case of MRKH syndrome.

Patient and family were counseled about the syndrome and associated problems. Detailed treatment plan including surgical treatment and intra- and post-operative vaginal stent usage was explained. The patient was informed that treatment will provide a better quality of life, and surrogacy options were also explained for future. Written consent was taken before the commencement of the treatment.

Surgical intervention for the patient was decided. A modified Abbe–McIndoe operation using a tissue conditioner-reinforced customized vaginal stent of suitable size was planned on the basis of thickness of intervening tissue between the perineum and pelvic peritoneum examined over a MRI scan.

### Fabrication of the vaginal stent

A tissue conditioner-reinforced hollow acrylic vaginal stent was planned for the patient with a dimension of 7.5 cm × 3.5 cm × 2.5 cm. Wax scaffolding of 15 mm was made over which a hard layer of 2-mm acrylic resin was adapted and was further relined by the resilient tissue conditioner by packing it in putty mold [Figure 1]. Technique for fabrication of vaginal stent is explained in the flowchart [Figure 2].

### Surgical procedure

Abbe–McIndoe procedure for the creation of neovagina was done after dissecting the fibroconnective tissues between bladder anteriorly and rectum posteriorly by progressively placing the dilators of increasing size. This was done for the depth up to 10 cm. Stent was prepared by immersing the amnion in saline treated with antibiotics and properly secured around the stent with chromic sutures [Figure 3].



Figure 1: Tissue conditioner-reinforced vaginal stent

After creating space and ensuring hemostasis, the amnion-covered stent was inserted in the newly created vagina. Labia minora were sutured together to keep the vaginal stent in position [Figure 4]. Postoperatively, the patient was managed by intravenous and oral fluids, antibiotics, and light diet for 3–4 days. Sutures were removed after 10 days. Mold was removed and neovagina was irrigated with povidine-iodine and saline. Acrylic stent was placed back for the maintenance of the cavity.

### Follow-up

The patient was trained to insert the mold herself and advised for its maintenance and regular use. The postoperative follow-up period was for 6 months. Patient’s compliance was satisfactory. During healing, minimal contracture of the neovaginal tissues was observed and the patient reported no discomfort. Hence, there was no need of replacing the stent with that of different size and the patient continued with the satisfactory use of same stent. Surgical intervention with customized vaginal stent resulted in satisfactory creation of neovagina.

### DISCUSSION

Young women being diagnosed with MRKH syndrome suffer from anxiety and psychological distress. Avaginosis poses many social, mental, and reproductive problems to an individual, and it is recommended that the patient and family must attend counseling before and throughout the treatment. Management of patients with MRKH syndrome

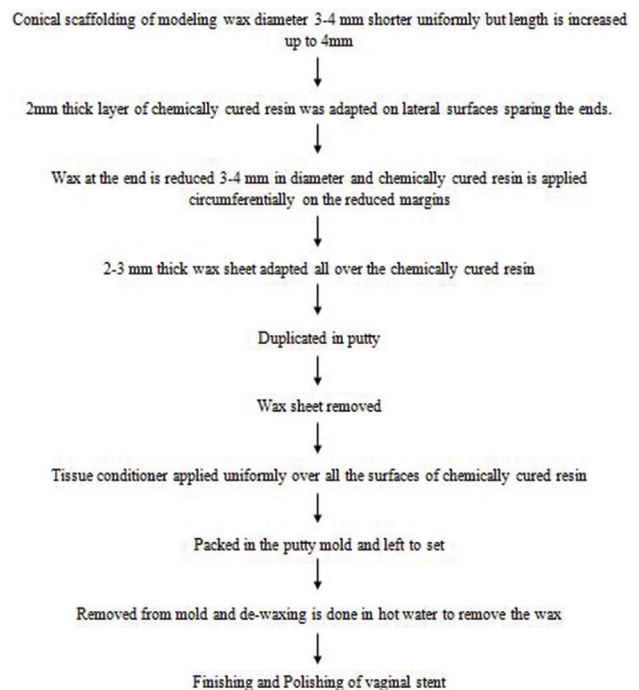
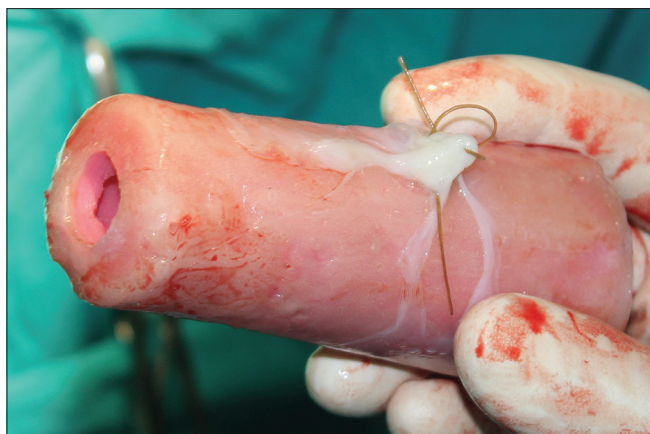

Figure 2: Flowchart elaborating laboratory steps of fabrication of a vaginal stent



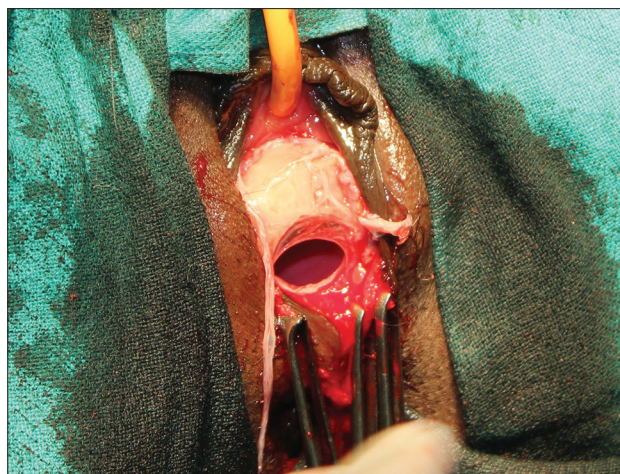
**Figure 3:** Hollow vaginal stent covered with amnion

is very debatable as the choice of the procedure for reconstruction of neovagina depends upon the anatomical, age, fertility potential, and social factors.<sup>[5]</sup>

The first clinical sign is generally primary amenorrhea in patients with normal female phenotype with normal functional ovaries.<sup>[3]</sup> External examination reveals the presence of normal secondary female sexual characteristics and normal external genitalia with vagina being reduced approximately to 2–7 cm deep vaginal dimple.<sup>[3,5]</sup> Anatomic examination is also important in the diagnosis of MRKH syndrome.

Vaginal stents are used for accomplishment of the tissue expansion and for the maintenance of vaginal depth and width to prevent the shrinkage and contraction of surgically created neovagina. Failure to wear the stent is one of the major reasons for the treatment failure.<sup>[4,6]</sup> Vaginal stents of increasing diameters are required during the healing period postsurgery. Several prefabricated stents of different designs are available. However, these are hard, costly, and only available in specific sizes and do not suit all the clinical situations.<sup>[7,8]</sup>

Customized stent offers a definite advantage over the prefabricated stent.<sup>[8,9]</sup> It provides a simple and economical alternative with adequate strength and durability. Furthermore, it permits the advantage of intraoperative modifications. The hollowed design of the customized vaginal stent permits the escape of the tissue fluids and other secretions.<sup>[8-10]</sup> The vaginal stent used in this clinical report uses a combination of materials of different consistencies. The use of inner hard acrylic resin core with overlying tissue conditioner counteracts disadvantages of both hard and soft stent by providing enough strength to the stent through the acrylic part to maintain the neovagina and enough cushioning effect from the outer layer of resilient tissue conditioner to make it comfortable for the patient.



**Figure 4:** McIndoe vaginoplasty with vaginal stent sutured in neocavity

## CONCLUSION

Vaginal stent is required for the success of surgical creation of neovagina, and a custom-made stent is definitely better because it can undergo size and surface modifications. Custom-designed vaginal stent may be fabricated by a prosthodontist on the advice of a gynecologist before the surgery. It is a very simple, relatively easy, cost-effective technique for the fabrication of vaginal stent, and it offers a convenient removable treatment option for maintaining the patency of the neovagina. The patient had good compliance and was comfortable with the use of tissue conditioner-reinforced vaginal stent.

## Declaration of patient consent

The authors certify that they have obtained all appropriate patient consent forms. In the form the patient(s) has/have given his/her/their consent for his/her/their images and other clinical information to be reported in the journal. The patients understand that their names and initials will not be published and due efforts will be made to conceal their identity, but anonymity cannot be guaranteed.

## Financial support and sponsorship

Nil.

## Conflicts of interest

There are no conflicts of interest.

## REFERENCES

1. Morcel K, Camborieux L, Programme de Recherches sur les Aplasies Müllériennes, Guerrier D. Mayer-Rokitansky-Küster-Hauser (MRKH) syndrome. *Orphanet J Rare Dis* 2007;2:13.
2. Guerrier D, Mouchel T, Pasquier L, Pellerin I. The Mayer-Rokitansky-Küster-Hauser syndrome (congenital absence of uterus and vagina) – Phenotypic manifestations and genetic approaches. *J Negat Results Biomed* 2006;5:11.

3. Folch M, Pigem I, Konje JC. Müllerian agenesis: Etiology, diagnosis, and management. *Obstet Gynecol Surv* 2000;55:644-9.
4. Klingele CJ, Gebhart JB, Croak AJ, DiMarco CS, Lesnick TG, Lee RA, *et al.* McIndoe procedure for vaginal agenesis: Long-term outcome and effect on quality of life. *Am J Obstet Gynecol* 2003;189:1569-72.
5. Edmonds DK. Congenital malformations of the genital tract and their management. *Best Pract Res Clin Obstet Gynaecol* 2003;17:19-40.
6. Adamson CD, Naik BJ, Lynch DJ. The vacuum expandable condom mold: A simple vaginal stent for McIndoe-style vaginoplasty. *Plast Reconstr Surg* 2004;113:664-6.
7. Barutçu A, Akgüner M. McIndoe vaginoplasty with the inflatable vaginal stent. *Ann Plast Surg* 1998;41:568-9.
8. Patnana AK, Chugh A, Chugh VK, Shekhar S. Simple and novel technique for fabrication of prosthetic vaginal dilators. *BMJ Case Rep* 2019;12. pii: e229524.
9. Rathee M, Boora P, Kundu R. Custom fabricated acrylic vaginal stent as an adjunct to surgical creation of neovagina for a young female with isolated vaginal agenesis. *J Hum Reprod Sci* 2014;7:272-5.
10. Ghanbari Z, Dahaghin M, Borna S. Long-term outcomes of vaginal reconstruction with and without amnion grafts. *Int J Gynaecol Obstet* 2006;92:163-4.