

Case Report

Laparoscopy-assisted Transanal Endorectal Pull-through for the Management of Hirschsprung's Disease in Nigeria: Report of Two Cases

Adesoji O Ademuyiwa¹, Olumide A Elebute¹, Olanrewaju S Balogun², Ibronke Desalu³, Lohfa B Chirdan⁴, Christopher O Bode¹

¹Department of Surgery, Paediatric Surgery Unit, College of Medicine, University of Lagos and Lagos University Teaching Hospital, Idi Araba, Lagos, Nigeria, ²Department of Surgery, General Surgery Unit (Minimal Access Surgery), College of Medicine, University of Lagos and Lagos University Teaching Hospital, Idi Araba, Lagos, Nigeria, ³Department of Anaesthesia, College of Medicine, University of Lagos and Lagos University Teaching Hospital, Idi Araba, Lagos, Nigeria, ⁴Department of Surgery, Division of Paediatric Surgery, University of Jos and Jos University Teaching Hospital, Jos, Plateau State, Nigeria

Received : 22-09-2018
Revision : 19-10-2018
Accepted : 18-11-2018
Published : 10-02-2020

ABSTRACT

Hirschsprung's disease is a relatively common disease in pediatric colorectal surgery. The treatment modalities have evolved from third-stage to single-stage in the past three decades. The single-stage procedure can be performed using the open, transanal or laparoscopy-assisted techniques. We use these cases to illustrate the first laparoscopically assisted procedures for Hirschsprung's disease in our center. The laparoscopic-assisted technique is described, and lessons in collaboration across institutions and within institutions are discussed.

KEYWORDS: Endorectal pull-through, Hirschsprung's disease, laparoscopy

INTRODUCTION

Hirschsprung's disease was first described by Harald Hirschsprung in the late 19th century.^[1] The management of the condition was a dilemma until the mid-20th century when the pathology was elucidated.^[2,3] Since then, the modalities of management of Hirschsprung's disease have evolved. From the initial third-staged procedure, it is now performed routinely as a single stage.^[4-6] In addition, other routes of access apart from the standard open per abdomen method for the pull through have also been added in the past three decades starting with

the anal approach and more recently, laparoscopy-assisted techniques.^[7,8] The laparoscopic-assisted transanal pull-through was first described by Bax and van der Zee in 1995 and has become the most widely used for this procedure.^[9] All these alternatives are available only in

Address for correspondence: Dr. Adesoji O Ademuyiwa, Department of Surgery, Paediatric Surgery Unit, Faculty of Clinical Sciences, College of Medicine, University of Lagos, PMB 12003, Idi Araba, Lagos, Nigeria.
E-mail: aoademuyiwa@cmul.edu.ng

This is an open access journal, and articles are distributed under the terms of the Creative Commons Attribution-NonCommercial-ShareAlike 4.0 License, which allows others to remix, tweak, and build upon the work non-commercially, as long as appropriate credit is given and the new creations are licensed under the identical terms.

For reprints contact: reprints@medknow.com

How to cite this article: Ademuyiwa AO, Elebute OA, Balogun OS, Desalu I, Chirdan LB, Bode CO. Laparoscopy-assisted transanal endorectal pull-through for the management of hirschsprung's disease in Nigeria: Report of two cases. Niger J Surg 2020;26:78-80.

Access this article online	
Quick Response Code: 	Website: www.nigerianjsurg.com
	DOI: 10.4103/njs.NJS_39_18

highly specialized pediatric surgical or colorectal centers in high income countries. Some of these methods have not been reported from the developing countries especially in sub-Saharan Africa. At the Lagos University Teaching Hospital, most of these modalities are routinely done except the laparoscopic-assisted techniques. We report our first two successful cases of laparoscopy-assisted transanal endoscopic pull-through (LATEP)– describing the technique and highlighting how collaborative efforts among the institutions and across units could enhance achievement of the desirable outcomes.

CASE REPORTS

Case 1

O. D., 19-month-old boy presented with a history of constipation since birth. The patient was noted to have passed meconium after 72 h of life. Bowel motions had been once in 2–3 weeks and occasionally after administering enema. There was associated abdominal distension, no straining on defecation, and no fever. On examination, abdomen was distended, with hyperactive bowel sounds. A barium enema showed transition zone in the sigmoid colon [Figure 1] following which a full-thickness rectal biopsy was done histologically confirmed Hirschsprung's disease. The patient was worked up for surgery and he had LATEP. He was discharged on postoperative day 5 with no untoward sequelae.

Case 2

M. J. is a 3-year-old boy who presented with 28 months history of constipation. He passed meconium after 24 h but within 48 h. Constipation was noticed from 6 months of life. Initially, bowel motions were 2–3 times a week but reduced to once per week (and only after castor oil administration). The patient strains at defecation had associated significant abdominal distension with colic. There is also a failure to thrive despite intact appetite.

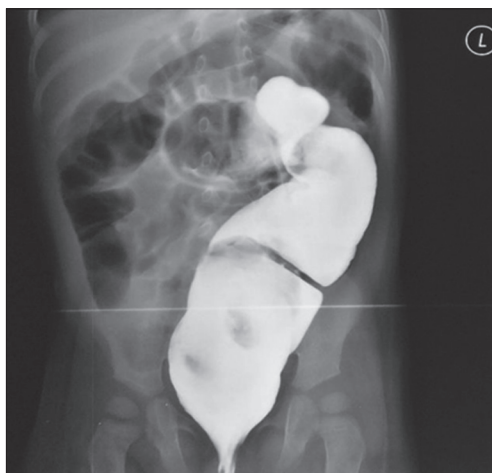

Figure 1: Contrast enema showing the transition zone in the sigmoid colon

Examination showed the abdomen was distended with normoactive bowel sounds. Digital rectal examination was unremarkable. Full-thickness rectal biopsy confirmed Hirschsprung's disease and barium enema (done before the biopsy) showed the transition zone in the sigmoid colon. The patient was optimized for surgery and had LATEP. He had uneventful postoperative period and he was discharged postoperative day 5.

Technique

Preoperative bowel preparation (low-residue diet and saline washouts) was done in the patients. We also did a preoperative barium enema in both patients to ascertain the region of the transition zone. Patients were positioned in a modified lithotomy with both legs on stirrups. Anesthetists are at the head of the patient while the camera is at the foot of the patient. The lead surgeon is on the patient's right, whereas the assistant surgeon is on the left with the perioperative nurse beside the surgeon close to the monitor.

Skin preparation was with cetrimide and chlorhexidine mixture and povidone-iodine from the nipple line to the mid-thigh incorporating the perineum. Draping exposed the abdomen and perineum, while the legs were covered from foot-to-mid-thigh. Four trocars were inserted a 10 mm in the umbilicus using Hanson's technique and three 5 mm in the lower abdomen under direct vision [Figure 2].

The abdomen is explored, and the transition zone was identified. Extramucosal biopsy about 3 cm above the upper limit of the transition zone was taken and sent for the intraoperative frozen section. The site was marked with a long-silk suture. In both patients, the results showed the positive ganglion cells, and this formed the part of the bowel that was pulled through for coloanal anastomosis. Minimal mobilization of the rectosigmoid was done laparoscopically before completing the pull through transanally.

DISCUSSION

Hirschsprung's disease is the most common cause of the functional intestinal obstruction in neonates and infants.^[10]

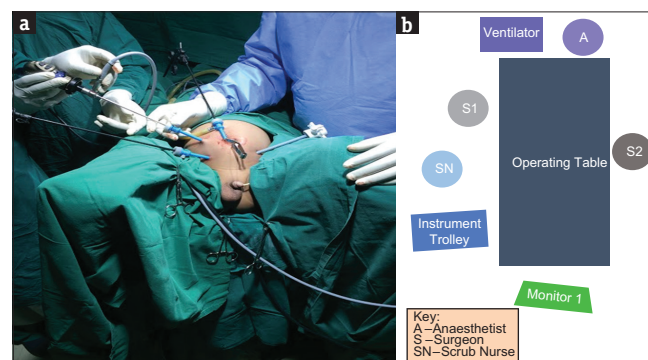


Figure 2: (a) Intraoperative position of ports. (b) Theater layout for laparoscopy-assisted transanal endoscopic pull-through

The obstruction is due to the lack of ganglion cells in the myenteric and submucous plexuses of the bowel which has been attributed to the failure of craniocaudal migration of neural crest cells during embryological development.^[11] The principle of management has evolved over the years and with the introduction of laparoscopy to surgical practice in the last half-century, the surgical treatment of Hirschsprung's disease has now involved this modality of treatment, since 1995 when its first use was published.^[9,12]

In the most developed countries, all the options are available in the specialized pediatric surgical centers, and many centers in sub-Saharan Africa do not have all the alternatives. This is partly due to the capital-intensive nature of acquiring both the equipment and training for laparoscopic surgery.^[13] However, there are a few centers that are beginning to gain proficiency in minimal access surgery.^[13] In our institution, equipment for laparoscopy had been acquired, and a young general surgeon who had undergone further training in laparoscopic surgery had just joined the service of the hospital. Due to the interest in pushing the frontiers of pediatric colorectal surgery in our center, a collaboration between the pediatric surgery unit with the adult laparoscopic surgeon (in our center), and another pediatric surgeon with extensive experience with the transanal procedure from another center within the country ensued. As such the first case was done with no untoward events, whereas the second was done with all personnel from our center with equally good outcome.

The use of laparoscopy in surgery has its pros and cons and some may argue its relevance in the management of Hirschsprung's disease particularly since the transanal route can achieve the same goals without an abdominal scar. While this is true, there are situations where the transanal route may not be the best choice. For example, in long-segment Hirschsprung's disease, some abdominal approach is often necessary for adequate mobilization. In such circumstances, the laparoscopic approach has advantages over the open route. Furthermore, even in the classical Hirschsprung's disease limited to the rectosigmoid, laparoscopy could be used to take intraoperative biopsies for the frozen section that could ascertain the level of aganglionosis before the pull through. Finally, acquisition of laparoscopic skills is the desired competence that pediatric surgeons in these contemporary times should have and be proficient in.

While we agree that our experience is very limited, it does show a feasible model that collaboration both within the institution and outside the institution can enhance the skills transfer. The authors are of the opinion that a lot can be achieved with this model both within the nation and generally across the West African sub-region. In conclusion, from our initial experience,

collaboration among the surgeons can enhance the skill transfer, and LATEP is a feasible therapeutic option for patients with Hirschsprung's disease in our center.

Declaration of patient consent

The authors certify that they have obtained all appropriate patient consent forms. In the form the patient(s) has/have given his/her/their consent for his/her/their images and other clinical information to be reported in the journal. The patients understand that their names and initials will not be published and due efforts will be made to conceal their identity, but anonymity cannot be guaranteed.

Financial support and sponsorship

Nil.

Conflicts of interest

There are no conflicts of interest.

REFERENCES

- Sergi C. Hirschsprung's disease: Historical notes and pathological diagnosis on the occasion of the 100(th) anniversary of Dr. Harald Hirschsprung's death. *World J Clin Pediatr* 2015;4:120-5.
- Balanescu R, Topor L, Nedelea S. Diagnosis and treatment of Hirschsprung's disease in children. *Ther Pharmacol Clin Toxicol* 2012;16:45-50.
- Haricharan RN, Georgeson KE. Hirschsprung disease. *Semin Pediatr Surg* 2008;17:266-75.
- Gunnarsdóttir A, Wester T. Modern treatment of Hirschsprung's disease. *Scand J Surg* 2011;100:243-9.
- Vincent MV, Jackman SU. Hirschsprung's disease in Barbados – A 16-year review. *West Indian Med J* 2009;58:347-51.
- Sowande OA, Adejuyigbe O, Ademuyiwa O, Usang UE, Bakare TI. Primary Swenson's pull through in infants less than 4 months: A preliminary report. *Afr J Pediatr Surg* 2006;3:56-60.
- Pratap A, Shakya VC, Biswas BK, Sinha A, Tiwari A, Agrawal CS, *et al.* Single-stage transanal endorectal pull-through for Hirschsprung's disease: Perspective from a developing country. *J Pediatr Surg* 2007;42:532-5.
- Aubdoollah TH, Li K, Zhang X, Li S, Yang L, Lei HY, *et al.* Clinical outcomes and ergonomics analysis of three laparoscopic techniques for Hirschsprung's disease. *World J Gastroenterol* 2015;21:8903-11.
- Bax NM, van der Zee DC. Laparoscopic removal of aganglionic bowel using the Duhamel-Martin method in five consecutive infants. *Pediatr Surg Int* 1995;10:226-8.
- Mabula JB, Kayange NM, Manyama M, Chandika AB, Rambau PF, Chalya PL, *et al.* Hirschsprung's disease in children: A five year experience at a university teaching hospital in northwestern Tanzania. *BMC Res Notes* 2014;7:410.
- Singer CE, Coşoveanu CS, Ciobanu MO, Stoica GA, Puiu I, Gruia CL, *et al.* Hirschsprung's disease in different settings – A series of three cases from a tertiary referral center. *Rom J Morphol Embryol* 2015;56:1195-200.
- Sowande OA, Adejuyigbe O. Ten-year experience with the Swenson procedure in Nigerian children with Hirschsprung's disease. *Afr J Paediatr Surg* 2011;8:44-8.
- Abdur-Rahman LO, Bamigbola KT, Nasir AA, Oyinloye AO, Abdulraheem NT, Oyedepo OO, *et al.* Pediatric laparoscopic surgery in North-Central Nigeria: Achievements and challenges. *J Clin Sci* 2016;13:158-62.