

## Original Article

# “Tracheomalacia after Thyroidectomy,” Does it Truly Exist?

Neda Valizadeh<sup>1</sup>, Peyvand Mohammadi<sup>2</sup>, Rahim Mahmodlou<sup>3</sup>, Seyed Arman Seyed Mokhtari<sup>4</sup>, Gohar Ramezani<sup>5</sup>

<sup>1</sup>Department of Endocrinology and Metabolism, Maternal and Childhood Obesity Research Center, Urmia University of Medical Sciences, Urmia, Iran, <sup>2</sup>Department of Endocrinology and Metabolism, Imam Khomeini Hospital, Urmia University of Medical Sciences, Urmia, Iran, <sup>3</sup>Department of General and Thoracic Surgery, Imam Khomeini Hospital, Urmia University of Medical Sciences, Urmia, Iran, <sup>4</sup>Student Research Committee, Urmia University of Medical Sciences, Urmia, Iran, <sup>5</sup>Student Research Committee, Faculty of Medical Sciences, Tabriz Branch, Islamic Azad University, Tabriz, Iran

Received : 13-07-2019

Accepted : 11-09-2019

Published : 10-02-2020

## INTRODUCTION

Tracheomalacia is defined as the intensity of a normal and physiologic decrement in tracheal diameter during the respiratory cycle. During deep inspiration, cough tracheal cartilages are collapsing and membranous part of the trachea in the posterior wall of it is prolapsed into the lumen, exacerbation of this condition during expiration that led to tracheal lumen narrowing is called tracheomalacia.<sup>[1]</sup> Czyhlarz reported tracheomalacia for the first time in 1897, after that this attributed to heterogeneous conditions without generally accepted definition and classification.<sup>[2,3]</sup> The cause of tracheomalacia can be congenital or acquired, secondary to external pressure or chronic infections. Congenital form results from cartilage immaturity, and acquired form

## ABSTRACT

**Aim:** Tracheomalacia is a potentially life-threatening, but a rare complication of thyroidectomy. In previous studies, the incidence rate was very different. Considering the relatively high prevalence of goiter and thyroidectomy in the West Azerbaijan region, we designed this study to determine the tracheomalacia incidence in patients who underwent thyroidectomy within a 10-year interval. **Materials and Methods:** This retrospective study was done in Urmia Imam Khomeini Hospital in West Azarbayjan Province. Demographic characteristics including the age and sex of patients who underwent thyroidectomy between 2007 and 2017 and also the incidence of tracheomalacia after surgery were recorded. **Results:** From 2007 to 2017, total 1236 thyroidectomy were performed. The patients' age ranged from 15 to 83-year-old with a mean age of patients was  $44.5 \pm 13.81$  years old. Two hundred and twenty-nine patients (19%) were male and 1007 (81%) were female. We did not find any cases of tracheomalacia after thyroidectomy in our study population. **Conclusion:** Based on the results of this study, it seems that with the necessary precautions, the incidence of tracheomalacia can reach zero.

**KEYWORDS:** Iran, thyroidectomy, tracheomalacia

is derived from the softening of normal cartilages due to external compression. A common factor in both conditions is inability of tracheal cartilage in keeping tracheal duct open.<sup>[4,5]</sup> Tracheomalacia in adults is mainly due to acquired factors and can be caused by acute or chronic conditions. Chronic tracheomalacia occurs due to tracheobronchitis, or recurrent polychondritis and acute form occur because of surgery on the trachea or its surrounding tissues.<sup>[6]</sup>

Postthyroidectomy tracheomalacia (PTT) is one of the respiratory problems after thyroidectomy that different results have been reported in previous studies.<sup>[6-8]</sup> PTT

**Address for correspondence:** Dr. Seyed Arman Seyed Mokhtari, 15 Num, Susan Alley, Golha Street, Tabriz, Iran. E-mail: armanmxt@yahoo.com

This is an open access journal, and articles are distributed under the terms of the Creative Commons Attribution-NonCommercial-ShareAlike 4.0 License, which allows others to remix, tweak, and build upon the work non-commercially, as long as appropriate credit is given and the new creations are licensed under the identical terms.

For reprints contact: reprints@medknow.com

**How to cite this article:** Valizadeh N, Mohammadi P, Mahmodlou R, Seyed Mokhtari SA, Ramezani G. “Tracheomalacia after Thyroidectomy,” Does it truly exist? Niger J Surg 2020;26:59-62.

Access this article online	
<b>Quick Response Code:</b> 	<b>Website:</b> <a href="http://www.nigerianjsurg.com">www.nigerianjsurg.com</a>
	<b>DOI:</b> 10.4103/njs.NJS_31_19

resulted from tracheal compression with long-standing huge thyroids. Some studies reported its incidence to as high as 10%.<sup>[9]</sup> On the other hand, other investigators reported its incidence from 0% to 5.3%.<sup>[7,8]</sup> For preventing of postextubation respiratory distress, prophylactic tracheostomy has been suggested in high-risk patients; patients with tracheal narrowing and retrosternal goiters.<sup>[7,10]</sup> In some centers, tracheostomy is done at the end of thyroidectomy because of tracheomalacia occurrence.<sup>[4,8]</sup> Correct diagnosis of tracheomalacia is made by the observation of cartilages collapses and membranous part collapse, despite normal motion of the vocal cord in bronchoscopy.<sup>[11,12]</sup>

### Aims and objectives

Cause of various reports of the occurrence of PTT and its potentially life-threatening risks, we designed this study to assess the frequency of tracheomalacia in a large number of patients undergoing thyroidectomy during a 10-year period.

### MATERIALS AND METHODS

This retrospective study was conducted in Urmia Imam Khomeini Hospital in West Azerbaijan Province. The Ethics Committee of Urmia University of Medical Sciences approved this study (Dated on 17, December 2019, Decision No: IR.UMSU.REC.1398.049). Demographic characteristics including the age and sex of patients who underwent thyroidectomy between years 2007 and 2017 and also the incidence of tracheomalacia after surgery were assessed. Due to the retrospective design of the study, informed consent was not taken.

All operations have been done by a single thoracic surgeon as the following: technique of thyroidectomy: after general anesthesia, a roll was put under shoulders, and operating table was positioned in reverse Trendelenburg position.

- Step 1: 6–7 cm incision from anterior of the right sternocleidomastoid muscle (SCM) to left SCM, and (larger incision in larger gland) two fingers width above suprasternal notch (SSN) were carried out
- Step 2: The subplatysmal flap was advanced by ElectroCutter or sharp dissection until SSN and upper border of the thyroid cartilage
- Step 3: Rafeh between strap muscles was opened
- Step 4: We began with small or intact lobe, strap muscles retracted in most cases but in very huge goiter incised then as high as possible
- Step 5: After dissection of the areolar tissues, middle thyroid vein was explored and ligated with 3-0 silk or with harmonic scalpel recently. When middle thyroid vein was absent, this step was omitted
- Step 6: The upper pole pedicle was ligated as near as

possible to thyroid with 00 silk or harmonic scalpel; we never explored superior laryngeal nerve

- Step 7: Inferior thyroid artery was identified, and in the angle between this artery and trachea, we explored the recurrent laryngeal nerve and followed until it enters the larynx. We explored recurrent laryngeal nerve without exception as opposed to superior laryngeal nerve. During this phase, we saved parathyroid gland, and when any of them became severe ischemic, was removed and preserved in saline for implantation at the end of the operation
- Step 8: After exploring of recurrent laryngeal nerve and parathyroid glands, thyroid lobe was removed from trachea by sharp dissection or harmonic scalpel. Opposite lobe was removed in the same manner
- Step 9: In large goiters, we drained wound with two Hemovac drains, strap muscle, and subcutaneous tissues were approximate with 00 and 000 chromic consecutively, and skin was closed with 000 nylon subcutaneously.

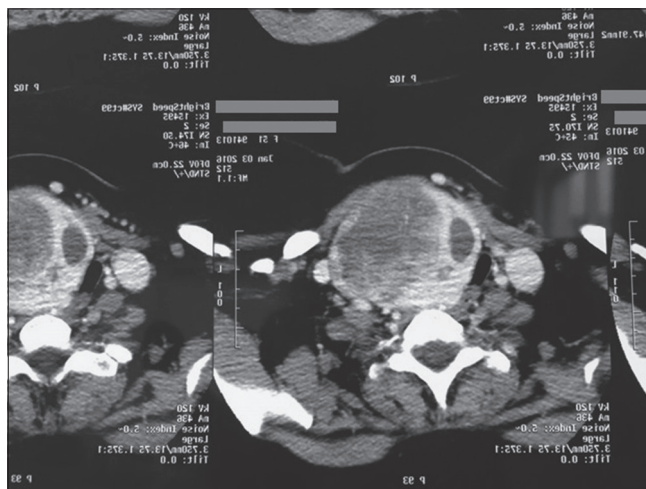
All patients had been extubated in the operating room without laryngoscopy at the time of extubation.

### RESULTS

From 2007 to 2017, 1236 total thyroidectomy were performed. The patient's age ranged from 15 to 83-year-old with a mean age of patients was  $44.5 \pm 13.81$  years old. Two hundred and twenty-nine patients (19%) were male and 1007 (81%) were female, respectively. We did not have any problem after extubation in the operating room, except two patients.

#### First case

A 54-year-old woman with multinodular goiter that scheduled for thyroidectomy due to pressure effect, she has no medical history and moderate thyroid



**Figure 1:** Neck computed tomography scan showing large right lobe with a deviation of trachea to left

enlargement, especially on the right lobe with tracheal deviation was only finding in physical examination. In laboratory tests, she was euthyroid, and other tests were normal. She underwent total thyroidectomy as the mentioned technique eventless and extubated at the end of the operation. Unfortunately, several minutes after extubation in operating room, she suffered severe stridor, cyanosis and we intubated her. We explored the wounds for nerve reexplore; fortunately, both nerves were completely intact until the entrance to larynx. With diagnosis of tracheomalacia, the patient transported to intensive care unit (ICU), after 24 h, reextubation was done, but severe stridor, cyanosis, and feeling of suffocation appeared, and we had to reintubate her. The day later, fiberoptic bronchoscope (FOB) was done along with pulmonologist, bilateral vocal cord paresis without any sign of cartilages collapses or membranous prolapsing was found. Then, tracheostomy was done with diagnosis of bilateral laryngeal nerve palsy. Two months later, FOB showed vocal cord recovery but we retained tracheostomy for another 4 weeks, and finally, tracheostomy removed successfully and the patient discharged 48 h later. She has no problem in 3-year follow-up.

### Second case

A 37-year-old woman was referred to endocrine clinics due to new-onset hoarseness and thyroid mass, in medical history, she had two cesarean sections that the last was 7 years ago. In physical examination, she had obvious hoarseness and a 6–7 cm nodule in the right lobe of the thyroid. Thyroid function tests were normal, and fine-needle aspiration of nodule showed colloid nodule in two separate examinations. Neck computed tomography scan showed large right lobe with deviation of trachea to left [Figure 1]. She scheduled for thyroidectomy, during operation, we first operated on the left lobe and after exploring the left recurrent laryngeal nerve and preserving two parathyroid glands, the left lobe was removed, in the right side strap muscles was transacted (we seldom do this), and exploration showed that the recurrent nerve is stretched severely in lower pole with nodule before crossing the inferior thyroid artery. The nerve was released and followed until larynx, aside this superior parathyroid gland preserved and inferior one that was ischemic removed and implemented in the left SCM at the end of operation. She extubated without any problems and transferred to recovery room, 30 min later, she complained of shortness of breathing, and her hoarseness was exaggerated, but she was conscious and O<sub>2</sub> saturation was 96%, head of bed is elevated, 200 mg hydrocortisone injected intravenously and was encouraged for coughing and deep inspiration. Gradually, her symptoms reduced and without intubation

transported to ICU for 12 h and on 2<sup>nd</sup> postoperation she discharged.

Pathology report was compatible with adenomatous goiter and surprisingly, her hoarseness resolved gradually during 3 months.

### DISCUSSION

Very large goiters are mainly associated with retrosternal extension and compression on the trachea and other adjacent organs.<sup>[1]</sup> Various complications following a thyroidectomy may occur, one of the most serious and most dangerous of these is tracheomalacia.<sup>[8]</sup> The definitive diagnosis of tracheomalacia is done with observation of tracheal membranous part collapse into lumen despite the normal motion of vocal cord.<sup>[11,12]</sup> It seems that the causes of contradiction results are the absence of accepted definitions about tracheomalacia, besides in some studies, the diagnosis was based on clinical diagnosis. If the diagnosis is done only clinically, so most of the postthyroidectomy respiratory problems will be reported as tracheomalacia, as in our patient that we thought that causes are tracheomalacia until bronchoscopy showed bilateral recurrent laryngeal nerve palsy. Different rates of tracheomalacia following thyroidectomy in patients with large goiters have been reported in various studies from 0 to 5.3 and even as high as 10%.<sup>[7,8,13]</sup>

In this study, despite a large number of patients undergoing thyroidectomy, we did not see any cases of tracheomalacia. The absence of this complication despite many patients with large goiters show that if other respiratory complications prevented by meticulous operation, and diagnosis of PTT is done with restrict adherence to bronchoscope evidence of tracheal collapse and normal vocal cord function, the true incidence of PTT is very low. Bennett *et al.*, in a study reviewing 12 articles, found that out of a total of 1969 cases of thyroidectomy, no cases of tracheomalacia and tracheal and airway collapse had occurred, which is consistent with our study results.<sup>[14]</sup> Furthermore, in Findlay *et al.* study, tracheomalacia incidence was about zero similar to our study.<sup>[7]</sup>

In a cross-sectional and retrospective study by Ayandipo *et al.*, from 2001 to 2005, among 507 patients undergoing thyroidectomy that most of them were female (86%), tracheomalacia has happened in 27 (5.3%) patients, and two patients with tracheomalacia died because of respiratory problems.<sup>[8]</sup> Compared with the study of Ayandipo *et al.*, in our study, there was no evidence of tracheomalacia following thyroidectomy. Nonoccurrence of tracheomalacia can be due to reducing other complication with meticulous operation and adherence

to bronchoscopic. Balasubramanian *et al.*<sup>[15]</sup> also reported tracheomalacia in three patients (one with papillary thyroid carcinoma and lung metastasis, one with hypopharyngeal cancer, and one with a papillary thyroid cancer with tracheal involvement). They advise supportive treatment with wet air, respiratory physiotherapy, and even continuous positive airway pressure through a mask for mild undiagnosed cases, and for severe cases, in addition to the above-mentioned measures, long-term intubation is considered necessary.<sup>[1]</sup>

## CONCLUSION

The strength of our study is the high sample size, and fortunately, based on our results, the tracheomalacia after thyroidectomy appears to be rarer than it is thought to be. Although worry about the occurrence of tracheomalacia after thyroidectomy in cases of very large goiter is reasonable, with the necessary precautions, it can be brought about near zero. Further prospective cohorts are recommended to investigate the incidence of tracheomalacia and its related risk factors after thyroidectomy, especially in the setting of massive goiters.

## Acknowledgment

We would like to thank Mrs. Parvin Ayremlou MSC of epidemiology from the Clinical Research Development Unit of Imam Khomeini Hospital, Urmia University of Medical Sciences, Urmia, Iran, for statistical analysis of the data.

## Financial support and sponsorship

Nil.

## Conflicts of interest

There are no conflicts of interest.

## REFERENCES

1. Parry Z, Macnab R. Thyroid disease and thyroid surgery. *Anaesth Intensive Care* 2017;18:488-95.
2. Medepalli K, Perez Y, Barahona LJ, Mirsaeidi M Mounier Kuhn Syndrome; a Magnified Incidental Finding, in D39: Dyspnea: Case reports II. *Am Thorac Soc* 2018:A6746-A6746.
3. Czyhlarz EV. Uber ein pulsionsdivertikel der trachea mit bemerkungen uber das verhalten der elastischen fasern an normalen tracheen und bronchien. *Centralb Allg Pathol Anat* 1897;8:721-8.
4. Hysinger EB, Panitch HB. Paediatric tracheomalacia. *Paediatr Respir Rev* 2016;17:9-15.
5. Atchley W, Kakkera KS, Vilensky V, Meena N. Acquired tracheomalacia secondary to excessive cuff inflation, in A44. *Interventional pulmonary: Case reports. Am Thorac Soc* 2017; A1620-A1620.
6. Machado NO. Thyroidectomy for massive goiter weighing more than 500 grams: Technical difficulties, complications and management. *review. Surg Sci* 2011;2:278.
7. Findlay JM, Sadler GP, Bridge H, Mihai R. Post-thyroidectomy tracheomalacia: Minimal risk despite significant tracheal compression. *Br J Anaesth* 2011;106:903-6.
8. Ayandipo O, Adigun T, Afuwape O. Airway complications and outcome after thyroidectomy in Ibadan: A 15 year review. *Arch Med* 2016;8:4.
9. Hasegawa I, Boiselle PM, Raptopoulos V, Hatabu H. Tracheomalacia incidentally detected on CT pulmonary angiography of patients with suspected pulmonary embolism. *AJR Am J Roentgenol* 2003;181:1505-9.
10. Jiang AG, Gao XY, Lu HY. Diagnosis and management of an elderly patient with severe tracheomalacia: A case report and review of the literature. *Exp Ther Med* 2013;6:765-8.
11. Lee C, Cooper RM, Goldstein D. Management of a patient with tracheomalacia and supraglottic obstruction after thyroid surgery. *Can J Anaesth* 2011;58:1029-33.
12. Kugler C, Stanzel F. Tracheomalacia. *Thorac Surg Clin* 2014;24:51-8.
13. White ML, Doherty GM, Gauger PG. Evidence-based surgical management of substernal goiter. *World J Surg* 2008;32:1285-300.
14. Bennett AM, Hashmi SM, Premachandra DJ, Wright MM. The myth of tracheomalacia and difficult intubation in cases of retrosternal goitre. *J Laryngol Otol* 2004;118:778-80.
15. Balasubramanian S, Kannan R, Balakrishnan K. Post-operative tracheomalacia after surgery on the thyroid and the aero-digestive tract. *Internet J Surg* 2009;19(2).