

Case Report

Avulsion Injuries of Right Hemidiaphragm: Report of Two Case Scenarios with Different Outcomes

Nupur Aggarwal, Priyansh Jariwala, Shaban Kamal, Navneet Kaur

General Surgery Department,
University College of
Medical Sciences and Guru
Teg Bahadur Hospital, New
Delhi, India

ABSTRACT

Avulsion injuries of domes of the diaphragm are rare injuries and may occur following lateral thoracoabdominal trauma. We share our experience of two cases of avulsion injuries of the right dome of the diaphragm. Our first case presented within a week following blunt trauma to the abdomen, and on thoracotomy, an effective repair was performed by restoring attachment of the diaphragm to the parietes. Our second case presented with severe respiratory distress, 1½ months after sustaining blunt injury chest and abdomen in a road traffic accident and on thoracotomy was found to have a completely necrosed right hemidiaphragm, and hence, no repair could be performed. However, the patient could not be weaned off ventilator and died after 3 months of primary injury. These cases highlight the importance of early diagnosis and repair of diaphragmatic injuries for a favorable outcome.

KEYWORDS: *Avulsion, diaphragmatic injury, right hemidiaphragm, trauma*

INTRODUCTION

Traumatic diaphragmatic injury is a commonly missed injury in trauma patients.^[1] Right-sided diaphragmatic injuries are less common due to the protective effect of bare area of liver and most series report incidence of 35%–49%.^[2] Here, we present two interesting cases of avulsion of the right hemidiaphragm.

CASE REPORTS

Case report 1

A 10-year-old boy, run over by a trolley, presented after 5 days of trauma to our center in tachypneic state with a chest tube *in situ* and oxygen saturation of 80%, which improved to 98% with oxygenation. The child had blood pressure of 99/72 mmHg and tachycardia of 112 beats/min, with Glasgow Coma Score of 15/15. On examination, there were diminished breath sounds on the right hemithorax, and tenderness was present in the right upper abdomen with overlying abrasion. The chest X-ray showed right costophrenic angle blunting with a chest tube *in situ* and tenting of the right dome of the diaphragm. Contrast-enhanced computed tomography (CECT) of the chest and abdomen showed grade intravenous (IV) liver laceration, hemoperitoneum, and Grade III diaphragmatic injury with herniation of

liver into right hemithorax.^[3] Atelectasis of the right lower lobe and right-sided moderate pleural effusion was also present. The patient was started on IV fluids and IV antibiotics. Avulsion injury of the right dome of the diaphragm was visualized on right posterolateral thoracotomy. The diaphragm was detached from parietes from midline anteriorly to posterior axillary line, and laceration of liver was also present [Figures 1 and 2]. Repair of the diaphragmatic injury was done by restoring attachment of diaphragm to the chest wall using polypropylene sutures. Liver laceration was not actively bleeding and hence did not require any repair. Right lung expanded fully on positive pressure ventilation. Postoperatively, the child had an uneventful recovery, and a follow-up chest X-ray after 3 months showed normal contour of the diaphragm and normal lung fields.

Case report 2

A 45-year-old female incurred multiple rib fractures with right-sided hemothorax following a road traffic accident,

Address for correspondence: Dr. Priyansh Jariwala,
A 136 Second Floor, Vivek Vihar Phase 2, Jhilmil Colony,
New Delhi - 110 095, India.
E-mail: drpriyanshjain@yahoo.com

This is an open access journal, and articles are distributed under the terms of the Creative Commons Attribution-NonCommercial-ShareAlike 4.0 License, which allows others to remix, tweak, and build upon the work non-commercially, as long as appropriate credit is given and the new creations are licensed under the identical terms.

For reprints contact: reprints@medknow.com

How to cite this article: Aggarwal N, Jariwala P, Kamal S, Kaur N. Avulsion injuries of right hemidiaphragm: Report of two case scenarios with different outcomes. *Niger J Surg* 2019;25:223-5.

Access this article online	
Quick Response Code: 	Website: www.nigerianjsurg.com
	DOI: 10.4103/njs.NJS_41_18

and a thoracostomy tube insertion was done at the primary treating hospital. The patient also had fractures of the right fibula and tibia which were managed with open reduction and internal fixation at the same center. A CECT thorax was done which showed second and third right rib fracture with collapse and consolidation of the right lung and laceration of the right lobe of liver with contusion. She was finally referred to our tertiary care center after 1½ months from the antecedent injury. On examination, she was conscious, oriented, pulse rate was 118/min, blood pressure was 108/82 mm Hg with severe dyspnea (respiratory rate of 25–30 breaths/min), and decreased air entries at the lung bases bilaterally. The patient was intubated and shifted to ICU for ventilatory support. A repeat Chest X Ray and CECT thorax showed bilateral multiple rib fractures, right-sided hemothorax with air foci in the collection, and an indistinct outline of the diaphragm [Figures 3 and 4]. The patient was taken up for exploration in view of a possible diaphragmatic

injury, and right posterolateral thoracotomy was done. Intraoperatively, we found necrotic sloughed out the right dome of the diaphragm with collapsed right lung. An organized collection was present in the right hemithorax and the liver was lying in the lower thoracic cavity. All the necrotic tissues and organized hematomas were removed, and an intercostal tube was placed between liver and the collapsed lung. No repair of diaphragm could be done. Postoperatively, she had stable recovery but could not be weaned off mechanical ventilation. A tracheostomy was done in view of long-term intubation. Enteral feeds were started through nasogastric tube. The patient was transferred to the cardiothoracic surgery unit after 3 weeks for further management. However, in view of her poor general condition, no further surgery was performed and she died after 1 month.

DISCUSSION

The incidence of diaphragmatic injury varies from 0.8% to 8%.^[4] Isolated diaphragmatic injury is rare

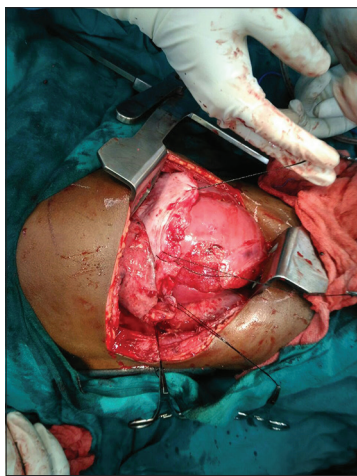


Figure 1: Intraoperative picture showing ruptured diaphragm and liver laceration

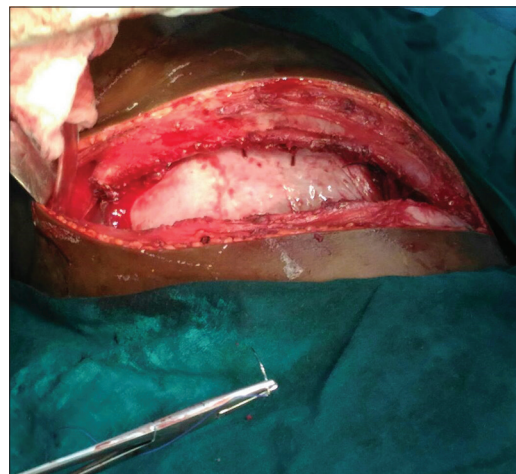


Figure 2: Intraoperative picture of the repaired diaphragm

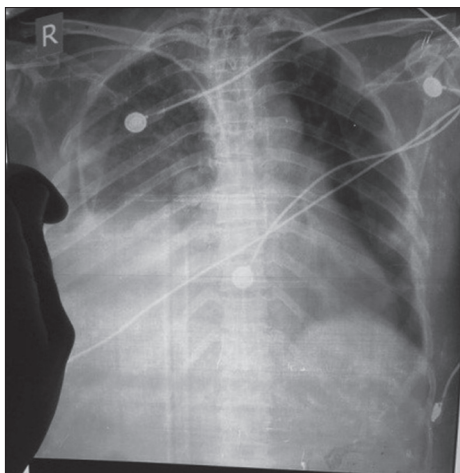


Figure 3: Chest X-ray showing ill-defined contour of the right hemidiaphragm

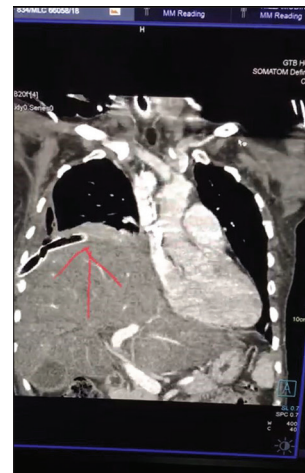

Figure 4: Contrast-enhanced computed tomography thorax film of the patient

with associated injury rate reaching up to 100%. Most morbidity and mortality are due to associated injuries. It is commonly associated with intra-abdominal injuries, thoracic injuries, fractures of the ribs, pelvis, and long bones, head injuries, and rarely aortic injuries.^[2]

A careful search for diaphragmatic injury in any suspected case of blunt or penetrating trauma abdomen should be the norm. All patients with wound entering Murray's Box, which is defined as area between nipple/inframammary fold to coastal margins below should be thoroughly evaluated.^[5] A simple chest X-ray showing pleural effusion, atelectasis, contusion, or diaphragmatic elevation is a red flag sign to suspect diaphragmatic injury. CECT chest is an excellent investigation. However, isolated diaphragmatic injury might still be missed.^[6] Diagnostic laparoscopy and thoracoscopy are new modalities for early diagnosis and repair of diaphragmatic injury at the same time. In case of further doubt, video-assisted thoracoscopy or laparotomy confirms a diaphragmatic rent.^[1]

Management involves exploratory laparotomy, reduction of the herniated contents with adhesiolysis, and repair of diaphragm with nonabsorbable sutures with or without nonabsorbable mesh. Thoracotomy might be needed to assess the integrity of suture line and adhesiolysis.^[7]

Alternative methods in a contaminated field include the use of biologic mesh, vascularized tissue flaps, or a temporary absorbable mesh with plans for a delayed reconstruction. However, massive gunshot wounds and diaphragmatic injuries are the challenges. Surgical options include relocating the hemidiaphragm at a higher level superior to the thoracic defect, effectively converting thoracic wound into abdominal one. Muscle flaps such as transverse abdominis, external oblique, and reverse latissimus dorsi are used to cover the wound.^[8] A sloughed diaphragm needs to be debrided and reinforced with mesh however with very high chances of infection in acute contaminated wound.^[1] Recent advances have allowed minimal access repair of diaphragmatic injuries including video-assisted thoracoscopic and robotic surgery.^[9,10]

Thus, we conclude that early diagnosis of diaphragmatic injury results in better outcome. We also highlight that management options for totally devitalized

hemidiaphragm with no support available to fix the mesh are abysmal. Thus, further trials to seek management options for such cases need to be done.

Declaration of patient consent

The authors certify that they have obtained all appropriate patient consent forms. In the form the patient(s) has/have given his/her/their consent for his/her/their images and other clinical information to be reported in the journal. The patients understand that their names and initials will not be published and due efforts will be made to conceal their identity, but anonymity cannot be guaranteed.

Financial support and sponsorship

Nil.

Conflicts of interest

There are no conflicts of interest.

REFERENCES

- Hanna WC, Ferri LE, Fata P, Razek T, Mulder DS. The current status of traumatic diaphragmatic injury: Lessons learned from 105 patients over 13 years. *Ann Thorac Surg* 2008;85:1044-8.
- Bosanquet D, Farboud A, Heyman L. A review diaphragmatic injury. *Respir Med CME* 2009;2:1-6.
- Available from: <http://www.aast.org/library/traumatools/injuryscoringscales.aspx#diaphragm>. [Last accessed on 2018 Dec 14].
- Hanna WC, Ferri LE. Acute traumatic diaphragmatic injury. *Thorac Surg Clin* 2009;19:485-9.
- DeBarros M, Martin MJ. Penetrating traumatic diaphragm injuries. *Curr Trauma Rep* 2015;1:92-101.
- Lone RA, Sharma ML, Wani M, Rather S, Ahangar AG, Rasool F, *et al.* Traumatic diaphragmatic rupture, a diagnostic dilemma in the presence of eventration: A case report. *Cases J* 2009;2:6615.
- Lee MA, Choi KK, Lee GJ, Yu BC, Ma DS, Jeon YB, *et al.* Right diaphragmatic injury accompanied by herniation of the liver: A case report. *J Korean Soc Traumatol* 2016;29:43-6.
- Solli P, Bertolaccini L, Brandolini J, Pardolesi A. Reconstructive techniques after diaphragm resection and use of the diaphragmatic flap in thoracic surgery. *Shanghai Chest* 2017;1(4).
- Parelkar SV, Oak SN, Patel JL, Sanghvi BV, Joshi PB, Sahoo SK, *et al.* Traumatic diaphragmatic hernia: Management by video assisted thoracoscopic repair. *J Indian Assoc Pediatr Surg* 2012;17:180-3.
- Counts SJ, Saffarzadeh AG, Blasberg JD, Kim AW. Robotic transthoracic primary repair of a diaphragmatic hernia and reduction of an intrathoracic liver. *Innovations (Phila)* 2018;13:54-5.