

## Case Report

# Large Abdominal Wall Defect Reconstruction: Revoking and Modifying the Old Technique

Singaravelu Viswanathan, Souparna Manjunath, BA Ramesh, Mohan Jagannathan

Department of Plastic Surgery, Sri Ramachandra Medical College and Research Institute (Deemed to be University), Chennai, Tamil Nadu, India

### ABSTRACT

The risk factors for abdominal wall hernia after surgery are an increase in body mass index, midline incision, incisional surgical-site infection, preoperative chemotherapy, blood transfusion, increasing age, female sex, and increasing thickness of subcutaneous tissue. Reconstructing the abdominal wall defect becomes a challenge in multiple risk factor patients. Many new mesh implants have been invented, but all fail in case of infections. We modified and re-evoked an old technique of fascia lata free graft reinforced with tensor fascia lata pedicled flap.

**KEYWORDS:** Abdominal wall reconstruction, pedicled tensor fascia lata, tensor fascia lata graft

## INTRODUCTION

Ventral hernias are a most common complication of abdominal surgery, especially ones that have had an adverse postoperative outcome concerning healing of the wounds. The risk factors for abdominal wall hernia after surgery are an increase in body mass index, midline incision, incisional surgical-site infection, preoperative chemotherapy, blood transfusion, increasing age, female sex, and increasing thickness of subcutaneous tissue.<sup>[1]</sup>

The defect can be corrected with anatomical repair or mesh repair as described in the literature. These techniques are executable if the abdomen is not extremely scarred and the abdominal wall musculature is intact. It becomes difficult in repairing the abdomen when some components of the abdominal wall are missing. Many flaps have been described for abdominal wall reconstruction which includes the latissimus dorsi, rectus abdominus, external oblique, tensor fascia lata (TFL), and rectus femoris. The challenge is when reconstruction is required when all the components of the abdominal wall are missing. The abdominal wall defects are divided into two groups depending on the presence or absence of normal skin coverage. In Type I defect, there is intact or stable covering skin, whereas Type II defects have absent or unstable skin cover.<sup>[2]</sup>

## CASE REPORT

A 55-year-old female admitted to us with complaints of 40% acute flame burns to the neck, chest anterior abdominal wall, and upper limbs. The patient had a history of multiple abdominal surgeries secondary to tuberculosis 10 years back. She had an exploratory laparotomy which ended up having a burst abdomen, for which a temporary colostomy was done and closed, due to which she developed a large ventral hernia. Five years later, the patient underwent an open mesh repair, which got infected, and the mesh had to be removed. When she presented to us, the skin over a ventral hernia had second-degree deep dermal burns which were grafted. The patient after rehabilitation from burn wounds came back again for a ventral hernia repair. The patient had Type 2 abdominal wall defect [Figure 1]. The patient deferred the option of the microvascular free flap.

We planned a TFL graft harvested from the left thigh for closing the rectus defect and an islanded TFL myocutaneous flap from right thigh for the abdominal defect.

**Address for correspondence:** Dr. BA Ramesh,

Department of Plastic Surgery, Sri Ramachandra Medical College and Research Institute (Deemed to be University), No. 1, Ramachandra Nagar, Porur, Chennai - 600 116, Tamil Nadu, India.

E-mail: [ramesh.ba@sriramachandra.edu.in](mailto:ramesh.ba@sriramachandra.edu.in)

### Access this article online

#### Quick Response Code:



Website: [www.nigerianjsurg.com](http://www.nigerianjsurg.com)

DOI: 10.4103/njs.NJS\_29\_18

This is an open access journal, and articles are distributed under the terms of the Creative Commons Attribution-NonCommercial-ShareAlike 4.0 License, which allows others to remix, tweak, and build upon the work non-commercially, as long as appropriate credit is given and the new creations are licensed under the identical terms.

**For reprints contact:** [reprints@medknow.com](mailto:reprints@medknow.com)

**How to cite this article:** Viswanathan S, Manjunath S, Ramesh BA, Jagannathan M. Large abdominal wall defect reconstruction: Revoking and modifying the old technique. *Niger J Surg* 2019;25:220-2.

On the table, the edge of a hernia was incised. The skin adherent to peritoneum was excised. There was a defect of 20 cm × 12 cm in the lower two-third of the abdomen in the midline. A fascia lata graft was harvested from left thigh measuring 18 cm × 10 cm and sutured to the edge of the abdominal wall [Figure 2a]. On the right side, the TFL islanded flap was elevated of about 30 cm × 10 cm in dimension and turned 120° for the distal end of the flap to reach the upper limit of the abdominal defect [Figure 2b]. The segment between the proximal end of the flap and the lower end of the abdominal defect in the right iliac region was incised and opened up to the external fascia to accommodate the bridging segment of the flap. The fascia was reinforced to the inside wall edge, and the skin was sutured with a closed suction drain. The donor area was closed primarily [Figure 2c].

The postoperative period was uneventful. The closed suction drain removed on the 6<sup>th</sup> postoperative day, and the sutures were removed on the 14<sup>th</sup> postoperative day. At 6-month follow-up, no herniation of the abdominal contents was obtained. Thigh donor site healed without any complications [Figure 3].

## DISCUSSION

Reconstruction of the abdominal wall focuses primarily on the restoration of function and stability, prevention of viscera herniation, as well as the re-establishment of esthetically acceptable appearance. An abdominal wall defect exists when one of the components of the abdominal wall is missing. The critical parts of the abdominal wall include the muscle and fascia providing support and function and the skin.

The abdominal wall defects are divided into two groups depending on the presence or absence of normal skin coverage.<sup>[2]</sup>

In Type I defect, there is intact or stable covering skin, whereas Type II defects have absent or unstable skin cover.

In Type II defect with a skin loss and exposed viscera and has been further categorized into different types depending on the presence of contamination, lateralization, and fixation of the abdominal wall, the presence of enteric fistula and finally a frozen abdomen.

Type 1 defects can be treated with facial reconstruction with either autologous or prosthesis materials such as prolene mesh and PTFE mesh since there is stable skin available.

Type 2 defects require musculoaponeurotic reconstruction with skin cover. The local flap options

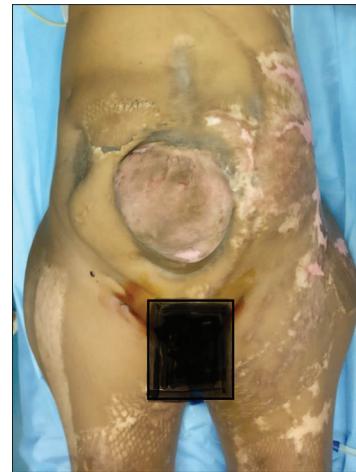


Figure 1: Preoperative incisional hernia

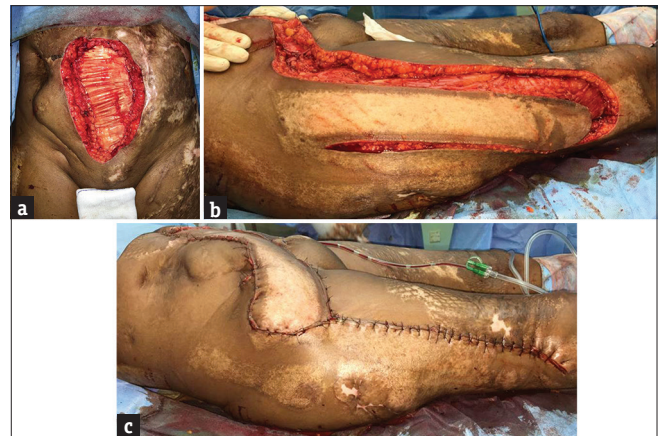


Figure 2: Intraoperative (a) tensor fascia lata graft sutured to abdomen defect, (b) tensor fascia lata flap harvest, and (c) flap inset over fascia lata graft

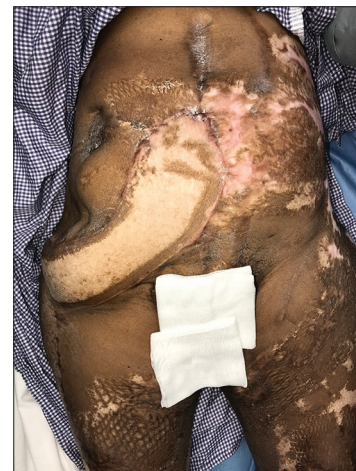

Figure 3: Postoperative after 6 months

are rectus muscle flap, latissimus dorsi muscle flap, and external oblique flap. Distant flap options are TFL muscle flap and rectus femoris flap. Free TFL graft is also an option for abdominal wall reconstruction.<sup>[3]</sup> The

patient already had complications due to mesh repair and deferred it for abdominal wall strengthening.

The component separation surgery is not possible in this patient as there is atrophy of rectus abdominus muscle. Since the patient has deferred microvascular free flap, we were left with an option of the regional flap. The regional flap cover of latissimus dorsi and external oblique would not reach. The rectus abdominus turnover flap was not possible due to the burnt lower abdominal skin. Other options discussed were rectus femoris or TFL flap; of the two, the postoperative morbidity is lesser with the TFL flap and hence it was chosen.<sup>[3,4]</sup>

The TFL flap is perhaps the most popular choice for reconstruction of lower abdominal wall defects. The flap is known for lower abdominal wall and groin reconstruction its reach up the umbilicus is questionable. Besides, the flap is also known to have distal tip necrosis if the length of the flap is extended beyond the 30 cm.<sup>[5]</sup>

In our patient, the length of the flap did not extend beyond 30 cm and the pivoting at the pedicle did not cause any vascular insufficiency; moreover, since the patient had previously undergone mesh repair which failed, an autologous material had to be used which in recent times is not in vogue, i.e., a nonvascularized TFL graft. The graft was used as additional support to prevent herniation of the abdominal contents. The current plastic surgical management of large abdominal defects is a microvascular free flap.

## CONCLUSION

The microvascular free flap reconstruction is the norm of the day and has jumped the reconstructive ladder.

When the patient defers the option, modification of old described techniques which have stood the test of time gives a good and viable outcome.

## Declaration of patient consent

The authors certify that they have obtained all appropriate patient consent forms. In the form the patient(s) has/have given his/her/their consent for his/her/their images and other clinical information to be reported in the journal. The patients understand that their names and initials will not be published and due efforts will be made to conceal their identity, but anonymity cannot be guaranteed.

## Financial support and sponsorship

Nil.

## Conflicts of interest

There are no conflicts of interest.

## REFERENCES

1. Itatsu K, Yokoyama Y, Sugawara G, Kubota H, Tojima Y, Kurumiya Y, *et al.* Incidence of and risk factors for incisional hernia after abdominal surgery. *Br J Surg* 2014;101:1439-47.
2. Mathes SJ, Steinwald PM, Foster RD, Hoffman WY, Anthony JP. Complex abdominal wall reconstruction: A comparison of flap and mesh closure. *Ann Surg* 2000;232:586-96.
3. Williams JK, Carlson GW, deChalain T, Howell R, Coleman JJ. Role of tensor fasciae latae in abdominal wall reconstruction. *Plast Reconstr Surg* 1998;101:713-8.
4. Srinivas JS, Panagatla P, Damalacheru MR. Reconstruction of type II abdominal wall defects: Anterolateral thigh or tensor fascia lata myocutaneous flaps? *Indian J Plast Surg* 2018;51:33-9.
5. Song Z, Yang D, Yang J, Nie X, Wu J, Song H, *et al.* Abdominal wall reconstruction following resection of large abdominal aggressive neoplasms using tensor fascia lata flap with or without mesh reinforcement. *Hernia* 2018;22:333-41.