

Case Report

An Unusual Case of Biliary Stent Migration in Sacrum

Anant Sadanand Ramani, Sudip Mandrekar, Dattaprasad Samant, Francisco Noronha

Department of Surgery,
Goa Medical College,
Bambolim, Goa, India

ABSTRACT

The common bile duct stenting has been a common endoscopic procedure practiced worldwide for the treatment of benign or malignant bile duct obstruction. Although the procedure has shown a very low morbidity, it is not free from complications. Stent migration has been a common late complication seen in 10% of cases presenting with various manifestations depending on the site of impaction. Here, we present a rare case of distal stent migration with impaction in the sacral foramina due to perforation through sigmoid diverticula with review of literature.

KEYWORDS: Common bile duct stent, distal stent migration, stent impaction

INTRODUCTION

The common bile duct stenting has been the procedure frequently employed in various pathologies secondary to benign or malignant diseases in the biliary tract. The above procedure of common bile duct stenting was first described by Soehendra and Reynders-Frederix,^[1,2] in 1980. The procedure is conducted with very low morbidity and negligible mortality rate but as the number of procedures are increasing few early and late complications have been reported. Common late complications in the form of stent migration are reported in 10% of the cases.^[1] Distal impaction following stent migration is commonly seen in bowel with hernia, adhesions, kinks, colonic diverticula, and rarely in appendix lumen. Migration in sigmoid colon through diverticula and further impaction in sacral foramina are rarely reported. Retrieval is usually done through endoscope with very low rate of complications.

CASE REPORT

A 58-year-old woman presented to the outpatient department with dull aching pain in the left lower abdomen of 1-month duration. The patient had a history of endoscopic retrograde cholangiopancreatography (ERCP) with sphincterotomy done with extraction of common bile duct stones and insertion of biliary plastic stent 10F 8 cm long. Later on, after 1 month, the patient underwent laparoscopic cholecystectomy. However, the patient did not turn up for stent removal in spite of advice.

On examination, pulse rate was 84/min, blood pressure was 130/80 mmHg, and respiratory rate was 20/min. Abdominal and rectal digital examination was normal. Computed tomography scan done showed stent impacted in sacral foramina in the left iliac fossa [Figures 1 and 2]. Colonoscopy showed multiple sigmoid diverticula with stent impacted in one of them in mid-sigmoid colon. Stent retrieval was done through colonoscopy with extractor forceps. The patient had an uneventful recovery and was discharged on the subsequent day [Figure 3]. The patient was seen 1 month later and was fine.

DISCUSSION

Common bile duct stent insertion was introduced by Soehendra and Reynders-Frederix in 1980 for ERCP and bile duct stone extraction. Today, it has been the gold standard for the same. Biliary stents are also used for the treatment of benign and malignant bile duct strictures. In benign conditions, biliary stenting is done for the management of bile duct fistulas or leaks. In malignant bile duct obstructions due to cholangiocarcinomas or pancreatic malignancies, bile duct stenting apart from palliative use can be also used effectively to correct the jaundice before

Address for correspondence: Dr. Anant Sadanand Ramani,
Department of Surgery, Goa Medical College, Bambolim,
Goa, India.
E-mail: ramani.anant@rediffmail.com

This is an open access journal, and articles are distributed under the terms of the Creative Commons Attribution-NonCommercial-ShareAlike 4.0 license, which allows others to remix, tweak, and build upon the work non-commercially, as long as appropriate credit is given and the new creations are licensed under the identical terms.

For reprints contact: reprints@medknow.com

How to cite this article: Ramani AS, Mandrekar S, Samant D, Noronha F. An unusual case of biliary stent migration in sacrum. *Niger J Surg* 2019;25:104-6.

Access this article online	
Quick Response Code: 	Website: www.nigerianjsurg.com
	DOI: 10.4103/njs.NJS_28_18

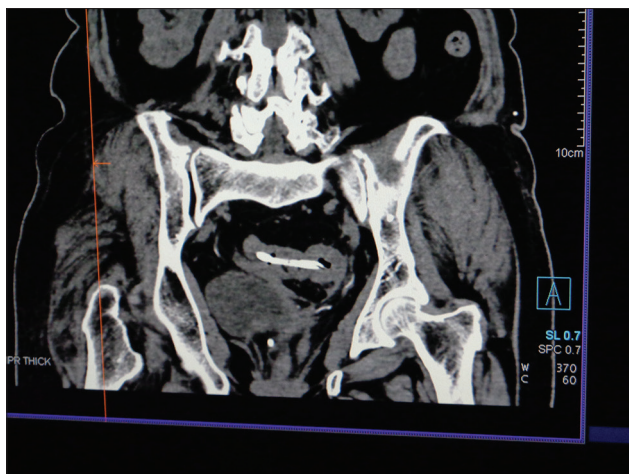


Figure 1: Computed tomography scan showing stent in sigmoid colon

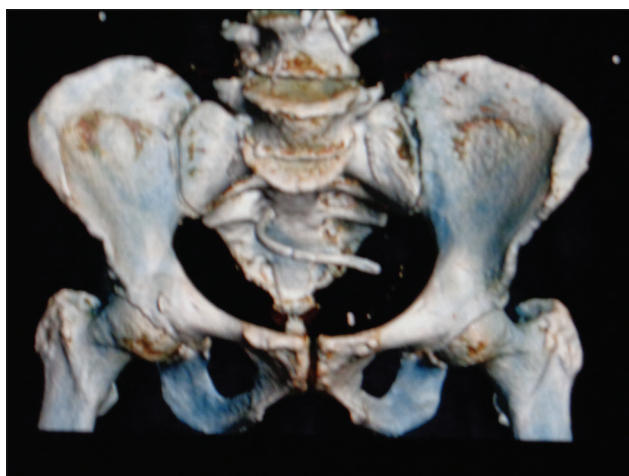


Figure 2: Computed tomography scan three-dimensional image showing stent impacted in sacral foramina

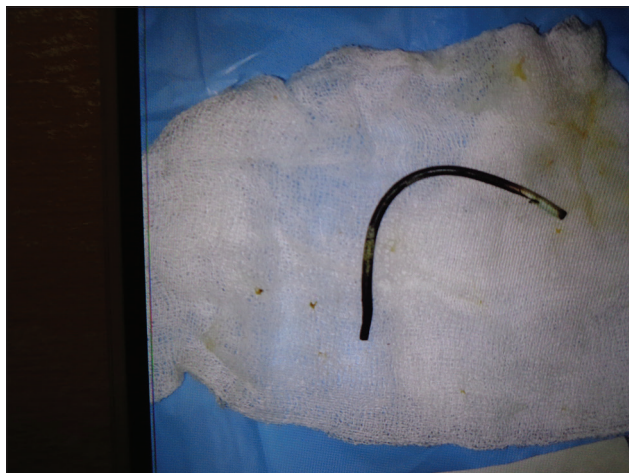

Figure 3: Stent retrieved via colonoscope

after adequate dilatation or percutaneously through transhepatic route through percutaneous transhepatic cholangiography channel. Ideally, the stent should be removed or changed after 6 weeks to prevent its complications. Biliary stents are of two types plastic and metallic, the former can be straight or double pigtail, whereas the latter is mainly used for the management of malignant strictures. Biliary stents are safe to use; however, few complications are known to occur in a small group of patients. Early complications following ERCP has a 5% risk in the form of infection (35%), pancreatitis (29%), bleeding (23%), perforation (6%), early stent migration (3%), and renal failure (3%).^[3] Late complications in the form of stent migration (10%) either proximal or distal, stent obstruction, and infections are seen to occur due to failure in timely removal of the stents.^[4] Proximal migration occurs in proximal hepatic ducts and present with jaundice. Although distal migration usually passes safely down the intestines, a few cases of stent impaction are seen in bowels with kinks, adhesions, hernia sites, and diverticula.^[5] Impaction is more seen in plastic stents due to its configuration with side wings and barbs. Impaction can further lead to perforation, abscess, and fistula formation. Extraintestinal stent migration through intestinal perforation is common with straight plastic biliary stents leading to diffuse peritonitis and intraperitoneal abscesses. Perforation is common in the duodenum it being a fixed structure and can lead to retroperitoneal bilomas.^[6] Further down perforation can occur in small bowel or colon fixed due to adhesions, hernia, or diverticula. Retrieval is usually done through endoscope using forceps, balloon, basket, or laparotomy. However, emergency laparotomy is indicated for retrieval when there is extraintestinal migration with gross contamination. Retroperitoneal bilomas need aspiration. Impaction commonly occurs in less than 1% cases in the duodenum and distal ileum,^[7] rarely seen in sigmoid diverticula leading to fistulas and abscesses. Here, we present a rare case of stent impaction in sacral foramina after perforation through sigmoid diverticula which as per our search is not found reported in the literature. Early retrieval done through endoscopy or surgery leads to cure.

CONCLUSION

All patients with biliary plastic stents should be advised and counseled about its removal 6 weeks postprocedure and explained the complications in case of failure to comply. Patients presenting with abdominal pain or

definitive surgery. However, there are certain limitations in its use when the biliary obstruction cannot be bypassed due to tight nature of the stricture. In such cases, bile duct stenting is done

jaundice with past history of ERCP and biliary stent insertion, the strong possibility of stent migration and impaction has to be kept in mind, especially in patients with known risk factors for stent impaction such as hernias, adhesions and colonic diverticula.

Declaration of patient consent

The authors certify that they have obtained all appropriate patient consent forms. In the form the patient(s) has/have given his/her/their consent for his/her/their images and other clinical information to be reported in the journal. The patients understand that their names and initials will not be published and due efforts will be made to conceal their identity, but anonymity cannot be guaranteed.

Financial support and sponsorship

Nil.

Conflicts of interest

There are no conflicts of interest.

REFERENCES

1. Bagul A, Pollard C, Dennison AR. A review of problems following insertion of biliary stents illustrated by an unusual complication. *Ann R Coll Surg Engl* 2010;92:W27-31.
2. Soehendra N, Reynders-Frederix V. Palliative bile duct drainage – A new endoscopic method of introducing a transpapillary drain. *Endoscopy* 1980;12:8-11.
3. Jones M, George B, Jameson J, Garcea G. Biliary stent migration causing perforation of the caecum and chronic abdominal pain. *BMJ Case Rep* 2013;2013. pii: bcr201300912.
4. Arhan M, Odemiş B, Parlak E, Ertuğrul I, Başar O. Migration of biliary plastic stents: Experience of a tertiary center. *Surg Endosc* 2009;23:769-75.
5. Akbulut S, Cakabay B, Ozmen CA, Sezgin A, Sevinc MM. An unusual cause of ileal perforation: Report of a case and literature review. *World J Gastroenterol* 2009;15:2672-4.
6. Kumar N, Sahu SK, Agrahari VK, Bedi KS, Shankar M, Arora R, *et al.* Extra intestinal biliary stent migration: A rare case. *SRHU Med J* 2017;1:38-40.
7. Saranga Bharathi R, Rao P, Ghosh K. Iatrogenic duodenal perforations caused by endoscopic biliary stenting and stent migration: An update. *Endoscopy* 2006;38:1271-4.