

## Original Article

# Management of Major Postcholecystectomy Biliary Injuries: An Analysis of Surgical Results in 62 Patients

Sushruth Shetty, Premal R Desai, Hasmukh B Vora, Mahendra S Bhavsar, Lakshman S Khiria, Ajay Yadav, Nikhil Jillawar

Department of Gastro Surgery, NHLM Medical College, Vadilal Sarabhai Hospital, Ahmedabad, Gujarat, India

ABSTRACT

**Background:** Management of injuries sustained during cholecystectomy requires expertise and involves a patient who is troubled, usually drained of personal resources. There has been an increase in incidence with laparoscopic cholecystectomy. The standard surgical management done for major biliary injuries is Roux-en-Y Hepaticojejunostomy (R-en-Y HJ). **Materials and Methods:** Patients managed surgically for definitive management of biliary injuries in the form of R-en-Y HJ were included. Data were collected from prospectively maintained records and through outpatient follow-up. Demographic data, early and late surgical complications, long-term outcomes, and follow-up results were analyzed. **Results:** Among the 62 patients, 26 were males, with a mean age of  $37.4 \pm 13.5$  years. A total of 24 patients presented with ongoing biliary fistula. The Strasberg–Bismuth type of injury included types E1 in 8 (13%), E2 in 31 (50%), E3 in 19 (30.6%), and E4 in four patients (6.4%). There were no postoperative mortality and morbidity in 27.4% of patients. Atrophy–hypertrophy complex was seen in four patients, vascular injury in six patients, and an internal fistulisation with duodenum in two patients. Presence of comorbidities ( $P = 0.05$ ), male gender ( $P = 0.03$ ), tobacco use ( $P = 0.04$ ), low albumin ( $P = 0.016$ ), and more proximal (E4-E1) type of injury ( $P = 0.008$ ) were independent predictors of postoperative morbidity ( $P < 0.05$ ). The mean duration of patient follow-up was  $26.2 \pm 21.1$  months. **Conclusion:** Optimization of preoperative nutrition, avoidance of intraoperative blood transfusion, proper timing of repair, and tension-free R-en-Y HJ draining all the ducts which is done at an experienced hepatobiliary center provide the best outcome.

**KEYWORDS:** Bile duct injury, cholecystectomy, hepaticojejunostomy, surgical treatment

## INTRODUCTION

Injury to bile ducts can occur during any surgical procedure but most commonly is seen during cholecystectomy. Management of these injuries requires expertise and involves a patient who is troubled as well as drained of personal resources. Several large population-based studies indicate that the incidence of major bile duct injury in laparoscopic cholecystectomy (LC) is 0.3% to 0.5%, which is higher than the 0.1%–0.2% incidence reported with open cholecystectomy (OC).<sup>[1]</sup> Management of patients sustaining iatrogenic bile duct injury depends on the time of detection of injury, type of injury, patient

factors and the availability of an expert hepatobiliary surgeon. A tension-free Roux-en-Y Hepaticojejunostomy (R-en-Y HJ) has been considered the most appropriate treatment for major injuries.<sup>[2,3]</sup> Controversies regarding the timing of repair of biliary fistula also need to be addressed with some recent studies showing equivalent results following early Vadilal Sarabhai (VS) late repair.<sup>[4]</sup> The goal of treatment is to mainly control sepsis,

**Address for correspondence:** Dr. Premal R Desai,

Department of Gastro Surgery, NHLM Medical College, Vadilal Sarabhai Hospital, Ahmedabad - 380 006, Gujarat, India.  
E-mail: [vsastro18@gmail.com](mailto:vsastro18@gmail.com)

This is an open access journal, and articles are distributed under the terms of the Creative Commons Attribution-NonCommercial-ShareAlike 4.0 License, which allows others to remix, tweak, and build upon the work non-commercially, as long as appropriate credit is given and the new creations are licensed under the identical terms.

For reprints contact: [reprints@medknow.com](mailto:reprints@medknow.com)

**How to cite this article:** Shetty S, Desai PR, Vora HB, Bhavsar MS, Khiria LS, Yadav A, et al. Management of major postcholecystectomy biliary injuries: An analysis of surgical results in 62 patients. *Niger J Surg* 2019;25:91-6.

| Access this article online  |   |
|---|---|
| Quick Response Code:<br> | Website: <a href="http://www.nigerianjsurg.com">www.nigerianjsurg.com</a> |
|   | DOI: 10.4103/njs.NJS_35_18  |

achieve controlled drainage of biliary fistula during the early period and to timely treat the biliary stricture and prevent hepatic damage during late phase. In our study we intend to discuss the results of surgical management of major postcholecystectomy biliary injuries managed in a tertiary care hospital of western part of India.

## MATERIALS AND METHODS

We included all patients who were managed surgically for definitive management of biliary injuries in the form of R-en-Y HJ in the department of Gastro surgery, VS Hospital, Smt. Nathiba Hargovandas Lakhmichand Municipal Medical College, Ahmedabad, Gujarat, India, between January 2012 and December 2017. VS Hospital is a major healthcare provider and the only teaching hospital providing super specialization in Surgical Gastroenterology in the State. All the surgeries were performed by a single surgeon with 22 years of experience in hepatobiliary surgery.

After obtaining approval of the institutional ethics committee, data were collected from prospectively maintained records and through outpatient follow-up. Patient data including demographics, operative details, and postoperative outcomes were recorded. All patients underwent preoperative blood investigations and investigation to evaluate biliary anatomy.

The standard surgery done was tension-free mucosa to mucosa R-en-Y HJ including all the ducts at the hilum.<sup>[5]</sup> All the surgeries were performed by an open approach and through a right sub costal incision extended to midline. Side-to-side HJ was done using a roux-loop of 50 cm taken in a retro-colic fashion. Following HJ, a stent was placed across the anastomoses in all the patients, which was exteriorized and usually removed between 45 and 90 days depending on the complexity of the anastomoses. The stent was preferably positioned into the right posterior duct across the anastomoses. An intraoperative liver biopsy was done in patients operated during last 3 years. The anatomic extent of bile duct injuries (BDIs) was described using the Strasberg–Bismuth classification system.<sup>[6]</sup> Early postoperative complications and mortality were those occurring within 90 days of surgical repair. Bile leak was defined as visible bile tinge/frank bile in intra-abdominal drain or presence of any intra-abdominal bile collection detected on imaging. The correlation of overall postoperative morbidity which included surgical-site infections (SSIs), bile leak, pulmonary complications, deep-vein thrombosis (DVT), incisional hernia, and anastomotic stricture was studied in relation to preoperative patient parameters such as serum albumin, preoperative total bilirubin levels, intraoperative blood transfusion, age, body mass index (BMI), comorbid

conditions, gender, type of biliary injury (E4-E1), and associated vascular injury. The duration of follow-up was calculated from the date of the BDI repair to the last follow-up visit. Liver function tests and ultrasound of the abdomen were done at each visit. The outcome of definitive surgery was graded as per the McDonald system [Table 1].<sup>[7]</sup>

## Statistical analysis

Data were presented as mean  $\pm$  standard deviation and range wherever appropriate. Comparisons between groups were made using Fisher's exact test/Chi-square test, and  $P < 0.05$  (confidence interval of 95%) was considered statistically significant. All statistical analyses were conducted using Statistical Package for the Social Sciences software version 20 (IBM Corporation, Chicago, United States).

## RESULTS

We included a total of 62 patients who underwent R-en-Y HJ for the management of postcholecystectomy bile duct injury at our center. All the patients were referred from other center except one patient who had sustained injury at our center, wherein a common bile duct clipping was done (Type E2) and patient developed postoperative jaundice. Patients underwent R-en-Y HJ on postoperative day 7. Among the 62 patients, 26 were male and 36 were female, with a mean age of  $37.4 \pm 13.5$  years [Table 2]. During index surgery, bile duct injury was detected intraoperatively in four patients.

**Table 1: Long-term outcome of patients undergoing Hepatico-jejunostomy**

| Classification                           | Number of patients |
|--|--------------------|
| Excellent (A)                            |                    |
| Normal LFT results, asymptomatic         | 56                 |
| Good (B)                                 |                    |
| Mild elevation LFT results, asymptomatic | 3                  |
| Fair (C)                                 |                    |
| Abnormal LFT results, cholangitis, pain  | 1                  |
| Poor (D)                                 |                    |
| Surgical revision or dilation required   | 2                  |

LFT: Liver function tests

**Table 2: Patient characteristics and index surgery done**

|                         |                         |
|-------------------------|-------------------------|
| Male: female            | 26:36                   |
| Age (range)             | 37.4 $\pm$ 13.5 (14–67) |
| Index surgery           |                         |
| OC                      | 10                      |
| LC                      | 39                      |
| Lap converted to OC     | 11                      |
| OC with CBD exploration | 2                       |

CBD: Common bile duct, LC: Laparoscopic cholecystectomy, OC: Open cholecystectomy

All these four patients had laparoscopic converted to OC. The on-table repair attempted included primary closure alone in one patient, primary closure with internal double J stent in one patient, and two patients were referred with drains placed as controlled biliary fistulas. Among the 62 patients, 24 patients presented as biliary fistula and 38 patients had biliary stricture without fistula. The mode of presentation has been discussed [Table 3].

The presenting symptoms included jaundice in 42 (67.7%), generalized prurites in 20 (32%), pain abdomen in 19 (30.6%), pale stool in 18 (29%), and fever in 11 (17.7%) patients. During the preoperative period, the mean value of patient's hemoglobin and albumin were  $9.9 \pm 1.28$  g/dl and  $2.56 \pm 0.51$  g/dl, respectively. Patient comorbidities included diabetes mellitus in three (4.8%), hypertension in four (6.4%) and both in two (3.2%) patients. The mean operative time duration for R-en-Y HJ was  $185 \pm 36$  min and mean blood loss was  $86 \pm 32$  ml. Intraoperatively nodular liver was seen in two patients, Atrophy-hypertrophy complex (AHC) in four patients and an internal fistulization with duodenum was demonstrable in two patients. The Strasberg-Bismuth type of injury is summarized [Figure 1]. Concomitant vascular injury was seen in six (9.6%) patients. All 62 patients underwent tension-free mucosa to mucosa R-en-Y HJ by preplaced delayed absorbable interrupted sutures. Among the 62 patients, two anastomoses were needed in three patients who had type E4 stricture. Liver

biopsy was performed in 31 patients. Final impression was secondary biliary cirrhosis in four, mild to moderate fibrosis in nine and no fibrosis in 18 patients.

There was no postoperative mortality. Postoperative morbidity occurred in 17 (27.4%) patients [Table 4]. The mean preoperative total bilirubin level was  $6.84 \pm 3.8$  mg/dl. The mean bilirubin levels at 2 weeks and 3 months postoperatively were  $1.81 \pm 1.18$  mg/dl and  $0.9 \pm 0.36$  mg/dl respectively. All four patients who had bile leak responded well to conservative management. Bile leak subsided on an average 6 days postoperatively. One patient developed intra-abdominal bile collection which was diagnosed by ultrasound on postoperative day 4 and was drained with two pigtail catheters placed percutaneously. Patient recovered well and is now well on 1 year of follow up. Late postoperative complications included anastomotic stricture and incisional hernia. Anastomotic stricture occurred in two patients after 12 and 16 months, respectively, following R-en-Y HJ. Both the patients underwent re-exploration with redo HJ proximal to the previous R-en-Y HJ site.

On comparison between postoperative complications and preoperative parameters [Table 5], presence of comorbidities ( $P = 0.05$ ), male gender ( $P = 0.03$ ), tobacco use ( $P = 0.04$ ), low serum albumin ( $P = 0.016$ ), more proximal (E4-E1) type of biliary injury ( $P = 0.008$ ) were independent predictors of postoperative morbidity ( $P < 0.05$ ). Advanced age ( $P = 0.47$ ), BMI ( $P = 0.32$ ), presence of fistula at the time of presentation ( $P = 0.48$ ), time duration between index surgery and HJ ( $P = 0.39$ ), associated vascular injury ( $P = 0.47$ ), intra operative blood transfusion ( $P = 0.17$ ), preoperative total bilirubin ( $P = 0.15$ ) and preoperative hemoglobin ( $P = 0.45$ ) did not show a statistically significant correlation to overall postoperative morbidity ( $P > 0.05$ ).

In two patients with biliary fistula, R-en-Y HJ was performed at the 4<sup>th</sup> and the 5<sup>th</sup> month in the presence of ongoing biliary fistula. This had no statistically significant correlation with overall postoperative morbidity ( $P = 0.52$ ). The mean duration of patient follow up was  $26.2 \pm 21.1$  months. During follow up period the outcome of R-en-Y HJ was assessed using the McDonald criteria [Table 1].<sup>[7]</sup> In our study majority of the patients had excellent (90.3%) to good (4.8%) outcomes. One patient whose intra operative biopsy had shown features of cirrhosis belonged to the fair outcome category (1.6%). Two patients developed anastomotic stricture on follow up and were symptomatic with altered liver function requiring a second surgical procedure (3.2%).

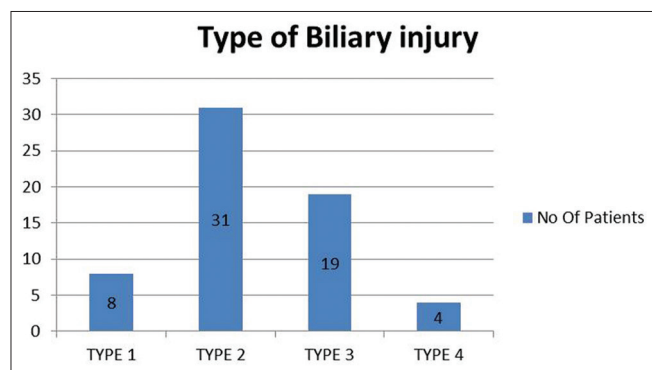


Figure 1: Type of injury according to Strasberg-Bismuth grading

Table 3: Presentation of patients sustaining biliary injury

| Mode of presentation                       | Number of patients (n=62) |
|--|---------------------------|
| Controlled biliary fistula                 | 17                        |
| Uncontrolled biliary fistula               | 7                         |
| Surgical Jaundice without fistula          | 36                        |
| Abnormal LFT and imaging showing stricture | 2                         |

LFT: Liver function tests

**Table 4: Complications of hepatico-jejunostomy and management**

| Surgical complications     | Number of patients (%) | Management                        |
|----------------------------|------------------------|-----------------------------------|
| Surgical site infection    | 6 (9.6)                | Conservative                      |
| Intra-abdominal collection | 1 (1.6)                | Ultrasound guided pig tail drains |
| Transient bile leak        | 4 (6.4)                | Conservative                      |
| Pulmonary complications    | 6 (9.6)                | Conservative                      |
| Deep vein thrombosis       | 1 (1.6)                | Conservative                      |
| Incisional hernia          | 4 (6.4)                | Meshplasty                        |
| Anastamotic stricture      | 2 (3.2)                | Redo Hepatico-jejunostomy         |

**Table 5: Correlation between preoperative parameters and postoperative morbidity and P value**

| Preoperative parameter     | Postoperative complication |           |                         |                   |                       |                                 |
|----------------------------|----------------------------|-----------|-------------------------|-------------------|-----------------------|---------------------------------|
|                            | Surgical site infection    | Bile leak | Pulmonary complications | Incisional hernia | Anastamotic stricture | Overall postoperative morbidity |
| Serum albumin              | 0.02                       | 0.21      | 0.20                    | 0.47              | 0.50                  | 0.016                           |
| Total bilirubin            | 0.66                       | 0.14      | 0.08                    | 0.14              | 0.10                  | 0.15                            |
| Blood transfusion          | 0.02*                      | 0.23*     | 0.45*                   | 0.57*             | 0.57*                 | 0.17*                           |
| Advanced age               | 0.75                       | 0.70      | 0.04                    | 0.02              | 0.31                  | 0.47                            |
| Higher BMI                 | 0.01                       | 0.33      | 0.37                    | 0.90              | 0.74                  | 0.32                            |
| Co morbid conditions       | 0.62*                      | 0.44*     | 0.03*                   | 0.38*             | 0.72*                 | 0.05*                           |
| Male gender                | 0.49*                      | 0.01*     | 0.49*                   | 0.37*             | 0.66*                 | 0.03*                           |
| Associated vascular injury | 0.52*                      | 0.41*     | 0.52*                   | 0.73*             | 0.18*                 | 0.47*                           |
| Type of injury (E4-E1)     | 0.67                       | 0.015     | 0.03                    | 0.24              | 0.88                  | 0.008                           |

\*Where Fischer exact test was used. Pearson Chi square test was used in all except. BMI: Body mass index

## DISCUSSION

Iatrogenic biliary injuries continue to occur even in the hands of experienced surgeons.<sup>[3]</sup> For major biliary injuries a well performed tension free R-en-Y HJ with wide anastomoses is the time proven treatment method and can be stated as a gold standard procedure.<sup>[2-4]</sup> A well performed R-en-Y HJ can give excellent results and a near-normal life but any problem during this may cause a biliary cripple. We included 62 patients who underwent R-en-Y HJ at our center. The mean age of our patient population was  $37.4 \pm 13.5$  years which is similar to the incidence of gall stone disease and cholecystectomy.<sup>[1,8]</sup> Overall the incidence of cholecystectomy is higher among women and in most studies women constitute majority of the biliary injury patients. In our population, the male: female ratio was 13:18.

The indication for OC is decreasing and has fewer indications in the present era.<sup>[9,10]</sup> In our study group 10 patients (16%) had undergone planned OC. This may indicate the regional differences from the world data. Majority of the biliary injuries are detected postoperatively in several series including ours where only in four patients (6.4%) it was detected intra operatively. This may be related to the intrinsic nature of LC or may be due to under reporting.

BDIs can be classified based on their location and degree of severity. The Bismuth–Strasberg classification

system<sup>[6]</sup> is the most widely used. In our study E2 was the commonest type seen. In patients who underwent HJ the mean time duration between index surgery and definitive surgery was  $48.1 \pm 15$  days in patients presenting with fistula and it was  $117.4 \pm 86$  days in patients who presented with biliary stricture without fistula. This delay in presentation of patients especially in those without bile leak further emphasizes the need for a better follow up and referral pattern for postcholecystectomy patients.

The timing of the definitive surgery has been debated and also some major series have argued in favor of late repair (after 6 weeks) in order to let infection, inflammation and ischemia settle before reconstruction. In contrast, immediate repair has been suggested to be the best if the BDI is recognized during primary surgery and there is an expert hepatobiliary surgeon available, but with a bit higher risk of anastomotic stricture.<sup>[3,8]</sup> We preferred a delayed approach (after 4–6 weeks) in majority of patients after the fistula output had ceased. This also allowed for the inflammation to settle down, to build up patient's nutrition and to perform the anastomoses on a dilated biliary system.

The use of trans-anastomotic stents across the R-en-Y HJ is controversial.<sup>[11,12]</sup> We used appropriate sized infant feeding tube which was exteriorized through the roux limb. The purpose of stenting was to facilitate anterior wall anastomoses, to help in case of anastomotic leak

and mainly to acquire a good postoperative tube cholangiogram demonstrating drainage of all the ducts in our setting of a teaching hospital. The stent was clamped usually during the first postoperative week and removed after an average of 45 days after performing a cholangiogram.

There was no postoperative mortality in patients undergoing R-en-Y HJ. The overall postoperative morbidity was 27.4% which is comparable to other similar studies showing results of biliary repair.<sup>[6,8]</sup> The most common postoperative morbidity seen was SSI in six (9.6%) patients which had a significant correlation with low preoperative serum albumin and intra operative blood transfusion. This emphasizes the need for preoperative optimization of nutrition and anemia. Postoperative bile leak from HJ site occurred in five patient's, of which four had a controlled leak through intra operatively placed drain and one had intra-abdominal collection which needed percutaneous guided pig tail drainage. All the HJ leaks subsided with conservative management. Postoperative pulmonary complications occurred in six patients (9.6%) and DVT in one patient (1.6%) during the early postoperative period. Both the patients recovered well with conservative management. Other complications included incisional hernia in four (6.4%) and anastomotic stricture in two patients (3.2%) seen during late postoperative period ( $P < 0.05$ ). Open Meshplasty was performed for two patients with incisional hernia. Postoperative anastomotic stricture was managed by open surgical revision of HJ as percutaneous balloon dilatation was not feasible.

The presence of cirrhosis during bile duct injury repair is considered an ominous sign and the most important risk factor predicting increased morbidity and mortality.<sup>[13-15]</sup> The liver histology of patients with biliary stricture varies from changes of cholestasis with swelling of hepatocytes, ballooning degeneration, periportal inflammation, periportal fibrosis and bridging fibrosis to profound secondary biliary cirrhosis with regenerating nodules.<sup>[14]</sup> Intra operative biopsy was done in 31 out of 62 patients who underwent R-en-Y HJ. Total four patients had features of definitive secondary biliary cirrhosis, nine patients had mild to moderate fibrosis which was graded as early cirrhosis and 18 patients did not have any liver fibrosis. Among the patients who had cirrhosis one patient had presented after 1 year, two presented between 6 months to 1 year and another one patient presented at 5 months following biliary injury for the definitive surgery. None of our patients with histological finding of cirrhosis developed profound portal hypertension with bleed or ascitis during

the follow up period. In our study concomitant vascular injury was seen in six patients of whom four patients had an intraoperative liver biopsy report available. Three of these four patients showed changes of liver fibrosis compared to 10 of 27 patients who did not have vascular injury and had undergone liver biopsy ( $n = 31$ ). Though this was not statistically significant ( $P = 0.15$ ) due to small number of patients, vascular injury may be an important contributing factor to liver fibrosis.

AHC of the liver sometimes complicates postcholecystectomy benign biliary strictures. In a study done in north India,<sup>[8,16]</sup> 36 out of 362 patients (9.9%) who underwent surgical repair had AHC. In our study, AHC was noted in four out of 62 patients (6.4%). The mean time duration between injuries to repair was 239 days for patients with AHC compared to 119 days for patients with biliary stricture undergoing HJ without AHC.

The long term outcome of patients sustaining iatrogenic biliary injuries has been less discussed in literature. Patients sustaining minor biliary injuries may have a near normal long term outcome but patients with high grade injuries and undergoing surgical repair may develop anastomotic stricture, incisional hernia, impaired liver functions and secondary biliary cirrhosis as complications, most of which are preventable by providing an ideal management of BDIs at expert hepatobiliary centers.<sup>[7,15]</sup> In our study two patients developed anastomotic stricture on follow up and required revision of R-en-Y HJ. When the preoperative parameters were analyzed, associated vascular injury was the factor with most significance for anastomotic stricture ( $P = 0.18$ ). Preoperative bilirubin ( $P = 0.14$ ) and advanced age of patient ( $P = 0.02$ ) correlated with the development of incisional hernia during late postoperative period. The long term outcome of surgical repair was described by the McDonalds criteria<sup>[7]</sup> by which majority of patients (95%) had excellent-to-good outcomes (Grades A and B).

## CONCLUSION

The analysis of our surgical results further emphasizes the fact that tension free mucosa to mucosa R-en Y HJ done by including all ducts at hilum is the most standard form of definitive repair for major biliary injuries. Delayed repair allows inflammation to settle and HJ can be performed with acceptable rates of morbidity on a dilated system. Optimization of preoperative nutrition, restricted intra operative transfusions and proper timing of repair done at an experienced hepatobiliary center provides best outcome. Further studies with longer duration of follow up are needed to assess the long-term

outcomes following repair of bile duct injury sustained during cholecystectomy.

### Financial support and sponsorship

Nil.

### Conflicts of interest

There are no conflicts of interest.

### REFERENCES

1. Deziel DJ, Millikan KW, Economou SG, Doolas A, Ko ST, Airan MC, *et al.* Complications of laparoscopic cholecystectomy: A national survey of 4,292 hospitals and an analysis of 77,604 cases. *Am J Surg* 1993;165:9-14.
2. Sicklick JK, Camp MS, Lillemoe KD, Melton GB, Yeo CJ, Campbell KA, *et al.* Surgical management of bile duct injuries sustained during laparoscopic cholecystectomy: Perioperative results in 200 patients. *Ann Surg* 2005;241:786-92.
3. Kapoor VK. Management of bile duct injuries: A practical approach. *Am Surg* 2009;75:1157-60.
4. Sahajpal AK, Chow SC, Dixon E, Greig PD, Gallinger S, Wei AC. Bile duct injuries associated with laparoscopic cholecystectomy: Timing of repair and long-term outcomes. *Arch Surg* 2010;145:757-63.
5. Hepp J. Hepaticojejunostomy using the left biliary trunk for iatrogenic biliary lesions: The French connection. *World J Surg* 1985;9:507-11.
6. Strasberg SM, Hertl M, Soper NJ. An analysis of the problem of biliary injury during laparoscopic cholecystectomy. *J Am Coll Surg* 1995;180:101-25.
7. McDonald ML, Farnell MB, Nagorney DM, Ilstrup DM, Kutch JM. Benign biliary strictures: Repair and outcome with a contemporary approach. *Surgery* 1995;118:582-90.
8. Pottakkat B, Vijayahari R, Prakash A, Singh RK, Behari A, Kumar A. Incidence, pattern and management of bile duct injuries during cholecystectomy: Experience from a single centre. *Dig Surg* 2010;27:375-9.
9. El Nakeeb A, Mahdy Y, Salem A, El Sorogy M, El Rafea AA, El Dosoky M, *et al.* Open cholecystectomy has a place in the laparoscopic era: A retrospective cohort study. *Indian J Surg* 2017;79:437-43.
10. Ashfaq A, Ahmadih K, Shah AA, Chapital AB, Harold KL, Johnson DJ. The difficult gall bladder: Outcomes following laparoscopic cholecystectomy and the need for open conversion. *Am J Surg* 2016;212:1261-4.
11. Redwan AA. Complex post-cholecystectomy biliary injuries: Management with 10 years' experience in a major referral center. *J Laparoendosc Adv Surg Tech A* 2012;22:539-49.
12. Mercado MA, Chan C, Orozco H, Cano-Gutiérrez G, Chaparro JM, Galindo E, *et al.* To stent or not to stent bilioenteric anastomosis after iatrogenic injury: A dilemma not answered? *Arch Surg* 2002;137:60-3.
13. Negi SS, Chaudhary A. Analysis of abnormal recovery pattern of liver function tests after surgical repair of bile duct strictures. *J Gastroenterol Hepatol* 2005;20:1533-7.
14. Sikora SS, Srikanth G, Agrawal V, Gupta RK, Kumar A, Saxena R, *et al.* Liver histology in benign biliary stricture: Fibrosis to cirrhosis and reversal? *J Gastroenterol Hepatol* 2008;23:1879-84.
15. Schmidt SC, Langrehr JM, Hintze RE, Neuhaus P. Long-term results and risk factors influencing outcome of major bile duct injuries following cholecystectomy. *Br J Surg* 2005;92:76-82.
16. Pottakkat B, Vijayahari R, Prasad KV, Sikora SS, Behari A, Singh RK, *et al.* Surgical management of patients with post-cholecystectomy benign biliary stricture complicated by atrophy-hypertrophy complex of the liver. *HPB (Oxford)* 2009;11:125-9.