

Case Report

An Alternative Technique in the Control of Massive Presacral Rectal Bleeding: Fixation of GORE-TEX® Aortic Patch

Mustafa Ozsoy, Zehra Ozsoy¹, Suleyman Sahin, Yüksel Arikan²

Department of General Surgery, Parkhayat Hospital,

¹Department of Internal Medicine, State Hospital,

²Department of General Surgery, Faculty of Medicine, Afyon Kocatepe University, Afyon, Turkey

ABSTRACT

The presacral venous system is located under the pelvic fascia covering the anterior of the sacrum and consists of two lateral sacral veins, middle sacral vein, and the veins that communicate them. The presacral venous system can be easily damaged and causes serious bleeding which is difficult to control and may cause intraoperative mortality. Its incidence varies between 3% and 9.4%. Although several methods have been tried to control presacral bleeding, the definitive method of treatment has not yet been identified. We present here our alternative technique in control of massive presacral massive bleeding developed from the presacral plexus secondary to the traction of the specimen during the dissection. The bleeding could not be controlled despite the use of all technical possibilities such as packing, ligation, and hemostatic agents. Bleeding control was provided by GORE-TEX® graft. We conclude that fixation of GORE-TEX® aortic patch should be kept in mind for uncontrolled massive presacral bleeding.

KEYWORDS: GORE-TEX® graft, presacral bleeding, rectal cancer

INTRODUCTION

The presacral venous system consists of two lateral sacral veins, middle sacral vein, and the veins that communicate them, under the pelvic fascia covering the anterior of the sacrum. These veins which do not have valves are connected with the internal vertebral venous system through basivertebral veins.^[1] The presacral venous system can be easily damaged and causes serious bleeding which is difficult to control, and its incidence varies between 3% and 9.4%.^[1] Herein, we described the new technique in the control of presacral plexus bleeding during rectal surgery.

CASE REPORT

A 59-year-old male patient was admitted with the complaint of rectal bleeding. Colonoscopy revealed an ulcerovegetative mass that partially allows the passage of the colonoscope, beginning from the 3rd cm of the rectum. The biopsy was reported as an adenocarcinoma, and magnetic resonance imaging revealed invasion of the levator ani muscle and lymph node positivity. The patient underwent neoadjuvant chemoradiotherapy, and a decision for surgery was made based on the evidence of no distant

organ metastasis and regression of the tumor mass. On encountering dissection difficulties in surgery which was started laparoscopically, it was converted to conventional surgery. Massive bleeding developed from the presacral plexus secondary to the traction of the specimen during the dissection. The abdominoperineal resection was rapidly completed after the bleeding was controlled with surgical buffer. Then, hemostatic agents such as Spongostan™ and bone wax were used with primary suturing to control bleeding. However, pelvic packing was performed due to oozing bleeding which filled the pelvis, and the operation was terminated. Intraoperatively, 4000 cc of bleeding was detected. Hemodynamic parameters and laboratory results were improved after resuscitation, and the patient was operated for depacking at 24 h postoperatively. After the abdominal compresses were removed, bleeding restarted. The management approaches to control bleeding with sutures and other hemostatic agents failed. Then, a GORE-TEX® graft (W. L. Gore and Associates, Flagstaff,

Address for correspondence: Dr. Mustafa Ozsoy, Department of General Surgery, Parkhayat Hospital, Afyon 0300, Turkey.
E-mail: dr.mustafafozsoy@gmail.com

This is an open access journal, and articles are distributed under the terms of the Creative Commons Attribution-NonCommercial-ShareAlike 4.0 License, which allows others to remix, tweak, and build upon the work non-commercially, as long as appropriate credit is given and the new creations are licensed under the identical terms.

For reprints contact: reprints@medknow.com

How to cite this article: Ozsoy M, Ozsoy Z, Sahin S, Arikan k. An alternative technique in the control of massive presacral rectal bleeding: Fixation of GORE-TEX® aortic patch. Niger J Surg 2018;24:60-2.

Access this article online

Quick Response Code:



Website: www.nigerianjsurg.com

DOI: 10.4103/njs.NJS_36_17

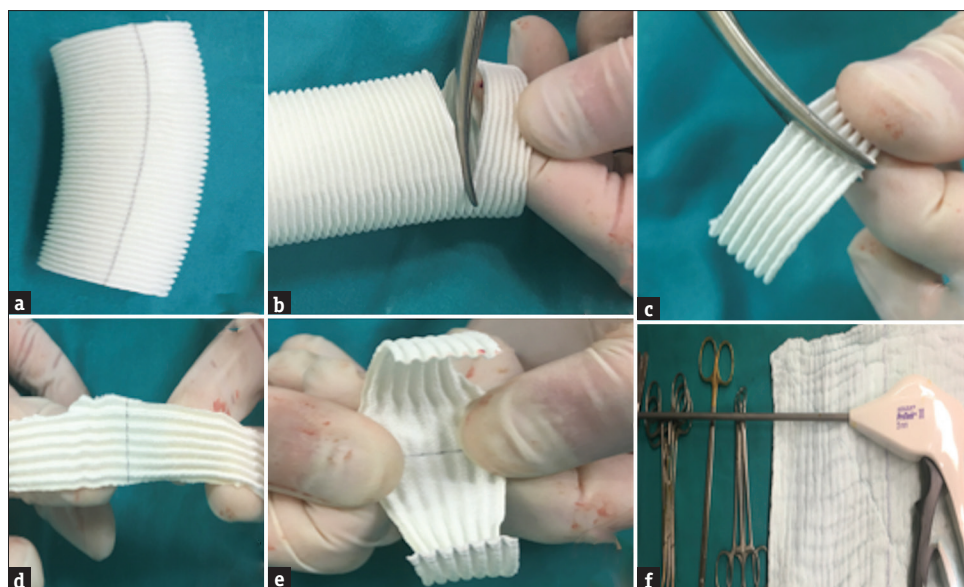


Figure 1: An aortic GORE-TEX® graft being converted into the presacral fascia patch and laparoscopic fixation device (a-f)

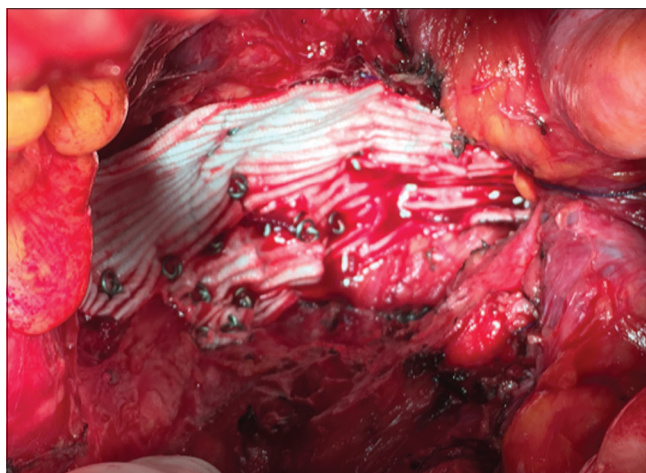


Figure 2: The appearance of new presacral fascia after the fixation of the GORE-TEX® patch

Ariz, USA) was provided. The graft was divided into two halves and made into a flat patch of 8 cm × 5 cm [Figure 1]. The mesh which was prepared with the fixation device (Autosuture ProTack, Norwalk, CT, USA), used for mesh fixation in laparoscopic hernia surgery, was tensely fixed to the sacrum [Figure 2]. As a result, bleeding control was achieved by obtaining a fascia-like layer, replacing the pelvic fascia and producing a tense pressure. The patient was discharged with healing in the postoperative 5th day.

DISCUSSION

Massive presacral bleedings are divided into two depending on the origin of the bleeding. The first one is the bleeding from the presacral plexus. The other is bleeding originating from the basivertebral veins in the sacral neural foramen.^[2] Massive presacral bleedings are

encountered more frequently in large fixed tumors, in neoadjuvant chemoradiotherapy areas, and in recurrent rectal cancers. The factors related to surgeon can be considered an erroneous dissection plan and excessive traction. Clinical presentation of presacral bleeding is often the case emerges suddenly during rectal mobilization which may lead patient up to be in a hemorrhagic shock condition. The amount of intraoperative bleeding published in the literature ranges from 300 cc to 7800 cc.^[3]

Several methods have been described to control presacral bleeding. The ligation of internal iliac artery is ineffective as well as leads necrosis of the bladder and gluteal region. The ligation of internal iliac veins may further exacerbate the bleeding by blocking venous return.^[4] Pelvic packing is the most commonly used technique. It is effective and lifesaving in the control of presacral bleeding. However, the packing has risks of pelvic sepsis secondary to the placement of foreign body into the abdomen, re-exposure to surgical stress, and bleeding.^[5] Bleeding from the presacral venous plexus can be stopped by suture ligation. The control with suture can only be performed in conditions where the presacral fascia is intact. However, inadequate field of view due to obesity, narrow pelvis, and intra-abdominal adhesions in patients undergoing surgery may result in failure of suture ligation. The placement of sutures according to typical venous confirmation may also fail due to variations in veins and communicating veins.^[6] The second type of bleeding originating from the basivertebral veins in the neural foramen is the type in which the bleeding control is most difficult. Metallic thumbtacks were first applied in basivertebral bleeding by Wang *et al.* in 1985, and the reliability has been proven in many studies. However,

it has complications such as difficulty in application in narrow pelvis, dislocation, chronic pain, anastomotic stenosis, and leakage.^[7] The free muscle fragment welding technique described by Harrison *et al.*^[8] is highly effective in the second type of bleeding. The free muscle flap is 1.5–2 cm in size, and the tampon is applied to the bleeding area with the help of a long Kelly clamp, and electrocautery is applied to form a coagulum. Thermal energy is transferred to the basivertebral system through this coagulum. Several studies have shown that hemostasis achieved with this technique is continuous and sufficient, and no complications, such as necrosis and abscess, have been reported. The hypervascular nature of the presacral area results in revascularization and epithelization of the coagulum with time.^[9]

CONCLUSION

An effective gold standard surgical treatment option for the control of presacral venous bleeding, which may result in fatal outcomes, has not been clearly established yet. Alternative treatment options come into question when the conventional techniques are inadequate. In our case, bleeding control could be achieved by forming a new presacral fascia layer as a result of the fixation of the patch, which was obtained from a GORE-TEX[®] graft, to the sacrum with a fixation device. We believe that this technique may be an alternative method both in open and laparoscopic surgery in the control of presacral plexus bleeding as it is cost-effective, easy-to-use, and available.

Consent

Written informed consent was obtained from patient who participated in this case.

Financial support and sponsorship

Nil.

Conflicts of interest

There are no conflicts of interest.

REFERENCES

1. Wang QY, Shi WJ, Zhao YR, Zhou WQ, He ZR. New concepts in severe presacral hemorrhage during proctectomy. *Arch Surg* 1985;120:1013-20.
2. Acheson AG, Brookes MJ, Spahn DR. Effects of allogeneic red blood cell transfusions on clinical outcomes in patients undergoing colorectal cancer surgery: A systematic review and meta-analysis. *Ann Surg* 2012;256:235-44.
3. Hata M, Kawahara N, Tomita K. Influence of ligation of the internal iliac veins on the venous plexuses around the sacrum. *J Orthop Sci* 1998;3:264-71.
4. Zama N, Fazio VW, Jagelman DG, Lavery IC, Weakley FL, Church JM, *et al.* Efficacy of pelvic packing in maintaining hemostasis after rectal excision for cancer. *Dis Colon Rectum* 1988;31:923-8.
5. Braley SC, Schneider PD, Bold RJ, Goodnight JE Jr., Khatri VP. Controlled tamponade of severe presacral venous hemorrhage: Use of a breast implant sizer. *Dis Colon Rectum* 2002;45:140-2.
6. Lacerda-Filho A, Duares LC, Santos HF. Displacement and per-anal extrusion of a hemostatic sacral thumbtack. *J Pelvic Med Surg* 2004;10:319-22.
7. Remzi FH, Oncel M, Fazio VW. Muscle tamponade to control presacral venous bleeding: Report of two cases. *Dis Colon Rectum* 2002;45:1109-11.
8. Harrison JL, Hooks VH, Pearl RK, Cheape JD, Lawrence MA, Orsay CP, Abcarian H. Muscle fragment welding for control of massive presacral bleeding during rectal mobilization: A review of eight cases. *Dis Colon Rectum* 2003;46:1115-7. [PMID: 12907909].
9. Germanos S, Bolanis I, Saedon M, Baratsis S. Control of presacral venous bleeding during rectal surgery. *Am J Surg* 2010;200:e33-5.