

## Original Article

# A Comparative Study of the Use of Harmonic Scalpel versus Unipolar Cautery in Modified Radical Mastectomy

Pallavi Mittal, Ashwani Kumar, Sunmeet Kaur<sup>1</sup>, Paras Kumar Pandove, Rachan Lal Singla, Jagpal Singh

Department of Surgery,  
Government Medical College  
and Rajindra Hospital,  
Patiala, Punjab, <sup>1</sup>Medical  
Student, All India Institute  
of Medical Sciences,  
New Delhi, India

### ABSTRACT

**Context:** Oncosurgery is an emerging branch with the set goals of prolonging the life and ensuring the best possible quality of life to the surviving patient. The use of harmonic scalpel has proved to be beneficial in a variety of surgeries but its role in breast surgery is still controversial. **Aims:** We conducted this study to compare the intraoperative and postoperative outcomes in modified radical mastectomy using harmonic scalpel versus electrocautery. **Subjects and Methods:** Fifty female patients with confirmed diagnosis of breast carcinoma and planned for modified radical mastectomy were taken up for surgery. Twenty-five patients were operated using harmonic scalpel (Group A) and another 25 were operated using unipolar cautery (Group B). **Results:** The mean operative time was significantly longer with harmonic scalpel when compared to that with electrocautery ( $140.40 \pm 29.96$  vs.  $99.80 \pm 24.00$  min,  $P < 0.001$ ). The smaller amount of drainage content ( $431.60 \pm 145.94$  vs.  $594.20 \pm 278.63$ ,  $P = 0.013$ ) and intraoperative blood loss ( $426.00 \pm 76.54$  vs.  $502.00 \pm 104.56$ ,  $P = 0.005$ ) in the group operated with the ultrasound harmonic scalpel was statistically significant. There was no significant difference between the groups with regard to drain duration ( $5.24 \pm 0.97$ ,  $P = 0.127$ ), seroma (12% vs. 16%,  $P = 0.684$ ), hematoma (4% vs. 4%,  $P = 1.000$ ), wound infection (24% vs. 32%,  $P = 0.529$ ), flap necrosis (8% vs. 28%,  $P = 0.066$ ), pain intensity (measured on visual analog scale) ( $5.08 \pm 1.29$  vs.  $5.20 \pm 1.68$ ,  $P = 0.778$ ), and lymphedema (4% vs. 8%,  $P = 0.552$ ). The length of hospital stay could not be compared effectively because all the patients were discharged on the 10<sup>th</sup> or 11<sup>th</sup> postoperative day. The cost of the equipment used in the electrocautery group was almost negligible as compared to the harmonic group. **Conclusions:** The use of harmonic scalpel versus electrocautery is somewhat advantageous but not cost-effective.

**KEYWORDS:** Harmonic scalpel, modified radical mastectomy, unipolar cautery

## INTRODUCTION

Breast cancer is the most site-specific cancer in women.<sup>[1]</sup> For patients who present late, radical mastectomy does not offer any advantage in terms of survival or cure. It only increases morbidity and decreases quality of life (because of “mutilation”). For patients who present early, modified radical mastectomy is the treatment of choice.<sup>[2]</sup> The main goals of cancer diagnosis and treatment are (i) to cure or considerably prolong the life of patients and (ii) to ensure the best

possible quality of life to the survivors. Nowadays, the most commonly used form of energy in modified radical mastectomy for raising flaps is monopolar diathermy. It is used to destroy tissue using conduction from a metal probe heated by electric current.<sup>[3,4]</sup> The ultrasonic surgical instrumentation was introduced into clinical

**Address for correspondence:** Dr. Pallavi Mittal,  
Department of Surgery, Ward No. 4, Government Medical  
College and Rajindra Hospital, Patiala - 147 001, Punjab, India.  
E-mail: [pallavi\\_mittal1988@yahoo.com](mailto:pallavi_mittal1988@yahoo.com)

### Access this article online

#### Quick Response Code:



**Website:** [www.nigerianjsurg.com](http://www.nigerianjsurg.com)

**DOI:** 10.4103/1117-6806.199962

This is an open access article distributed under the terms of the Creative Commons Attribution-NonCommercial-ShareAlike 3.0 License, which allows others to remix, tweak, and build upon the work non-commercially, as long as the author is credited and the new creations are licensed under the identical terms.

**For reprints contact:** [reprints@medknow.com](mailto:reprints@medknow.com)

**How to cite this article:** Mittal P, Kumar A, Kaur S, Pandove PK, Singla RL, Singh J. A comparative study of the use of harmonic scalpel versus unipolar cautery in modified radical mastectomy. *Niger J Surg* 2017;23:20-5.

practice nearly a decade ago in an effort to minimize the risks of traditional electrosurgical technologies, local peripheral energy damage, and potentially devastating complications associated with monopolar energy.<sup>[5]</sup> The harmonic scalpel denatures protein by ultrasonic vibration at a frequency of 55,500 Hz with a vibratory excursion of 50–100  $\mu\text{m}$ .<sup>[6]</sup>

In a study by Galatius *et al.*,<sup>[7]</sup> no significant difference was found in terms of operative time, intraoperative bleeding, and wound complications using both techniques.

In contrast, the study by Sanguinetti *et al.*<sup>[8]</sup> showed the benefits of the use of ultrasonic scissors compared to electrocautery. As literature is unclear about the best modality of raising the flaps in modified radical mastectomy, the main objective of this study was to evaluate the advantage of the harmonic scalpel in modified radical mastectomy in comparison with the traditional use of electrocautery (diathermy) for intraoperative and postoperative outcomes.

## SUBJECTS AND METHODS

### Data source

Fifty female patients with confirmed diagnosis of breast carcinoma and planned for modified radical mastectomy were taken up for surgery.

### Inclusion criteria

- Fine-needle aspiration cytology (FNAC)/ biopsy-proven operable breast carcinoma (primary or postneoadjuvant chemotherapy) female patients of all age groups, undergoing modified radical mastectomy with axillary lymph node dissection
- Tumor size >4 cm
- Patient who was not a candidate for breast conservation surgery (multicenter or diffuse tumor, tumor size >4 cm, large tumor in a small breast, patient preference)
- Positive margins after breast conservation surgery.

### Exclusion criteria

- Patients who did not give informed consent
- Patients who were unfit for general anesthesia
- Patients with inoperable advanced breast malignancies.

A detailed history of the patient was taken and a complete clinical examination of the patients was carried out. The clinical information such as age of the patient, age of menarche, age of menopause, parity of the patient, presence of any comorbidity such as diabetes mellitus and hypertension, size of the tumor, and presence of lymph nodes was recorded.

All the patients underwent routine investigations, liver function tests, chest X-ray, and ultrasound of the

abdomen. Diagnosis was confirmed by FNAC or trucut biopsy or incisional biopsy.

Informed consent was obtained from all the patients before surgery. Preanesthetic and medical fitness was assessed. Patients were enrolled into two groups by random selection; the first group (Group A) included 25 females who underwent modified radical mastectomy using harmonic scalpel (Ethicon Endo-Surgery, Inc., NJ, USA) and the second group (Group B) consisted of 25 females who underwent modified radical mastectomy using conventional electrocautery (unipolar cautery) by the same team of surgeons having an experience of at least 6 months of using both the harmonic scalpel and diathermy. It was done to rule out any learning curve if involved, in the use of harmonic scalpel as compared to cautery.

### Operative procedure

The operative procedure was conducted under general anesthesia. The time of starting of the surgery was noted. After the patient had been cleaned and draped, a skin incision was made with a conventional scalpel.

In Group A, the harmonic scalpel was used to raise skin flaps and carry out dissection of the breast tissue defined by the pectoralis major muscle below the clavicle superiorly, margin of the sternum medially, inframammary fold overlying the rectus abdominis inferiorly, and serratus anterior muscle to the latissimus dorsi muscle laterally. The instrument was also used to perform axillary dissection. Claviopectoral fascia was incised. The axillary vein was exposed. Only vessels larger than 5 mm in diameter were ligated with suture tie. A plane of dissection was created along the inferior border of the axillary vein, and all the fat, lymph nodes, and blood vessels were dissected off the axillary vein towards the breast. All axillary vein tributaries and artery branches directed towards the breast and pectoralis major muscle were ligated by the device. The thoracodorsal vessels and nerve and the long thoracic, subscapular nerves were identified and preserved.

In Group B, the whole procedure was performed using diathermy for both cutting (pure mode) and coagulation (fulguration mode), except for ligation of blood vessels bigger than 5 mm or when deemed necessary. The 2-0 silk sutures were used for vessel ligation. Two closed suction drains were placed: one in the axilla and the other on the chest wall. The skin was approximated using staples or sutures. Antiseptic dressing was done.

Operating time, considered as the time elapsed between the first incision and the last suture stitch (measured in minutes), was noted. Intraoperative blood loss was

estimated by calculating the amount of blood in the suction apparatus. Daily drainage was recorded (in ml). The drains were removed when the drainage amount was <30 ml/24 h. The drain on the chest wall was removed earlier than the one in the axilla. The duration of the drain (in days) was noted. The patients were given a stat dose of injection diclofenac sodium 75 mg through intramuscular route immediate postoperatively, followed by tablet diclofenac orally afterwards. Postoperative pain intensity was measured in every patient with a visual analog scale (VAS) by the end of the first 24 h. The patient marked a vertical line on a horizontal line marked “0” on the left side and “10” on the extreme right. Zero (0) indicated no pain and 10 indicated extreme pain.

The wound was inspected on day 2 of the postsurgery. Postoperative complications, which included seroma, hematoma, wound infection, flap necrosis, and upper limb lymphedema, were evaluated during the hospital stay and at follow-up. The patients were encouraged to ambulate early and begin arm stretches.

In the study, all patients with seroma formation settled down by multiple aspirations, with pressure bandage or open drainage within 1 month.

The patients with flap necrosis and wound infections were treated with antiseptic dressings, systemic and local antibiotics, and debridement. Wounds were later closed by secondary suturing. The patients with wound infection were treated with antibiotics according to culture and sensitivity reports and with sterilized daily dressing. As hematoma usually occurs as a result of improper hemostasis, it was avoided by fixation of flaps and suction drainage. The duration of hospital stay after surgery was noted. Figure 1 illustrates the consort flow diagram of the patients who participated. The follow-up of the patient was carried out till 1 month postsurgery.

A comparison was carried out between the two groups considering operative time, intraoperative blood loss, drain volume, drain duration, and incidence of postoperative complications such as seroma, hematoma, wound infection, flap necrosis, pain, upper limb lymphedema, length of hospital stay, and cost of the equipment used. All the data were recorded and analyzed statistically. An unpaired two-tailed Student’s *t*-test was used to compare two arithmetic means.  $\chi^2$ -test was used to compare two proportions or percentages. *P* < 0.05 was considered statistically significant.

## RESULTS

In this study as cited in Table 1, maximum number of patients (62%) were in the age group of 40–59 years.

On the basis of these statistics, it can be said that women of the middle age group are at a higher risk of developing breast cancer. In the present study, the mean age of the patients in harmonic scalpel group was  $50.36 \pm 11.04$  years and electrocautery group was  $52 \pm 11.19$  years, which was in concordance with some of the studies<sup>[9,10]</sup> as mentioned in Table 2.

Four percent of the patients were recorded with diabetes mellitus both in harmonic scalpel and electrocautery group. Incidence of hypertension in harmonic scalpel group was 12% and electrocautery group was 16% [Table 3].

The mean operative time was significantly longer in the group in which harmonic scalpel was used compared to that in which electrocautery was used [Table 4]. The smaller amount of drainage content and intraoperative blood loss in the group operated with the ultrasound harmonic scalpel was statistically significant. There was no significant difference regarding drain duration. There was no significant difference regarding seroma, hematoma, wound infection, pain intensity measured (on VAS), and lymphedema between the groups [Table 5]. Although the incidence of flap necrosis was less in harmonic scalpel group than in electrocautery group, the difference between the two groups was not statistically significant. Postoperative flap complications resulted in prolonged hospital stay. The cost of the cautery pencil was almost negligible (Rs. 150) as compared to the harmonic ace (Rs. 30,000 approximately).

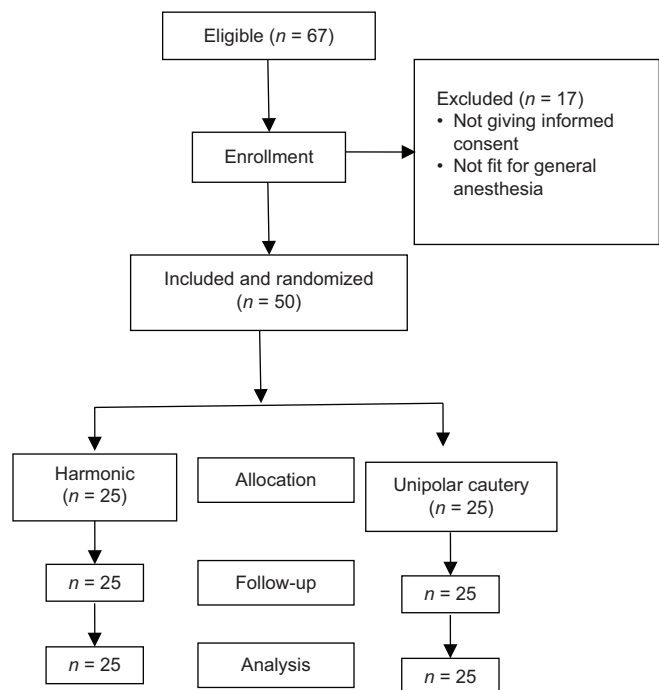


Figure 1: Consort flow diagram of participants

**Table 1: Age distribution among the breast carcinoma patients**

Age (years)	Number of patients	Percentage
30-39	07	14
40-49	15	30
50-59	16	32
60-69	07	14
70-79	05	10
Total	50	100
Mean±SD	51.18±11.03	

SD: Standard deviation

**Table 2: Age at diagnosis (in years)**

Author and year of study	Group A (harmonic scalpel)	Group B (electrocautery)
Present study	50.36±11.04	52±11.19
Deo and Shukla (2000) <sup>[9]</sup>	51±11	50±10
Khater (2010) <sup>[10]</sup>	54.47±7.57	56.27±9.05

**Table 3: Patients with comorbidities**

Comorbidity	Group A (harmonic scalpel) (%)	Group B (electrocautery) (%)	P
Diabetes mellitus	1/25 (4)	1/25 (4)	1.000 (NS)
Hypertension	3/25 (12)	5/25 (16)	0.684 (NS)
Any other	-	-	

NS: Not significant

**Table 4: Patient record**

Observations	Group A (harmonic scalpel)	Group B (electrocautery)	P
Operative time	140.40±29.96	99.80±24.00	<0.001 (HS)
Intraoperative blood loss	426.00±76.54	502.00±104.56	0.005 (HS)
Drain volume	431.60±145.94	594.20±278.63	0.013 (S)
Drain duration	5.24±0.97	5.76±1.36	0.127 (NS)
VAS	5.08±1.29	5.20±1.68	0.778 (NS)
Hospital stay (days)	14.32±9.82	19.04±34.18	0.621 (NS)

HS: Highly significant, NS: Not significant, S: Significant,

VAS: Visual analog scale

**Table 5: Postoperative wound complications**

Type of complication	Group A (harmonic scalpel) (%)	Group B (electrocautery) (%)	P*
Seroma	3/25 (12)	4/25 (16)	0.684
Hematoma	1/25 (4)	1/25 (4)	1.000
Wound infection	6/25 (24)	8/25 (32)	0.529
Flap necrosis	2/25 (8)	7/25 (28)	0.066
Lymphedema	1/25 (4)	2/25 (8)	0.552

\*Not significant

## DISCUSSION

Safety, efficiency, complications, recurrences, cost, and acceptance from the patients are the factors determining the success of a surgical procedure. Acceptance from the patients is determined by postoperative pain, length of hospital stay, and recovery rate as well as complications.<sup>[11]</sup> Hence, our experience regarding the use of harmonic scalpel versus the traditional use of electrocautery (diathermy) in modified radical mastectomy for intraoperative and postoperative outcomes has been discussed taking into account the various parameters.

In this study, the mean age of the patients who underwent modified radical mastectomy was 51.18 years, which was in concordance with some of the earlier studies.<sup>[9,10]</sup> Our study showed the higher incidence of breast carcinoma in middle-aged group. Siddiqui *et al.*<sup>[12]</sup> and Baloch and Iqbal<sup>[13]</sup> also found the disease to be most common in middle-aged patients (40–59 years). This can be explained by the fact that breast cancer is a heterogeneous malignancy; its age-specific incidence profile rises exponentially until menopause and increases more slowly thereafter.<sup>[14]</sup>

The mean operative time in our study was significantly longer using harmonic scalpel (140.4 vs. 99.8 min,  $P < 0.001$ ). Our results were in contrast to the study conducted by Kiyangi *et al.*<sup>[15]</sup> and Huang *et al.*<sup>[16]</sup> which showed no statistically significant difference. Our results were also similar to the study conducted by Rohaizak *et al.*<sup>[17]</sup> and Khan *et al.*<sup>[18]</sup> Rohaizak *et al.*<sup>[17]</sup> said that this could be explained by the lack of experience in using the ultracision. Böhm *et al.*<sup>[19]</sup> conducted similar study that exposed the surgeon to the technique for 5 months before the study and managed to show no significant difference in operating time between ultrasonic surgery and conventional device. Our study showed longer operative time using harmonic scalpel in spite of prior training.

We infer that the harmonic scalpel takes slightly longer than cautery to divide the tissue as it cuts and coagulates at the same time. This calls for patience and avoidance of undue traction on the surgical specimen, which is almost instinctive reaction to the slower rate of cutting.<sup>[20]</sup>

Our study revealed that the use of the harmonic scalpel significantly reduces intraoperative blood loss (426.00 ± 76.54 vs. 502 ± 104.56,  $P = 0.005$ ). This is in agreement with most of the studies, for example, by Deo and Shukla,<sup>[9]</sup> Kozomara *et al.*,<sup>[21]</sup> Khan *et al.*,<sup>[18]</sup> and Huang *et al.*<sup>[16]</sup> The harmonic scalpel provides a better hemostasis with less lateral thermal injury; thus,

undesirable injury is avoided when it is used, resulting in lesser intraoperative blood loss.<sup>[22]</sup>

Drains are placed to help check complications such as hematoma, seroma, and flap necrosis as a result of sequelae to seroma. Electrocoagulation causes sloppy lymphostasis and hemostasis and increases morbidity by severing and thermally injuring lymph pathways as well as by forming hematoma.<sup>[23]</sup> The harmonic scalpel, on the other hand, generates ultrasonic energy, which causes a breakage of hydrogen bonds and formation of denatured protein coagulum, thus sealing off the vessels and lymphatics and resulting in decreased blood loss and lymphatic drainage.<sup>[9]</sup> Moreover, the inflammatory reaction in the operative field is reduced, less lymphatic tissues are injured, and less oozing surface is produced in the operative field.<sup>[22]</sup> All these factors contributed in reducing the postoperative drainage volume in our study.

A statistically insignificant difference was found in relation to drain volume, which is contradictory to results by Deo and Shukla,<sup>[9]</sup> who showed significant lowering of drain days in harmonic scalpel group. Studies by Khan *et al.*<sup>[18]</sup> and Huang *et al.*<sup>[16]</sup> also showed significant difference in drainage volume. The drain volume curve was steeper in case of electrocautery group compared to harmonic scalpel group.

Our study showed that the harmonic scalpel decreases the rate of occurrence of seroma than electrocautery (12% in harmonic scalpel group vs. 16% in electrocautery group); however, the difference was statistically insignificant. Porter *et al.*<sup>[23]</sup> found that the use of electrocautery was significantly associated with increased seroma formation in a randomized controlled trial. As the difference in drain volume was significant among the two groups, the study showed comparable results in relation to seroma formation, which might have been prevented due to the placement of drains in every single case. Thus, it can be concluded that harmonic scalpel can effectively occlude lymphatic channels.

In our study, 4% of patients were reported with hematoma in both harmonic scalpel and electrocautery groups. The difference between the two groups was statistically insignificant ( $P = 1.000$ ). However, intraoperative blood loss was significantly less in case of harmonic scalpel group, proving its effective hemostasis.

This study showed statistically insignificant value in terms of incidence of wound infection between the groups. Similar results have been shown in studies by Kozomara *et al.*,<sup>[21]</sup> Ribeiro *et al.*,<sup>[24]</sup> and Rohaizak *et al.*<sup>[17]</sup> Infection was more common in patients who developed seroma, hematoma, or flap necrosis.

Flap necrosis either develops as sequelae to continued abnormal vascularity or develops primarily.<sup>[25]</sup> The seroma may become infected and cause flap necrosis.<sup>[26]</sup> Very thin flaps tend to develop necrosis; therefore, one should try to raise the flap with an approximately 0.5 cm thick layer of subcutaneous tissue. In our study, flap necrosis was found in 8% patients in harmonic scalpel group and 28% patients in electrocautery group; however, the  $P$  value between the groups was 0.066, which was not statistically significant. Hence, from this, we can infer that the ultracision causes lesser thermal tissue injury, leading to lesser chances of flap necrosis. However, in a study by Huang *et al.*,<sup>[16]</sup> a significant difference was observed in terms of wound complications between the two groups.

At 24 h, VAS score of Group A was compared with that of Group B. The value was not statistically significant and was similar to that shown in the study by Kozomara *et al.*<sup>[21]</sup> In a study by Khater,<sup>[10]</sup>  $P < 0.001$  (highly significant) indicated statistically significant lower pain in the harmonic group. This was due to the minimal lateral thermal damage observed with harmonic scalpel in comparison with electrocautery, resulting in less irritation to pain nerve endings.<sup>[10]</sup> This contradiction in results can be because pain estimation is subjective and varies from patient to patient.

The hospital stay was counted from the 1<sup>st</sup> postoperative day. In this study, the length of hospital stay was not reduced as most of our patients were discharged after the first cycle of adjuvant chemotherapy, probably the 10<sup>th</sup> or 11<sup>th</sup> postoperative day as per our unit protocol. Hence, the length of hospital stay could not be compared effectively in our study.

The difference in the incidence of lymphedema between the two groups was not statistically significant ( $P = 0.552$ ). However, these results should be carefully evaluated as lymphedema takes longer time to develop after surgery. One limitation of our study is its shorter period of follow-up, so we cannot comment on the frequency of lymphedema in both the groups.

## CONCLUSION

Ultracision in comparison to electrocautery is somewhat but not fully advantageous and miraculous. No doubt it causes effective hemostasis and lymphostasis, but its use in modified radical mastectomy is still not cost effective and so, not recommended to be used in countries where cost is a major concern.

## Financial support and sponsorship

Nil.

## Conflicts of interest

There are no conflicts of interest.

## REFERENCES

1. Brunicardi F, Andersen D, Billiar T, Dunn D, Hunter J, Matthews J, *et al.* The breast. In: Schwartz's Principles of Surgery. 9<sup>th</sup> ed. New York: McGraw-Hill; 2009. p. 440-1.
2. Kuraparthi S, Reddy KM, Yadagiri LA, Yutla M, Venkata PB, Kadainti SV, *et al.* Epidemiology and patterns of care for invasive breast carcinoma at a community hospital in Southern India. *World J Surg Oncol* 2007;5:56.
3. Odel RC. Laparoscopic electrocautery. In: Hunter JG, Sackier JM, editors. Minimally Invasive Surgery. New York: McGraw-Hill; 1993. p. 33-41.
4. Voyles CR, Tucker RD. Education and engineering solutions for potential problems with laparoscopic monopolar electrocautery. *Am J Surg* 1992;164:57-62.
5. Matthews B, Nalysnyk L, Estok R, Fahrback K, Banel D, Linz H, *et al.* Ultrasonic and nonultrasonic instrumentation: A systematic review and meta-analysis. *Arch Surg* 2008;143:592-600.
6. Foschi D, Cellerino P, Corsi F, Taidelli T, Morandi E, Rizzi A, *et al.* The mechanisms of blood vessel closure in humans by the application of ultrasonic energy. *Surg Endosc* 2002;16:814-9.
7. Galatius H, Okholm M, Hoffmann J. Mastectomy using ultrasonic dissection: Effect on seroma formation. *Breast* 2003;12:338-41.
8. Sanguinetti A, Docimo G, Ragusa M, Calzolari F, D'Ajello F, Ruggiero R, *et al.* Ultrasound scissors versus electrocautery in axillary dissection: Our experience. *G Chir* 2010;31:151-3.
9. Deo SV, Shukla NK. Modified radical mastectomy using harmonic scalpel. *J Surg Oncol* 2000;74:204-7.
10. Khater A. Harmonic scalpel as a single instrument in modified radical mastectomy. Is it more cost effective than electrocautery and ligature? *Egypt J Surg* 2010;29:959-62.
11. Baigrie RJ, Lamont PM, Kwiatkowski D, Dallman MJ, Morris PJ. Systemic cytokine response after major surgery. *Br J Surg* 1992;79:757-60.
12. Siddiqui MS, Kayani N, Sulaiman S, Hussainy AS, Shah SH, Muzaffar S. Breast carcinoma in Pakistani females: A morphological study of 572 breast specimens. *J Pak Med Assoc* 2000;50:174-7.
13. Baloch TA, Iqbal P. Breast carcinoma in Karachi: Clinical and pathological features. *Med Channel* 2006;12:47-8.
14. Benz CC. Impact of aging on the biology of breast cancer. *Crit Rev Oncol Hematol* 2008;66:65-74.
15. Kiyangi AK, Macdonald LJ, Shugg SA, Bollard RC. Harmonic dissection versus electrocautery in breast surgery in regional Victoria. *ANZ J Surg* 2015;85:358-62.
16. Huang J, Yu Y, Wei C, Qin Q, Mo Q, Yang W. Harmonic scalpel versus electrocautery dissection in modified radical mastectomy for breast cancer: A meta-analysis. *PLoS One* 2015;10:e0142271.
17. Rohaizak M, Khan FJ, Jasmin JS, Mohd Latar NH, Abdullah SS. Ultracision versus electrocautery in performing modified radical mastectomy and axillary lymph node dissection for breast cancer: A prospective randomized control trial. *Med J Malaysia* 2013;68:204-7.
18. Khan S, Khan S, Chawla T, Murtaza G. Harmonic scalpel versus electrocautery dissection in modified radical mastectomy: A randomized controlled trial. *Ann Surg Oncol* 2014;21:808-14.
19. Böhm D, Kubitz A, Lebrecht A, Schmidt M, Gerhold-Ay A, Battista M, *et al.* Prospective randomized comparison of conventional instruments and the Harmonic Focus® device in breast-conserving therapy for primary breast cancer. *Eur J Surg Oncol* 2012;38:118-24.
20. Armstrong DN, Ambrose WL, Schertzer ME, Orangio GR. Harmonic scalpel vs. electrocautery hemorrhoidectomy: A prospective evaluation. *Dis Colon Rectum* 2001;44:558-64.
21. Kozomara D, Galic G, Brekalo Z, Sutalo N, Kvesic A, Soljic M. A randomised two-way comparison of mastectomy performed using harmonic scalpel or monopolar diathermy. *Coll Antropol* 2010;34 Suppl 1:105-12.
22. Burak WE Jr., Goodman PS, Young DC, Farrar WB. Seroma formation following axillary dissection for breast cancer: Risk factors and lack of influence of bovine thrombin. *J Surg Oncol* 1997;64:27-31.
23. Porter KA, O'Connor S, Rimm E, Lopez M. Electrocautery as a factor in seroma formation following mastectomy. *Am J Surg* 1998;176:8-11.
24. Ribeiro GH, Kerr LM, Haikel RL, Peres SV, Matthes AG, Depieri Michelli RA, *et al.* Modified radical mastectomy: A pilot clinical trial comparing the use of conventional electric scalpel and harmonic scalpel. *Int J Surg* 2013;11:496-500.
25. Hongying WU, Shan ZC, Thakuri B. Origin and countermeasure for common skin flap complications after radical operation for breast cancer. *Kathmandu Univ Med J (KUMJ)* 2006;4:14-7.
26. Aitken DR, Hunsaker R, James AG. Prevention of seromas following mastectomy and axillary dissection. *Surg Gynecol Obstet* 1984;158:327-30.