

# A Rare Presentation of Lower Back Swelling as Tailgut Cyst

Prem Chand, Simmi Bhatnagar<sup>1</sup>, Ashok Kumar, Nisha Rani

Departments of General Surgery and <sup>1</sup>Radiodiagnosis, Government Medical College, Patiala, Punjab, India

## ABSTRACT

Retrorectal cystic hamartoma, also known as tailgut cyst, is a rare congenital developmental lesion arising from postnatal primitive gut remnants in the retrorectal space. The rarity of the lesion and its anatomical position usually leads to difficulty in diagnosis and surgical management. This cyst predominantly occurs in women (female to male ratio, 3:1). Tailgut cysts can present as incidental findings during the routine examination but over half of the patients are thought to present with symptoms. Computed tomography or magnetic resonance imaging has a crucial role in diagnosing these misdiagnosed cysts. Complete surgical excision is the treatment of choice for tailgut cysts as this provides a definitive diagnosis, relieves symptoms, and prevents possible complications such as infection, fistula formation, and malignant degeneration. We present a case of a 40-year-old female, who presented to us with lower back swelling (7 cm × 5 cm) for last 2 years, which had become more prominent to her while sitting. The patient was investigated. Ultrasonography demonstrated ill-defined large cystic lesion (8 cm × 7 cm), posterior to the uterus. Fine needle aspiration cytology suggested sebaceous cyst. A lumbosacral contrast-enhanced computed tomography demonstrated well-defined fluid density mass/collection with enhancing walls in the retrorectal, presacral, precoccygeal area, and suggested tailgut duplication cyst/retrorectal cystic hamartoma. Surgical complete excision of the cystic mass was done with both anterior (transabdominal) and posterior approach. Histopathology confirmed a tailgut cyst.

**KEYWORDS:** Retrorectal cystic hamartoma, retrorectal space, surgical management, tailgut cyst, trans-abdominal approach

## INTRODUCTION

Tailgut cysts, also known as retrorectal cystic hamartomas, are rare congenital developmental lesions arising from postnatal primitive gut remnants, that generally occur in the retrorectal space,<sup>[1]</sup> but have also been described in prerectal<sup>[1]</sup> and perirenal<sup>[2]</sup> locations. The retrorectal space is a potential space bound anteriorly by the mesorectum and posteriorly by the sacrum. The superior border is formed by the peritoneal reflection while the inferior border is formed by the rectosacral fascia. The lateral borders of the retrorectal space are formed by the ureters, the iliac vessels, the sacral nerve roots, and the lateral stalks of the rectum.<sup>[3]</sup> The retrorectal space contains loose connective tissue, the middle sacral, ilio-lumbar and middle hemorrhoidal vessels, branches

### Address for correspondence:

Dr. Prem Chand,  
Department of General Surgery, Government Medical College,  
Patiala - 147 001, Punjab, India.  
E-mail: premchandsingl@gmail.com

### Access this article online

<b>Quick Response Code:</b>	<b>Website:</b> www.nigerianjsurg.com
	<b>DOI:</b> ***

of the sympathetic and parasympathetic nervous systems, and lymphatics.<sup>[4]</sup> The anatomical position and rarity of the lesion lead to difficulty first in diagnosis (the lesion is often misdiagnosed) and second in surgical management (the condition is often suboptimally managed).<sup>[5]</sup> These tailgut cysts predominantly occur in women, with average age of presentation at 35 years. Retrorectal tumors are frequently asymptomatic and are found incidentally during evaluation for unrelated physical complaints.<sup>[5,6]</sup> Half of the patients present with symptoms such as low back or rectal pain, pain during defecation, rectal bleeding, urinary frequency, etc.<sup>[7]</sup> Furthermore, retrorectal lesions in women can mimic gynecological pathology, and the risk of malignant transformation of a tailgut cyst always exists. Despite that, the role of preoperative biopsy for retrorectal tumors is very controversial,<sup>[8]</sup> but most authors agree that it can be a more harmful than a useful option. This is why preoperative high-resolution modern imaging techniques (pelvic computed tomography [CT] or magnetic resonance imaging [MRI]) play such a crucial role in differential diagnostics between retrorectal tumors and planning the surgical management of retrorectal lesions,

This is an open access article distributed under the terms of the Creative Commons Attribution-NonCommercial-ShareAlike 3.0 License, which allows others to remix, tweak, and build upon the work non-commercially, as long as the author is credited and the new creations are licensed under the identical terms.

For reprints contact: reprints@medknow.com

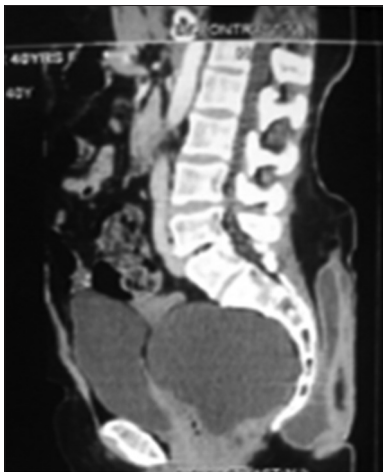### How to cite this article: \*\*\*

including tailgut cysts. Complete surgical resection with negative margins still remains the cornerstone of surgical treatment, as this eliminates the potential of recurrence, hemorrhage, infection, compression, and malignant changes.<sup>[9]</sup>

## CASE REPORT

A 40-year-old female was referred to our institution with the history of lower back swelling since 2 years. Swelling had become more prominent to her while sitting. She had recurring constipation since last 1 year which was relieved by laxatives. She consulted a surgeon, at some regional hospital, about 1 year back, who misdiagnosed it to be an abscess. The swelling was subjected to incision and drainage, at that regional hospital, but without any success.

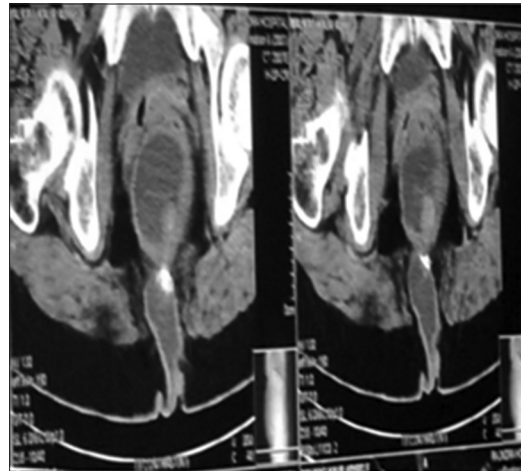
Later on, the patient was referred to us, ultrasonography for pelvic organs demonstrated ill-defined large cystic lesion 8 cm × 7 cm, posterior to the uterus. The margins could not be well defined due to distal acoustic shadowing of adjacent gut loops. Fine needle aspiration cytology reported the possibility of sebaceous cyst.



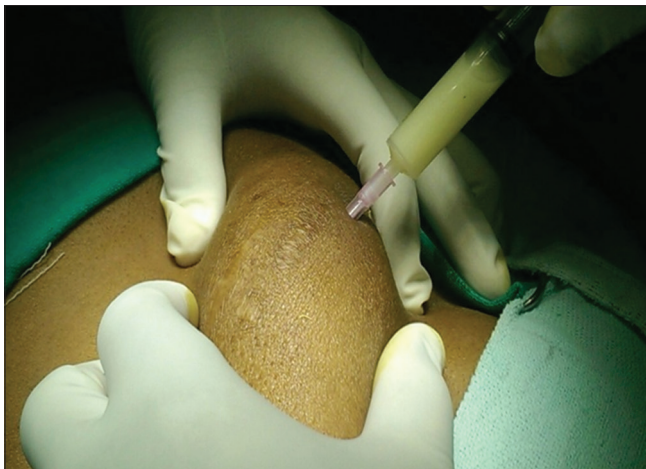**Figure 1:** Bilobed retrorectal cyst

A lumbosacral contrast-enhanced CT (CECT) [Figures 1 and 2], demonstrated a well-defined fluid density mass/collection with enhancing walls in the retrorectal, presacral, precoccygeal area, measuring (7.9 cm × 11.2 cm × 11.5 cm), with anterolateral displacement of rectum to left side, extending posterior to sacrum and coccyx through the infracoccygeal region forming a fluid collection with enhancing walls (4.5 cm × 4.8 cm × 13.5 cm). Fat strandings were seen in overlying subcutaneous tissue. No lytic/sclerotic lesions were seen in the lumbosacral spine. CECT report suggested the lesion most likely to represent tailgut duplication cyst/retrorectal cystic hamartoma.

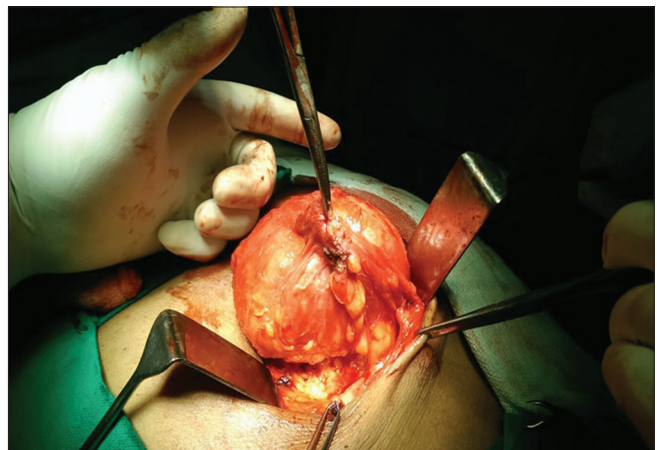
Following discussion, it was decided that surgical excision of this lesion was the most appropriate course of action given its symptomatology and uncertain malignant potential. The procedure was commenced in the prone position. A vertical incision was given over the swelling on the sacrococcygeal area, facilitated en bloc removal of the sacrococcygeal cystic mass [Figures 3 and 4]. This component was communicating with the retrorectal swelling. The latter required a trans-abdominal approach through lower midline vertical incision. The peritoneum overlying the pelvic brim was incised posterolaterally, and the



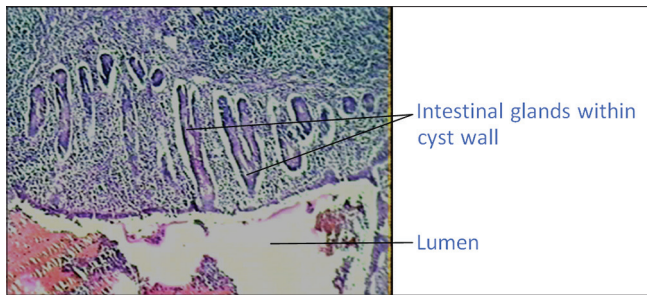
**Figure 2:** Axial view of retro-rectal/tailgut cyst



**Figure 3:** Previous scar of incision and drainage, and mucoïd color fluid on aspiration of cyst



**Figure 4:** Surgical excision of cyst from the posterior approach



**Figure 5:** Histopathology showing intestinal glands within cyst wall confirming tailgut cyst (H and E,  $\times 100$ )

mesorectal plane was entered. Dissection was continued in a caudal direction. The rectum was fully mobilized, allowing the cyst, which was adherent to it, to also be mobilized and removed intact. The rectal wall was not breached, and the presacral fascia was fully intact.

Histopathology revealed a multiloculated tailgut cyst containing abundant mucoid material lined by glandular mucinous epithelium with fibrous tissue and showing intestinal glands [Figure 5], with no evidence of malignancy. The patient had an uneventful postoperative course with complete resolution of her swelling. She remains well at 1-year follow-up with no evidence of recurrence on serial pelvic imaging.

## DISCUSSION

Embryologically, tailgut cysts are believed to arise from vestigial remnants of the embryonic hindgut. The largest reported case series of 53 tailgut cysts over a 35-year period from 1950 to 1985 was described by Hjerstad and Helwig.<sup>[6]</sup> They found that these cysts predominantly occurred in women (female to male ratio, 3:1). The ages ranged from 4 days to 73 years with an average age of presentation at 35 years. Tailgut cysts are usually asymptomatic in adults.<sup>[5]</sup> Symptoms only occur due to the local mass effect on surrounding organs (rectal fullness, constipation, painful defecation, lower abdominal and/or back pain or genitourinary obstruction (dysuria)), infection (cysts with secondary infection have typical symptoms of anorectal or pelvic abscess and fistula, or perianal sinus),<sup>[10]</sup> bleeding or malignant transformation/degeneration (pain in the anorectal region).<sup>[11]</sup> Retrorectal cystic hamartomas in the presacral space are usually well-defined, thin-walled and multicystic or unilocular.<sup>[11]</sup> Despite the fact that the majority of tailgut cysts are benign, and can very rarely undergo malignant transformation<sup>[10,11]</sup> and then most common histopathologic diagnoses are adenocarcinoma or carcinoid.<sup>[11]</sup> Most lesions were multicystic, and the average diameter was 3.9 cm. They were lined by a variety of epithelia which varied not only among multiple cysts of multicystic lesions but also within the same cyst. The contents varied from clear fluid to dense mucous. Due to the location of tailgut cysts, almost all of them are palpable on rectal examination as extrinsic, contained; fluctuant masses.<sup>[5,8]</sup> The differential diagnoses can be classified as congenital, neurogenic, osseous, miscellaneous, and inflammatory.

Excluding inflammatory processes, congenital lesions account for approximately two-thirds of retrorectal lesions.<sup>[5]</sup> These include developmental cysts, chordomas (remnants of notochord), and anterior sacral meningoceles. Developmental cysts can be further divided according to their origin and histopathological features into tailgut cysts, enteric duplication cysts, dermoid cysts, epidermoid cysts, and teratomas.<sup>[8,10]</sup>

Plain films, for investigation of presacral masses, are of limited use but may show evidence of bony destruction suggesting malignancy or an osseous lesion. Rarely, they may identify a sacrococcygeal anomaly associated with tailgut cysts. Transrectal ultrasound may be useful in demonstrating the integrity of the layers of the rectum as well as revealing a cystic lesion and clarifying whether it is unilocular or multilocular. Occasionally it shows internal echoes due to the mucoid material or inflammatory debris.<sup>[11,12]</sup> The appearance of a tailgut cyst on CT imaging is usually of a well-defined, thin-walled, uni- or multi-locular, nonenhancing lesion in the retrorectal space. Calcification does not tend to be a feature of tailgut cysts but has been reported and if present may suggest the possibility of malignancy.<sup>[11,12]</sup> In our case, we did not get MRI scan done as it was quite obvious on CT scan. MRI has become the modality of choice to image tailgut cysts because of its multiplanar imaging capability (allowing imaging of surgically relevant planes) as well as its good soft tissue contrast. MRI typically demonstrates a retrorectal lesion with low signal intensity on T1-weighted images and high signal intensity on T2 weighted images although this may vary depending on cyst content. Malignancy is suspected if there is focal irregular wall thickening and intermediate signal intensity before contrast on both T1- and T2-weighted images with enhancement after contrast.<sup>[12,13]</sup> Historically, the classical treatment in this area consists of different approaches: The anterior (transabdominal), the posterior approaches (inter-sphincteric, trans-sphincteric parasacrococcygeal, trans-sacral, trans-sacrococcygeal, trans-anorectal, and transvaginal).<sup>[10,14]</sup> In the current case, combined approach (posterior and then trans-abdominal) was undertaken as the lesion could not be removed solely from posterior approach due to large retrorectal component and adhesions with the rectum. On follow-up, the patient was relieved of discomfort, constipation, and swelling. Patient has been advised to visit hospital 3–6 monthly for the 1<sup>st</sup> year and yearly after that or if any fresh complaints appear. There is no standard recommendation for the follow-up of tailgut cysts in the literature. Follow-up of this rare condition should, therefore, be clinical and case specific. If the patient develops symptomatology, targeted cross-sectional imaging should be instituted. In the presence of abnormal histology, serial perineal examination, and cross-sectional imaging are advised.

## CONCLUSION

The anatomical position and rarity of the tailgut cyst lead to difficulty firstly in diagnosis (the lesion is often misdiagnosed) and secondly in surgical management



(the condition is often suboptimally managed).<sup>[5]</sup> Surgical excision is the treatment of choice for tailgut cysts as this provides a definitive diagnosis, relieves symptoms, and prevents possible complications such as infection, fistula formation, and malignant degeneration.<sup>[12]</sup> Preoperative imaging with CT or MRI is essential to plan the most appropriate surgical approach. One should be very alert while separating cyst from the rectal wall so as to prevent inadvertent injury to the rectum.

### Financial support and sponsorship

Nil.

### Conflicts of interest

There are no conflicts of interest.

### REFERENCES

- Jang SH, Jang KS, Song YS, Min KW, Han HX, Lee KG, *et al.* Unusual prerectal location of a tailgut cyst: A case report. *World J Gastroenterol* 2006;12:5081-3.
- Sung MT, Ko SF, Niu CK, Hsieh CS, Huang HY. Perirenal tailgut cyst (cystic hamartoma). *J Pediatr Surg* 2003;38:1404-6.
- Hassan I, Wietfeldt ED. Presacral tumors: Diagnosis and management. *Clin Colon Rectal Surg* 2009;22:84-93.
- Ghosh J, Eglinton T, Frizelle FA, Watson AJ. Presacral tumours in adults. *Surgeon* 2007;5:31-8.
- Lin C, Jin K, Lan H, Teng L, Lin J, Chen W. Surgical management of retrorectal tumors: A retrospective study of a 9-year experience in a single institution. *Onco Targets Ther* 2011;4:203-8.
- Hjermstad BM, Helwig EB. Tailgut cysts. Report of 53 cases. *Am J Clin Pathol* 1988;89:139-47.
- Joyce EA, Kavanagh DO, Winter DC. A rare cause of low back pain: Report of a tailgut cyst. *Case Rep Med* 2012;2012:623142.
- Neale JA. Retrorectal tumors. *Clin Colon Rectal Surg* 2011;24:149-60.
- Killingsworth C, Gadacz TR. Tailgut cyst (retrorectal cystic hamartoma): Report of a case and review of the literature. *Am Surg* 2005;71:666-73.
- Rosa G, Lolli P, Vergine M, El-Dalati G, Malleo G. Surgical excision of developmental retrorectal cysts: Results with long-term follow-up from a single institution. *Updates Surg* 2012;64:279-84.
- Doyle D, Wyse G, Casey M, Kelly D. Answer to case of the month #109. Retrorectal cystic hamartoma. *Can Assoc Radiol J* 2006;57:179-81.
- Au E, Anderson O, Morgan B, Alarcon L, George ML. Tailgut cysts: Report of two cases. *Int J Colorectal Dis* 2009;24:345-50.
- Dahan H, Arrivé L, Wendum D, Docou le Pointe H, Djouhri H, Tubiana JM. Retrorectal developmental cysts in adults: Clinical and radiologic-histopathologic review, differential diagnosis, and treatment. *Radiographics* 2001;21:575-84.
- Hannon J, Subramony C, Scott-Conner CE. Benign retrorectal tumors in adults: The choice of operative approach. *Am Surg* 1994;60:267-72.