

Comparative Efficacy of Amoxicillin/Clavulanic Acid and Levofloxacin in the Reduction of Postsurgical Sequelae After Third Molar Surgery: A Randomized, Double-Blind, Clinical Trial in a Nigerian University Teaching Hospital

Kizito Chioma Ndukwe, Ramat Oyebunmi Braimah¹, John Foluso Owotade, Stephen Babatunde Aregbesola

Department of Oral and Maxillofacial Surgery and Oral Pathology, Obafemi Awolowo University Teaching Hospitals Complex, Ile-Ife, Osun State, ¹Department of Dental and Maxillofacial Surgery, Usmanu Danfodio University Teaching Hospital, Sokoto, Nigeria

ABSTRACT

Background: The most common sequelae after surgical removal of mandibular third molar are pain, trismus, swelling, and dysphagia. However, these symptoms can also signal the onset of surgical site infection and alveoli osteitis. The aim of this study was to evaluate the efficacy of prophylactic amoxicillin/clavulanic acid and levofloxacin and preemptive therapy of amoxicillin/clavulanic acid in the reduction of postinflammatory complications, surgical site infection, and alveolar osteitis following the third molar surgery. **Patients and Methods:** A total of 135 patients were randomized into three equal groups: Group A (preemptive therapy of amoxicillin/clavulanic acid) with preoperative dose of 875/125 mg amoxicillin/clavulanic acid followed by 500/125 mg amoxicillin/clavulanic acid 12 hourly for 5 days, Group B (amoxicillin/clavulanic acid prophylaxis) with a single preoperative dose of amoxicillin/clavulanic acid 875/125 mg tablets, and Group C (levofloxacin prophylaxis) with a single preoperative dose of levofloxacin 1000 mg tablets. All patients had ostectomy using surgical handpiece and burs and received same analgesics (tabs ibuprofen 400 mg 8 hourly for 3 days). **Results:** No case of surgical site infection or alveoli osteitis was recorded in the study groups. There were no statistically significant differences between the treatment groups with regard to pain, mouth opening, postoperative facial dimension, and body temperature. **Conclusion:** Amoxicillin/clavulanic acid as a single preoperative bolus should be adequate for the prevention of postoperative wound infection and alveoli osteitis following the third molar extraction as there is no need for an extension of the antibiotic. Moreover, levofloxacin can be utilized as prophylaxis in patients undergoing mandibular third molar extraction if such patients are allergic to penicillins.

KEYWORDS: Antibiotics, complications, third molar surgery

Address for correspondence:

Dr. Ramat Oyebunmi Braimah,
Department of Dental and Maxillofacial Surgery, Usmanu Danfodio
University Teaching Hospital, Sokoto, Nigeria.
E-mail: robdeji@yahoo.com

Access this article online

Quick Response Code:



Website: www.nigerianjsurg.com

DOI:
10.4103/1117-6806.179830

INTRODUCTION

Extraction of the impacted third molar is one of the most common minor oral surgical procedures carried out in oral surgery.^[1] It is classified as a clean-contaminated surgery with infection rates reported to be between 1.2% and 27%.^[2,3] Pain, swelling, and trismus occur as immediate physiologic sequelae of the third molar surgery.^[4-6] These clinical features can also signal

This is an open access article distributed under the terms of the Creative Commons Attribution-NonCommercial-ShareAlike 3.0 License, which allows others to remix, tweak, and build upon the work non-commercially, as long as the author is credited and the new creations are licensed under the identical terms.

For reprints contact: reprints@medknow.com

How to cite this article: Ndukwe KC, Braimah RO, Owotade JF, Aregbesola SB. Comparative efficacy of amoxicillin/clavulanic acid and levofloxacin in the reduction of postsurgical sequelae after third molar surgery: A randomized, double-blind, clinical trial in a Nigerian University Teaching Hospital. *Niger J Surg* 0;0:0.

the onset of alveolar osteitis and surgical site infection.^[7,8] Other complications are permanent nerve damage^[9,10] and difficulty in swallowing.^[11]

The use of systemic antibiotic following the third molar surgery in healthy individuals for the purpose of preventing postinflammatory complications is still controversial. Some authors have reported the need for such method.^[3,12-15] Lacasa *et al.* in their study reported a higher rate of infection among the patients receiving placebo (16%) than those receiving a single-dose prophylaxis (5.3%) or 5-day preemptive therapy (2.7%).^[12] Similarly in a study of 197 subjects, Jose *et al.* found out that suture dehiscence and infection was seen in the placebo group, while no socket infection was found in the prophylactic group.^[13] Other authors have reported a lack of efficacy.^[14,15] Siddiqi *et al.* in a split-mouth technique did not find a statistically significant difference in infection rate, pain, swelling, trismus, and temperature between prophylaxis and placebo groups.^[16] Ataoglu also reported no significant difference in infection rate, pain, swelling and trismus between prophylaxis and placebo groups following the third molar surgery in 150 healthy patients.^[17] Several commentaries have been reported with regard to these controversies.^[18-19] More recently, a Cochrane review on the use of antibiotics in the third molar removal concluded that antibiotics may be beneficial following removal of the third molar in diseased gum and severely decayed tooth.^[20] Carrying out placebo-controlled studies in such patients is not ethically possible because the risk of infection is high and treatment of such infections, when they occur, may be difficult.^[20]

In sub-Saharan Africa, especially Nigeria, the indications for mandibular third molar removal are chronic infections or infection-related cases^[4,21-23] that may justify the use of prophylactic antibiotic after the third molar extraction.^[24]

The aim of this study was to evaluate the efficacy of prophylactic amoxicillin/clavulanic acid and levofloxacin and preemptive therapy of amoxicillin/clavulanic acid in the reduction of postinflammatory complications, surgical site infection, and alveolar osteitis following the third molar surgery.

PATIENTS AND METHODS

A total of 135 healthy patients aged 18–35 years were recruited for the study. The study was conducted at the Department of Oral and Maxillofacial Surgery, Obafemi Awolowo University Teaching Hospitals Complex, Ile-Ife, Osun State between May 2011 and February 2012. The protocol was approved by the hospital ethics and research committee with protocol number ECR/2011/04/14, national number NHREC/27/02/2009a and international number IRB/IEC/0004553, and written, dated, informed consent were obtained from all patients prior to study entry.

The 135 patients were randomized into three equal groups of 45 patients each: Group A (preemptive therapy of

amoxicillin/clavulanic acid) with preoperative dose of 875/125 mg amoxicillin/clavulanic acid followed by 500/125 mg amoxicillin/clavulanic acid 12 hourly for 5 days, Group B (amoxicillin/clavulanic acid prophylaxis) with a single preoperative dose of amoxicillin/clavulanic acid 875/125 mg tablets, and Group C (levofloxacin prophylaxis) with a single preoperative dose of levofloxacin 1000 mg tablets. Each medication was labeled with a medication code number according to the randomization sequence that was generated online before the commencement of the study. An online randomization sequence generator was assessed and the total number of the sample (135) and the number of group (three groups) was slotted into the software, and the sequence was generated automatically.^[25] This sequence was used to allocate the patients into the groups to eliminate bias. There was no other type of antibiotics given after the surgical procedures. The surgeon, as well as the independent observer, was blinded to the type of drug given to each patient.

Preoperative assessment

After consenting to participate in the study, the independent observer recorded the maximal interincisal distance between the incisal edges of the upper and lower right incisors at the maximum mouth opening in millimeters using caliper as described by Ustün *et al.* [Figure 1].^[26] This was used to assess the degree of trismus. Axillary temperature was recorded in degree centigrade using a clinical thermometer. Where swelling is expected to be present, measurement was carried out using a horizontal and vertical guide with a tape on four reference points: Tragus, lateral canthus, outer corner of the mouth, and angle of the mandible [Figure 2]. The vertical measure corresponds to the distance between the lateral canthus of the eye and the angle of the mandible, while the horizontal measure corresponds to the distance between the ipsilateral commissure of the mouth and the tragus of the ear [Figure 2] (measurement of the craniometric point as described by Souza and Console).^[27] This distance was measured in millimeters using a measuring tape. The arithmetic means of these values determined the facial measurement.

Surgical protocol

All surgery was performed by the same surgeon using a standardized procedure. Under local anesthesia (2% lignocaine with 1:100,000 adrenaline), a buccal three-sided mucoperiosteal flap was raised by a gingival margin incision around the mandibular second and third molars with anterior and posterior relieving incisions using a #15 surgical blade. Bone removal was done by a bucco-distal guttering technique using fast handpiece (80,000–150,000 rev/min) and #10 surgical round cutting bur under continuous irrigation with sterile 0.9% saline solution.

Tooth sectioning, when indicated, was performed with a tapering fissure bur in a fast handpiece (80,000–150,000 rev/min) under irrigation with sterile 0.9% saline solution. After tooth removal

by the use of Coupland elevators, the alveolus was inspected, curetted for granulation tissue removal (for those with associated periapical granuloma and cysts), and irrigated with sterile saline solution. In addition, the flap base was carefully debrided and irrigated with a sterile normal saline solution. A 3/0 black braided silk suture material was used to close the wound without tension.

Immediately after the surgery, details of the procedure including intraoperative complications were recorded. A dental surgery assistant using a quartz battery-driven wall clock recorded the duration of surgery in minutes (from the incision time to insertion of the last suture).

All patients were asked to commence warm saline mouth bath 24 h after extraction to ensure organization of blood clot. Subjects were given a contact mobile telephone numbers of the researcher should any questions or complications arise thereafter.

Evaluation criteria

A review appointment was scheduled for postoperative days (PODs) 1, 3, 5, 7, and 14. Healing complications were assessed using parameter reported by Adeyemo *et al.*^[28] for postextraction-healing complication:

- Acutely inflamed socket was diagnosed for a painful socket that was red and swollen but without pus or systemic fever
- Acutely, infected socket was diagnosed when there was redness, swelling, pus discharge, or systemic fever
- The diagnosis for alveolar osteitis was made on the basis of persistent throbbing pain and exposure of bare alveolar bone with/without fetor Oris
- Normal wound healing occurred in an alveolus with normal granulation tissue with or without pain.

Inflammatory variables

Facial swelling

The presence of swelling was recorded by adopting the method used to measure swelling preoperatively. The arithmetic mean of both the vertical and horizontal components of the swelling determined the facial swelling.

Degree of mouth opening

Trismus was assessed by measuring a range of opening between the incisal edges of the upper and lower incisors at the maximum mouth opening in millimeters using caliper as described by Ustün *et al.*^[26]

Temperature

Subject's axillary temperature was recorded on each study visit to assess the degree of fever in degree centigrade using a mercury clinical thermometer (Umec clinical thermometer manufactured by Wuxi Hongguang Medical Equipment Company Limited China) by a calibrated assistant who is a junior resident.

Pain

Subjects were asked to mark the visual analog scale (VAS) for

pain assessment. Operationally, VAS is usually a horizontal line 100 mm in length, anchored by word descriptors at each end. The subjects were asked to mark on the line the point they feel represents their perception of their current pain state. The visual analog score was determined by measuring in millimeters from the left-hand end of the line to the point that the subjects mark by a calibrated assistant who is a junior resident.^[29]

Dysphagia

Painful swallowing to either solid foods, liquid foods, or both was recorded on each recall visit. In this case, dysphagia will be categorized into present or absent.

Safety variables

Side effects such as nausea, vomiting, and skin rash were also inquired about for each examination.

Statistical analysis

Data analysis was carried out using Stata 10 (StataCorp College Station, Texas). Descriptive statistics was carried out for sociodemographic variables such as age, gender, marital status, and occupation. The descriptive variables that are continuous parameters such as mean, median, minimum, maximum, and measures of variability were determined. For descriptive variables that are categorical, simple frequency and percentages were determined.

Statistical analysis was done using intention-to-treat analysis.^[30] In order to address the objectives, the proportion of postoperative infection in subjects taking prophylactic oral administration of levofloxacin and amoxicillin/clavulanic acid was determined and compared using Chi-square statistics. One-way analysis of variance (ANOVA) was used for continuous variables. Statistical significance was inferred at $P < 0.05$.

RESULTS

A total of 135 patients were randomized to study medications

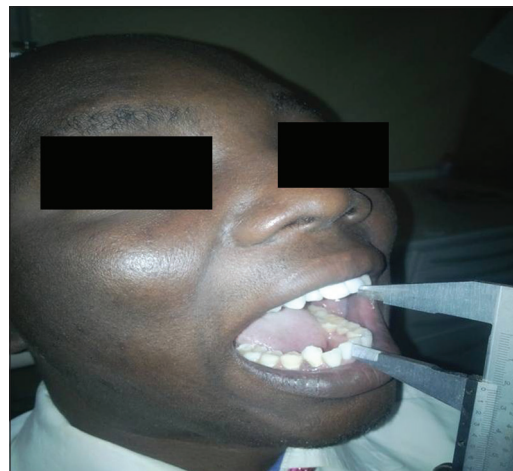

Figure 1: Measurement of interincisal distance in one of the patients

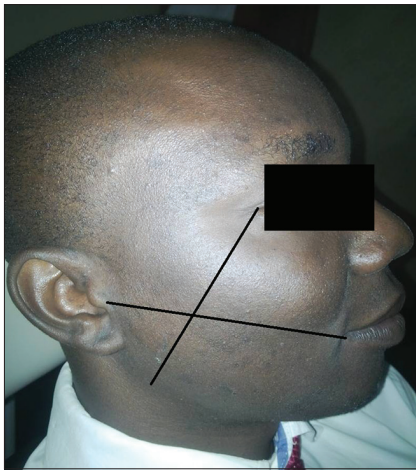


Figure 2: Measurement of facial dimension in one of the patients

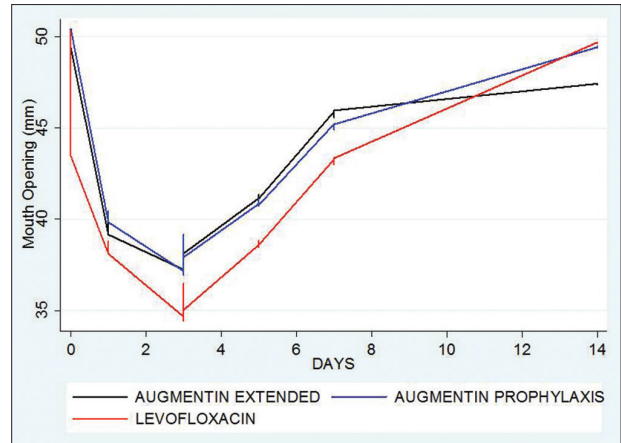


Figure 3: Plot of trend in degree of mouth opening preoperatively and on review days

Table 1: Sex distribution by mean age of patients in the groups

Sex	Patient groups								
	A			B			C		
	Frequency(%)	Age range	Mean±SD (years)	Frequency (%)	Age range	Mean±SD (years)	Frequency (%)	Age range	Mean±SD (years)
Female	26 (57.8)	18-35	23.9±4.8	21 (46.7)	19-35	23.7±5.4	25 (55.6)	18-35	25.7±5.9
Male	19 (42.2)	18-35	27.7±5.7	24 (53.3)	19-31	23.7±3.3	20 (44.4)	18-35	24.5±4.2
Total	45 (100)	18-35	25.5±5.5	45 (100)	19-35	23.7±4.3	45 (100)	18-35	25.2±5.2

SD: Standard deviation

Table 2: Distribution of preoperative variables among patient groups

	Group A (Augmentin extended)	Group B (Augmentin prophylaxis)	Group C (levofloxacin prophylaxis)	P
Mouth opening (±SD) (mm)	49.4±8.1	50.42±9.4	50.4±5.9	0.791
Facial dimension (±SD) (mm)	108.6±5.9	107.37±6.4	106.6±5.2	0.244
Temperature (±SD) (°C)	36.8±0.4	36.7±0.4	36.7±0.5	0.638
Dysphagia, frequency (%)				
Yes	4 (8.9)	1 (2.2)	4 (8.9)	0.343
No	41 (91.1)	44 (97.8)	41 (91.1)	

SD: Standard deviation

Table 3: Distribution of preoperative clinical status and duration of surgery among patient groups

Preoperative clinical status	Patient groups (%)			Total (%)	P
	A frequency	B frequency	C frequency		
Indications for extraction					
Pericoronitis	35 (77.8)	32 (71.1)	33 (73.3)	100 (74.1)	0.763
Apical periodontitis	10 (22.2)	13 (28.9)	12 (26.7)	35 (25.9)	
Impaction type					
Mesioangular	24 (53.3)	19 (42.2)	27 (60.0)	70 (51.9)	0.035
Distoangular	13 (28.9)	14 (31.2)	2 (4.4)	29 (21.4)	
Vertical	5 (11.1)	6 (13.3)	8 (17.8)	19 (14.1)	
Horizontal	3 (6.7)	6 (13.3)	8 (17.8)	17 (12.6)	
Associated pathology					
No pathology	16 (35.6)	20 (44.4)	11 (24.4)	47 (34.8)	0.411
Pocket	10 (22.2)	9 (20.0)	13 (28.9)	32 (23.7)	
Pocket + caries	15 (33.3)	10 (22.2)	12 (26.7)	37 (27.4)	
Caries + periapical cyst	3 (6.7)	3 (6.7)	3 (6.7)	9 (6.7)	
Caries + periapical cyst + pocket	1 (2.2)	3 (6.7)	6 (13.3)	10 (7.4)	
Surgery duration (±SD) (min)	24.1±5.0	19.5±12.1	22.0±13.2	-	0.139

SD: Standard deviation

Table 4: Distribution of mean visual analog scores among patient groups at different postoperative days

POD	Mean (±SD) visual analog score			P
	Group A	Group B	Group C	
POD 1	34.8±24.4	37.9±28.1	38.2±23.4	0.778
POD 3	23.3±19.6	21.1±20.5	23.8±20.8	0.799
POD 5	15.6±17.7	13.6±16.8	15.8±17.4	0.814
POD 7	7.7±11.3	6.6±12.5	8.6±10.9	0.727
POD 14	1.6±1.9	1.1±3.1	0.9±2.4	0.610

SD: Standard deviation, POD: Postoperative day

Table 5: Distribution of mean facial values among patient groups at preoperative and different postoperative days

Pre- and post-operative day	Mean (±SD) facial values (mm)			P
	Group A	Group B	Group C	
Preoperative	108.6±5.9	107.4±6.4	106.6±5.2	0.244
POD 1	111.9±6.6	113.1±5.8	113.0±8.4	0.693
POD 3	109.6±5.8	109.5±5.5	109.5±6.6	0.971
POD 5	107.3±5.5	108.1±5.5	106.7±5.5	0.268
POD 7	107.5±5.4	107.9±5.9	106.4±5.0	0.444
POD 14	107.5±5.6	107.4±6.5	105.9±5.2	0.530

SD: Standard deviation, POD: Postoperative day

Table 6: Distribution of mean temperature value in patient groups at preoperative and different postoperative days

Pre- and post-operative day	Mean (±SD) temperature values (°C)			P
	Group A	Group B	Group C	
Preoperative	36.8±0.4	36.7±0.4	36.7±0.5	0.638
POD 1	36.6±0.4	36.8±0.4	36.9±0.4	0.071
POD 3	36.6±0.5	36.6±0.5	36.7±0.5	0.419
POD 5	36.6±0.5	36.6±0.4	36.5±0.5	0.449
POD 7	36.6±0.4	36.6±0.4	36.6±0.5	0.772
POD 14	36.6±0.4	36.6±0.4	36.5±0.5	0.526

SD: Standard deviation, POD: Postoperative day

with 45 patients in each group. No patient was excluded from the study. The patient's age and the sex distributions are listed in Table 1. There were no significant difference in gender ($P = 0.54$; $\chi^2 = 1.25$) and age ($P = 0.19$; ANOVA) between the three groups. ANOVA for baseline body temperature, mouth opening, and facial dimension did not show statistically significant difference (P : 0.34, 0.64, and 0.79, 0.24, respectively) [Table 2]. The preoperative clinical status in the three treatment groups is shown in Table 3.

No case of acutely inflamed socket, acutely infected socket, or alveolar osteitis was recorded in the study groups.

There were no statistically significant differences between the treatment groups with regard to pain scores (VAS) on the first, third, fifth, seventh, and fourteenth PODs after surgery (P value in these fixed time intervals: 0.72, 0.80, 0.81, 0.73, and 0.61, respectively, ANOVA) [Table 4]. Figure 3 shows a trend in the degree of mouth opening preoperatively and on review days.

Table 5 shows a trend in the evaluation of postoperative facial dimension. As far as the body temperature was concerned, there were no statistically significant differences between the examined groups throughout the review days (P value in these time intervals: 0.07, 0.42, 0.45, 0.77, and 0.53, respectively) [Table 6].

DISCUSSION

The present study compared the clinical advantages of an extended regimen of amoxicillin/clavulanic acid and a single-dose preoperative bolus of amoxicillin/clavulanic acid to a single-dose preoperative bolus of levofloxacin (fluoroquinolone) in healthy subjects undergoing mandibular third molar extraction. The indication for extractions included chronic/recurrent pericoronitis, grossly carious third molars with associated infective pathologies such as pockets, periapical granuloma, and cysts. In our setting, placebo-controlled studies are not permitted due to ethical concerns. However, in a recently published Cochrane review on the use of antibiotics following mandibular third molar extraction, it was concluded that carrying out a placebo-controlled study in diseased gums (pericoronitis, carious lesions, and periapical granulomas/cysts) is unethical and therefore the use of antibiotics in these group of patients is justified.^[20] In sub-Saharan Africa, it is important to note that most of the indications for third molar extractions are chronic infections or infection-related cases that may justify the use of prophylactic antibiotic after the third molar extraction.^[4,23-26]

A very crucial point in the debate about prophylactic antibiotics in the third molar surgery for these cases is the timing of antibiotic administration. In the past, three different approaches were compared with either placebo or control groups in several clinical trials.^[31-33] The first approach included the administration of antibiotic before surgery, which is maintained postoperatively for several days.^[8,31] The second approach, otherwise known as preemptive treatment, involved the administration of antibiotics before or immediately after surgery and maintained for several days.^[32,34] The third option (perioperative) included the administration of antibiotics preoperatively as a single bolus antibiotic therapy. This may serve as the only antibiotic given, or an additional second course may be administered few hours after surgery.^[24,31,33-35]

In this study, the three options of antibiotic administration were compared, and there was no record of wound infection among the three groups of subjects studied. In other words, there was no difference in infection rate between the patients who received prophylactic single-dose and extended amoxicillin/clavulanic acid after the third molar surgery and between the patients who received single-dose levofloxacin and amoxicillin/clavulanic acid. This observation was corroborated by other related studies.^[13,31,36,37] In a study to compare the efficacy of pre- and post-operative amoxicillin in the prevention of postoperative complications in patients undergoing third molar surgery, Jose et al.^[13] recorded no infection among the patients who received

prophylactic amoxicillin and extended amoxicillin. However, they recorded postoperative wound infection in five patients who received placebo. Similarly, Olusanya *et al.*^[38] compared prophylaxis versus preemptive amoxicillin and metronidazole in the prevention of postoperative complications after the third molar surgery in 84 subjects and concluded that single bolus antibiotics prophylaxis should be adequate for most cases of third molar surgery based on the fact that the degree of postoperative wound infection, pain, swelling, and trismus was similar in both groups that were studied.

Some other studies^[24,37] have compared other forms of antibiotics apart from penicillins in the prevention of postoperative complications following the third molar surgery and have recorded similar infection rates as with the use of penicillins. Although, there was no difference in infection rate between group of subjects who received single bolus levofloxacin and amoxicillin/clavulanic acid in the present study, however, Limeres *et al.*^[39] in their study of 100 subjects concluded that moxifloxacin (fluoroquinolones) shortens the period of postoperative recovery in terms of oral function and return to work better than amoxicillin-clavulanic acid combination.

There was no record of alveolar osteitis (dry socket) among subjects in the three groups. These findings are consistent with the results of previous, related studies.^[13,37] In a study by Halpern and Dodson,^[37] “does prophylactic administration of systemic antibiotics prevent postoperative inflammatory complications after third molar surgery” they observed that no subject met the case definition for alveoli osteitis out of the 118 subjects that had their third molars extracted compared with placebo. Alveolar osteitis is considered a healing disturbance related to some risk factors, and in some studies, it has been included as a complication of infection.^[12] Surgical trauma appears to be one of the most important risk factors for the development of alveolar osteitis and subjects aged 18 years or older are more prone.^[34] However, this complication was not observed in this study. The relatively short operative times in this study could help to explain, at least in part, the absence of such complications, because the dry socket is commonly associated with prolonged trauma to the hard tissues. The mean duration of the procedure in this study was 24.1 ± 15.8 in Group A, 19.5 ± 12.1 in Group B, while in Group C mean duration of the procedure was 22.0 ± 13.2 min [Table 3].

It is also important to highlight the low pain levels in this study. Although differences in the mean level of pain were observed among the three groups during the first 7 days, the mean scores did not reach a score 40 on a 100 mm scale in any of the groups [Figure 1]. According to the criteria used by Monaco *et al.*,^[27] this pain intensity should be considered very mild in the context of postoperative complications. The same applies to temperature as no statistically significant differences were found and the mean value never exceeded 37°C in any of the three groups. The administration of ibuprofen that has both anti-inflammatory and antipyretic effects could explain, at least in

part, the temperatures not greater than 37°C compared with that in other studies, in which fever occurred in some of the subjects.^[27]

CONCLUSION

No subject presented with extraction socket infection when levofloxacin and amoxicillin/clavulanic acid as a single bolus preoperative prophylaxis and amoxicillin/clavulanic acid as a single preoperative bolus and extended regimens were used after the third molar surgery with associated pathologies. Moreover, no subject presented with alveoli osteitis when levofloxacin and amoxicillin/clavulanic acid as single preoperative bolus was used following the third molar removal with associated pathologies. Therefore, amoxicillin/clavulanic acid as a single preoperative bolus should be adequate for the prevention of postoperative wound infection and alveoli osteitis following the third molar extraction as there is no need for extension of the antibiotic also, levofloxacin can be utilized as prophylaxis in patients undergoing mandibular third molar extraction, especially if such patients are allergic to amoxicillin.

Declaration of patient consent

The authors certify that they have obtained all appropriate patient consent forms. In the form the patient(s) has/have given his/her/their consent for his/her/their images and other clinical information to be reported in the journal. The patients understand that their names and initials will not be published and due efforts will be made to conceal their identity, but anonymity cannot be guaranteed.

Acknowledgment

The authors are grateful to the management of Obafemi Awolowo University Teaching Hospital Complex for part sponsoring the research.

Financial support and sponsorship

Nil.

Conflicts of interest

There are no conflicts of interest.

REFERENCES

1. Flick WG. The third molar controversy: Framing the controversy as a public health policy issue. *J Oral Maxillofac Surg* 1999;57:438-44.
2. Hochwald DA, Davis WH, Martinoff J. Modified distolingual splitting technique for removal of impacted mandibular third molars: Incidence of postoperative sequelae. *Oral Surg Oral Med Oral Pathol* 1983;56:9-11.
3. Mitchell DA. A controlled clinical trial of prophylactic tinidazole for chemoprophylaxis in third molar surgery. *Br Dent J* 1986;160:284-6.
4. Oginni FO, Ugboko VI, Assam E, Ogunbodede EO. Postoperative complaints following impacted mandibular third molar surgery in Ile-Ife, Nigeria. *SADJ* 2002;57:264-8.
5. Battista G, Maiorana C, Alberto G, Borgonovo A, Creminelli L. Assessing postoperative discomfort after third molar surgery:

- A prospective study. *J Oral Maxillofac Surg* 2007;65:901-17.
6. Blondeau F, Daniel NG. Extraction of impacted mandibular third molars: Postoperative complications and their risk factors. *J Can Dent Assoc* 2007;73:325.
 7. Larsen PE. Alveolar osteitis after surgical removal of impacted mandibular third molars. Identification of the patient at risk. *Oral Surg Oral Med Oral Pathol* 1992;73:393-7.
 8. Piecuch JF, Arzadon J, Lieblich SE. Prophylactic antibiotics for third molar surgery: A supportive opinion. *J Oral Maxillofac Surg* 1995;53:53-60.
 9. Chiapasco M, De Cicco L, Marrone G. Side effects and complications associated with third molar surgery. *Oral Surg Oral Med Oral Pathol* 1993;76:412-20.
 10. Wofford DT, Miller RI. Prospective study of dysesthesia following odontectomy of impacted mandibular third molars. *J Oral Maxillofac Surg* 1987;45:15-9.
 11. Savin J, Ogden GR. Third molar surgery – A preliminary report on aspects affecting quality of life in the early postoperative period. *Br J Oral Maxillofac Surg* 1997;35:246-53.
 12. Lacasa JM, Jimenez JA, Ferras V. Prophylactic versus pre-emptive treatment for infective and inflammatory complications of surgical third molar removal: A randomized, double-blind, placebo-controlled, clinical trial with sustained release amoxicillin/clavulanic acid (1000/62.5 mg). *J Oral Maxillofac Surg* 2007;65:321-7.
 13. Jose LL, Jose IP, Joseba S, Gonzalo H. Efficacy of amoxicillin treatment in preventing postoperative complications in patients undergoing third molar surgery: A prospective, randomized, double-blind controlled study. *J Oral Maxillofac Surg* 2011;69:5-14.
 14. Poeschl PW, Eckel D, Poeschl E. Postoperative prophylactic antibiotic treatment in third molar surgery – A necessity? *J Oral Maxillofac Surg* 2004;62:3-8.
 15. Peterson LJ. Antibiotic prophylaxis against wound infections in oral and maxillofacial surgery. *J Oral Maxillofac Surg* 1990;48:617-20.
 16. Siddiqi A, Morkel JA, Zafar S. Antibiotic prophylaxis in third molar surgery: A randomized double-blind placebo-controlled clinical trial using split-mouth technique. *Int J Oral Maxillofac Surg* 2010;39:107-14.
 17. Ataog'lu H, Öz GY, Çandirli C. Routine antibiotic prophylaxis is not necessary during operations to remove third molars. *Br J Oral Maxillofac Surg* 2008;46:133-8.
 18. Lindeboom IA. The controversy continues!!! *Int J Oral Maxillofac Surg* 2008;37:199-201.
 19. Kaczmarzyk T. Abuse of antibiotic prophylaxis in third molar surgeries. *J Oral Maxillofac Surg* 2009;67:2551-2.
 20. Lodi G, Figini L, Sardella A, Carrassi A, Del Fabbro M, Furness S. Antibiotics to prevent complications following tooth extractions. *Cochrane Database Syst Rev* 2012;11:CD003811.
 21. Adeyemo WL. Do pathologies associated with impacted lower third molars justify prophylactic removal? A critical review the literature. *Oral Surg Oral Med Oral Pathol Oral Radiol Endod* 2006;102(4):448-52.
 22. Adeyemo WL, James O, Ogunlewe MO, Ladeinde AL, Taiwo OA, Olojede AC. Indications for extraction of third molars: A review of 1763 cases. *Niger Postgrad Med J* 2008;15(1):42-46.
 23. Akadiri AO, Okojie VN, Fasola AO, Olusanya AA, Aladelusi TO. Indications for the removal of impacted mandibular third molars at Ibadan - any compliance with established guidelines. *Afr J Med Sci* 2007;36(4):359-63.
 24. Kaczmarzyk T, Wichlinski J, Stypulkowska J, Zaleska M, Panas M, Woron J. Single-dose and multi-dose clindamycin therapy fails to demonstrate efficacy in preventing infectious and inflammatory complications in third molar surgery. *Int J Oral Maxillofac Surg* 2007;36:417-22.
 25. Available from: <http://www.graphpad.com/quickcalcs/randomize2.cfm>. [Last accessed on 2011 May 08].
 26. Ustün Y, Erdogan O, Esen E, Karsli ED. Comparison of the effects of 2 doses of methylprednisolone on pain, swelling, and trismus after third molar surgery. *Oral Surg Oral Med Oral Pathol Oral Radiol Endod* 2003;96:535-9.
 27. Souza J, Consone D. Metodoparamedida do edema facial. *Emposoperatorio de cirurgiasbucais. RGO* 1992;40:137-41.
 28. Adeyemo WL, Ladeinde AL, Ogunlewe MO. Clinical evaluation of post-extraction site wound healing. *J Contemp Dent Pract* 2006;7:40-9.
 29. Gould D. Visual analogue scale. *J Clin Nurs* 2001;10:697-706.
 30. Fisher LD, Dixon DO. Intention-to-treat in clinical trials. In: Peace KE, editor. *Statistical Issues in Drug Research and Development*. New York: Marcel Dekker; 1990.
 31. Monaco G, Tavernese L, Agostini R, Marchetti C. Evaluation of antibiotic prophylaxis in reducing postoperative infection after mandibular third molar extraction in young patients. *J Oral Maxillofac Surg* 2009;67:1467-72.
 32. Arteagoitia I, Diez A, Barbier L, Santamaria G, Santamaria J. Efficacy of amoxicillin/clavulanic acid in preventing infectious and inflammatory complications following impacted mandibular third molar extraction. *Oral Surg Oral Med Oral Pathol Oral Radiol Endod* 2005;100:e11-8.
 33. Happonen RP, Bäckström AC, Ylipaavalniemi P. Prophylactic use of phenoxymethylpenicillin and tinidazole in mandibular third molar surgery, a comparative placebo controlled clinical trial. *Br J Oral Maxillofac Surg* 1990;28:12-6.
 34. Monaco G, Staffolani C, Gatto MR, Checchi L. Antibiotic therapy in impacted third molar surgery. *Eur J Oral Sci* 1999;107:437-41.
 35. Bulut E, Bulut S, Etikan I, Koseoglu O. The value of routine antibiotic prophylaxis in mandibular third molar surgery: Acute phase protein levels as indicators of infection. *J Oral Sci* 2001;43:117-22.
 36. Srinivas MS, Basel S, Thomas BD. Do Antibiotics Reduce the Frequency of Surgical Site Infections After Impacted Mandibular Third Molar Surgery. *Oral Maxillofac Surg Clin N Am* 2001;23:541-6.
 37. Halpern LR, Dodson TB. Does prophylactic administration of systemic antibiotics prevent postoperative inflammatory complications after third molar surgery? *J Oral Maxillofac Surg* 2007;65:177-85.
 38. Olusanya AA, Arotiba JT, Fasola OA, Akadiri AO. Prophylaxis versus pre-emptive antibiotics in third molar surgery: A randomized control study. *Niger Postgrad Med J* 2011;18:105-10.
 39. Limeres J, Sanromán JF, Tomás I, Diz P. Patients' perception of recovery after third molar surgery following postoperative treatment with moxifloxacin versus amoxicillin and clavulanic acid: A randomized, double-blind, controlled study. *J Oral Maxillofac Surg* 2009;67:286-91.