

Clinical Outcome of Parotidectomy with Reconstruction: Experience of a Regional Head and Neck Cancer Unit

Eyituyo Okoturo, Anslem Osasuyi¹

Division of Head and Neck Surgical Oncology, Department Oral and Maxillofacial Surgery, Lagos State University College of Medicine/Teaching Hospital, ¹Department Oral and Maxillofacial Surgery, Lagos State University College of Teaching Hospital, Lagos, Nigeria

ABSTRACT

Background: Salivary gland pathologies represent a histologically diverse group of benign and malignant neoplasms. Currently, World Health Organization recognizes 13 benign and 24 malignant variants of all salivary gland neoplasms. Surgery continues to remain the main-stay for treatment of parotid gland neoplasms. The aim of this study was to document our experiences of the patients treated for parotid tumors and find out if any compelling variable predicted the relative clinical outcomes.

Materials and Methods: This was a retrospective study, from records of parotidectomies performed at the operating theatre by the head and neck cancer division of the study institution between 2010 and 2013. Eligibility for study inclusion included cases with benign or malignant parotid neoplasms requiring surgical management with or without adjunct radiotherapy. The predictors of postoperative complications, overall survival (OS), and disease-free survival (DFS) were analyzed. **Results:** A total of 20 patients underwent parotidectomy. The mean age was 42 years. Tumors were located on the left parotid in 13 cases (65%) and the right parotid in 7 cases (35%). The surgical procedures comprised 16 superficial parotidectomies, 1 total parotidectomy, and 3 radical parotidectomy (inclusive of facial nerve sacrifice) and 2 neck dissections levels II–V. The reconstructive procedures were 2 facial nerve branch cable grafts, 1 end-to-end facial-facial nerve branch anastomoses, and 2 facial re-animation surgeries (temporalis muscle suspensions). A total of five cases (33.3%) had postoperative complications. 2 variables (length of surgery and neck dissection) were found to have an impact on postoperative complications that were statistically significant. Additionally, length of surgery was a significant predictor on the 2 years OS and DFS. **Conclusion:** The result of this study showed good clinical outcome, especially in the benign cases. The comprehensive clinical outcome of the malignant cases could not be objectively assessed, as the OS and DFS were 50% at 2-years follow-up. It is our submission that a larger sample size is utilized in subsequent studies and quality of life evaluation is included in the methodology.

KEYWORDS: Facial re-animation, neural anastomosis, parotidectomy

Address for correspondence:

Dr. Eyituyo Okoturo,
Division of Head and Neck Surgical Oncology, Department Oral and Maxillofacial Surgery, Lagos State University College of Medicine/Teaching Hospital, Lagos, Nigeria.
E-mail: eyituyo.okoturo@lasucom.edu.ng

Access this article online

Quick Response Code:



Website: www.nigerianjsurg.com

DOI:
10.4103/1117-6806.176396

BACKGROUND

Salivary gland pathologies represent a histologically diverse group of benign and malignant neoplasms. These neoplasms are rare, mainly benign and account for between 2% and 6% of all head and neck pathologies.^[1-3] Of the three major salivary glands, the parotid gland accounts for between 70 and 80% of all salivary gland neoplasms with its malignant component constituting 1–2% of all head and neck malignancies.^[4,5]

Currently, World Health Organization recognizes 13 benign and 24 malignant variants of salivary gland neoplasms.^[6] Pleomorphic adenoma constitutes the commonest benign salivary gland

This is an open access article distributed under the terms of the Creative Commons Attribution-NonCommercial-ShareAlike 3.0 License, which allows others to remix, tweak, and build upon the work non-commercially, as long as the author is credited and the new creations are licensed under the identical terms.

For reprints contact: reprints@medknow.com

How to cite this article: Okoturo E, Osasuyi A. Clinical outcome of parotidectomy with reconstruction: Experience of a regional head and neck cancer unit. *Niger J Surg* 2016;22:26-31.

neoplasm with a prevalence of between 45 and 80%. This is followed by Warthin's tumor with 10% prevalence. For the malignant variant, mucoepidermoid carcinoma constitutes the most common malignant salivary gland tumor with 30% prevalence, followed by adenocystic carcinoma 25%.^[4,5,7]

Surgery continues to remain the mainstay of treatment for parotid gland neoplasms. In continuum, radical surgery involving dissection of the facial nerve may be indicated for malignant salivary gland neoplasms. This aspect of the management involving sacrificing of the facial nerve is reported to be esthetically displeasing and emotionally traumatising, therefore, some form of facial-neural reconstruction becomes imperative.^[8,9]

The clinical outcomes following parotidectomies have been published in the literature with very little emanating from a limited opportunity environment. Thus, the aim of this study was to document our experiences of patients that had parotidectomy with or without reconstructive surgery and finding out if any compelling variable predicted the relative clinical outcomes in terms of postoperative complications and overall and disease-free survival (DFS).

MATERIALS AND METHODS

Patients

This was a retrospective study collated from records of parotidectomies with or without reconstructive surgery, performed at the operating theater of the head and neck cancer division of the study institution between 2010 and 2013. Eligibility for study included cases with benign or malignant parotid neoplasms requiring surgical management with or without adjunct treatment.

Data collated included; biodata, side of gland affected, histopathology, TNM staging, histological adverse effects for malignancies (+ve tumor margins and lymphovascular invasion), types of surgery, type of reconstruction, the length of surgery, the length of hospital admission, deaths, and follow ups. Tumor margin was adjudged positive when tumor front was ≤ 4 mm from the margin of excision.

Surgery

The surgical procedures comprised partial or superficial parotidectomy defined as a surgical procedure aimed at eradicating the tumor by removal of part or whole of the superficial lobe of the parotid gland containing the tumor. Total parotidectomy was defined as removal of the entire parotid gland without its adjoining structures. Radical parotidectomy was defined as a surgical procedure aimed at eradicating the malignant tumor involving the parotid gland and its adjacent structures including any facial nerve branch or trunk.^[9] Irrespective of the type of parotidectomy, facial nerve trunk and bifurcation were mandatorily exposed during dissection as shown in Figure 1.

This is to avoid inadvertent damage to nerve and act as a guide to type of parotidectomy.

Neck dissection was indicated for parotid gland malignancies with either high-grade variant or presence of cervical metastasis.

Reconstructive surgeries were in two parts; micro-neural anastomosis and facial re-animation surgery. Following facial nerve sacrifice, micro-neural anastomosis was done using tensionless, end-to-end, facial-to-facial nerve branch anastomosis or micro-neural nerve cable grafting with greater auricular nerve as shown in Figures 2 and 3. These were done using 9.0 Ethilon™ nylon sutures (Ethicon, USA) and an operating microscope at $\times 4$ magnification (ZEISS OPMI Vario/S88). Postoperative facial nerve anastomosis function was assessed using House–Brackmann (H-B) facial grading system after a minimum of 9 months follow-up period.^[9,10] Temporalis muscle suspension was the facial re-animation surgery performed as shown in Figures 4 and 5. Indications for postoperative radiotherapy were high-grade cancer variant and cervical lymph node metastasis.

All patients underwent preoperative evaluation with a view to ascertaining fitness for surgery. All malignant cases were reviewed at the study institution's head and neck multidisciplinary tumor board. This study did not require approval according to the study institution's research and ethics committee guidelines.

Main outcome measures

The impact of the following variables (type of surgery, histopathology, neck dissection, lymph node metastasis, length of surgery, and length of hospital admission) on postoperative complication were analyzed using univariate and multivariate analyses. The impact of significant variables on overall survival (OS) and DFS were equally analyzed using Kaplan–Miere's analysis.

Statistical analysis

Data were analyzed using Statistical package for social science (SPSS) for Mac OS version 21 (IBM Corporation Chicago IL). Percentages, mean and standard deviation were analyzed as appropriate for age, gender, side of affected gland, histopathology and adverse effects, surgery type (\pm neck dissection), the length of surgery, the length of hospital admission, reconstruction, radiotherapy, postoperative complications, deaths, and follow ups. Univariate, Multivariate, and Kaplan–Miere's analyses were used as appropriate. Statistical significant was set at $P < 0.05$.

RESULTS

A total of 20 patients underwent consecutive parotidectomies at the study institution over the study period (2010-2013). The mean age was 42.55 ± 12.50 years with an age range of between 16 and 70 years. Tumors were located on the left parotid in 13 cases (65.0%) and on the right parotid in

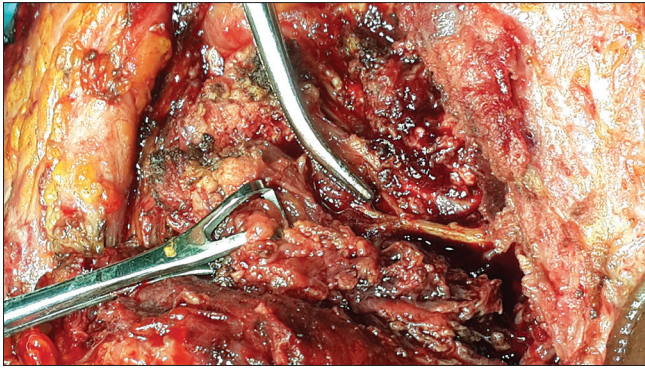


Figure 1: Exposed facial nerve trunk and bifurcation (pointed with instrument)

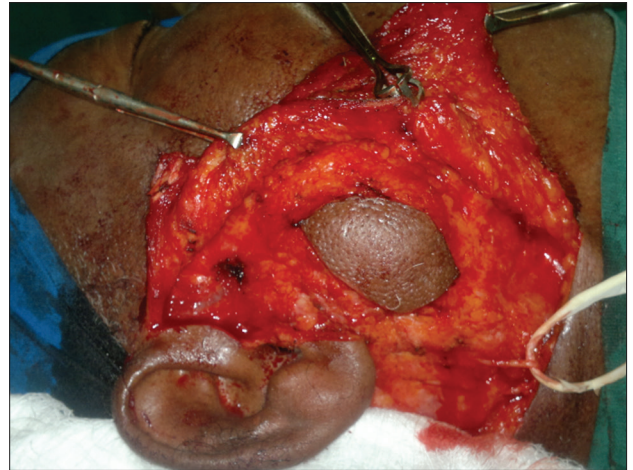


Figure 2: Exposure for radical parotidectomy with looped greater auricular nerve

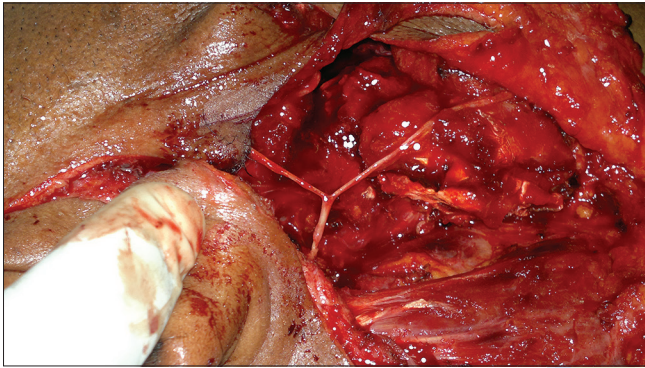


Figure 3: Greater auricular nerve cable grafted; from facial nerve trunk to zygomatic and marginal mandibular branch

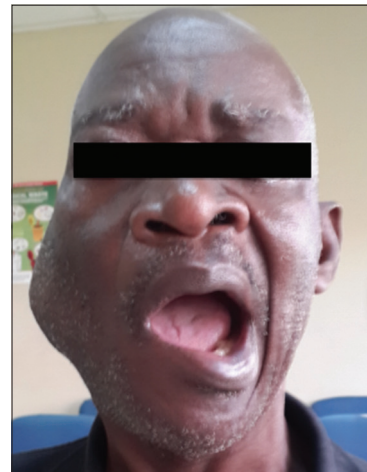

Figure 4: Facial re-animation surgery (before temporalis tendon transfer)

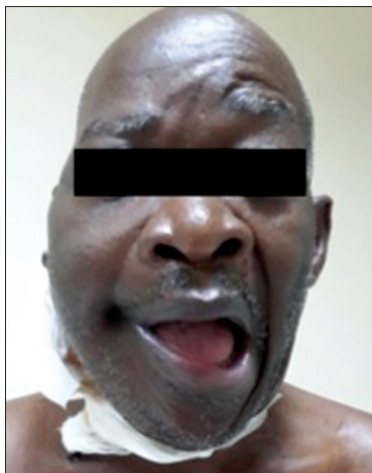


Figure 5: Facial re-animation surgery (after temporalis tendon transfer)

7 cases (35.0%). Further clinico-demographic characteristics are as shown in Table 1. The predominant benign histologic types were pleomorphic adenoma 12/20(60%), Warthins tumor 3/20(15.0%), and monomorphic adenoma 1/20(5.0%).

The prevalent malignant neoplasms were mucoepidermoid carcinoma (3/20) comprising 2 low (Tumor stage T₂) and 1 intermediate grade (Tumor stage T₄) respectively and an adenocystic carcinoma (1/20) of the tubular variant also

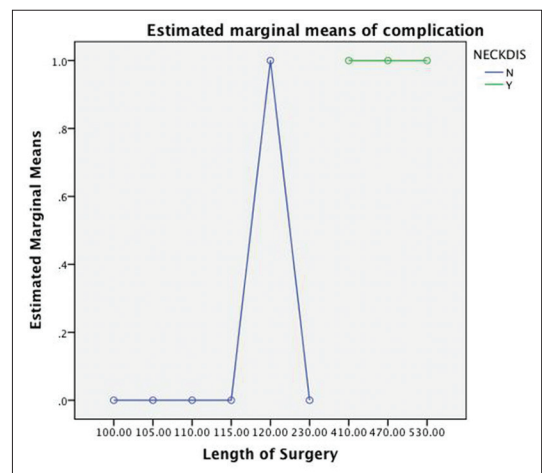


Figure 6: Multivariate analysis for complication predictors: Neck dissection (green = performed; blue = not performed) and length of surgery (neck dissection; $P = 1.000$, Length of Surgery; $P = 0.000$)

tumor stage T₄. Tumor margins and lymphovascular invasion were negative for all malignancies. The surgical procedures

Table 1: Characteristics of patient population

Data	n
Number of patients	20
Gender ratio	
Female/male	14/6
Mean age (range)	42 years (16-70 years)
Histology (%)	
Benign	16 (80)
Malignant (T ₄ , T ₄ , T ₃ , T ₃)	4 (20)
Histological adverse effects (malignant)	
Positive tumor margin (≤4 mm)	0/4
Lymphovascular invasion	0/4
Surgical technique (%)	
Partial/superficial parotidectomy (5/11)	16 (73.3)
Total parotidectomy	1 (6.7)
Radical parotidectomy	3 (20)
Neck dissection (%)	
Yes	3 (15.0)
No	17 (85.0)
Reconstructive surgery (%)	
Yes	3 (15.0)
No	17 (85.0)
Postoperative RT (%)	
Yes	2 (10.0)
No	18 (90.0)
Postoperative complications (%)	
Yes (1 facial nerve palsy, 2 facial nerve paresis, 2 fistulations)	5 (25.0)
No	15 (75.0)

RT: Radiotherapy, T3, T4 = Cancer Tumour Size

Table 2: Bivariate and multivariate analyses

Variable	Complications (bivariate)	Complications (multivariate)
Type of surgery		
Histology	0.642	1.000
Neck dissection	0.018	
Lymph node metastasis		
Length of surgery	0.000	0.000
Hospital admission	-	

Table 3: Kaplan Miere's analysis

Variable	OS	DFS
Length of surgery	0.006	0.008

OS: Overall survival, DFS: Disease-free survival

comprised 16 superficial parotidectomies, 1 total parotidectomy and 3 radical parotidectomies (with facial nerve sacrifice) inclusive of 2 selective neck dissections involving levels II–V. The reconstructive procedures were 2 temporalis muscle suspensions, 2 facial nerve cable grafts using greater auricular nerve and 1 tensionless, end-to-end facial-facial nerve branch anastomosis (buccal branch). 2 malignant cases received postoperative radiotherapy indicated for cervical lymph node metastasis.

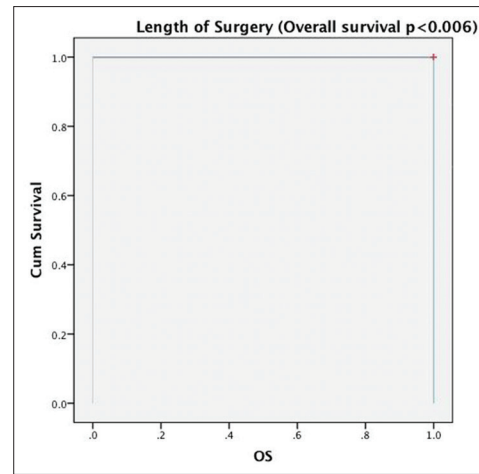


Figure 7: Kaplan–Miere's illustration for overall survival with length of surgery (overall survival; $P = 0.006$)

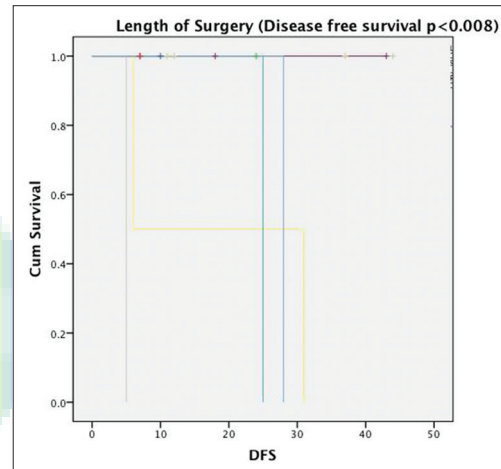


Figure 8: Kaplan–Miere's illustration for disease free survival with length of surgery (disease free survival; $P = 0.008$)

Postoperative course and morbidity

A total of five cases (25%) had postoperative complications. One of which had unexplained postoperative facial nerve palsy following total parotidectomy. Two other cases of superficial parotidectomies had postoperative facial nerve weakness that recovered over time. Two additional cases of partial parotidectomies had adenocutaneous fistulations that were treated primarily using pressure dressing.

Two patients presented with preoperative facial nerve palsy secondary to parotid gland malignancy. One of these cases died from medical complications, 5 months after surgery. The second case died from recurrent disease 10 months after surgery. Both cases had facial nerve reconstruction and the latter case recorded Grade VI on the H-B facial nerve grading system. A third malignant case that had a facial-facial nerve anastomosis (buccal branch) recorded a Grade IV H-B grading system of the buccal branch and patient is alive and well. The

fourth malignant case had only total parotidectomy and is also alive and well.

The average surgery time was 186.75 ± 143.11 min with a range of 100–530 min. The mean hospital admission was 5.75 ± 2.31 days with a range of 4–12 days.

Long-term follow-up

The average follow-up was 17.70 ± 13.34 months (range 5–44 months). The benign cases had 100% of 2 years OS and 100% of 2 years DFS while the malignant cases had 50% of 2 years OS and 50% of 2 years DFS.

Predictors of postoperative complications

According to this study, two variables were found to have a statistical significant impact on postoperative complications. These were neck dissection and length of surgery as shown in Table 2 and graphically illustrated in Figure 6. Other variables were found to be statistically insignificant. Using multivariate analysis, the length of surgery only, had a statistically significant impact on postoperative complication.

Predictors of overall survival and disease free survival

Using Kaplan Miere's, length of Surgery was found to have a significant impact on 2 years OS and DFS as shown in Table 3 and illustrated graphically in Figures 7 and 8.

DISCUSSION

The aim of this study was to evaluate the clinical outcome of parotid neoplasms following parotidectomies. The two major variants of parotid neoplasms, i.e., benign and malignant types are managed almost always by surgery. The surgical procedures can either be partial, superficial, or total parotidectomy. In contrast, the malignant types may require radical parotidectomy with facial nerve dissection to ensure free margins of resection, and neck dissection.

According to the literature, pleomorphic adenoma and mucoepidermoid carcinoma has the highest prevalence of benign and malignant parotid neoplasms, respectively.^[4,7] This study, despite its limited sample size tended to support these reports

Micro-neural nerve anastomosis or grafting with added temporalis muscle suspension can also be reconstruction imperatives.^[10-13] The average time for attainment of maximum voluntary facial motor activity recovery following neural anastomosis is between 9 and 18 months with reports of some lasting up to 4 and 6 years.^[12] Based on this time uncertainty and long duration for motor recovery, some form of interim intervention became imperative thus laying the foundation for facial re-animation surgery.

Several reports in the literature on the clinical postoperative outcomes of parotidectomies have reported a complication

rate of between 24 and 32% comprising facial nerve palsy, hematoma, infection and Frey syndrome.^[9,13] This study reported a complication rate of 25% comprising of facial nerve palsy and adenocutaneous fistulation. The later complication is not often reported in the literature. In this study, two cases presented with adenocutaneous fistulation. Both cases were part of a total of 5 partial parotidectomies carried out. The reason adduced were post-surgical communication of residual glandular tissues of the parotid gland along the incision line. No reason could be adduced for the absence of this observation in the literature. This study also recorded 10% postoperative facial nerve palsy. This percentage was lower than percentages of other published reports.^[9,13] The limited sample size in this study may have accounted for this.

The literature reported statistically significant predictors of postoperative complications to include malignant histopathology and radical resection.^[13] This study reported neck dissection and length of surgery as the statistically significant predictors of postoperative complication. Both variables could be adjudged to be a function of the radical resection required for treating malignant histopathology.

The 2-year OS and DFS for malignant neoplasms were also analysed. The literature reports cervical node metastasis as having a statistically significant impact on OS.^[13] This study suggested a length of surgery as having a significant impact on OS and DFS. The limited sample size did not allow for a compelling conclusion on this finding.

Reconstruction with microsurgical nerve grafting while proven to be successful literaturally was unable to be objectively assessed due to the absence of electroneurography.^[11,12] Only one case was assessed clinically as the second case did not survive long enough to the stipulated 9-month assessment period. Temporalis tendon suspension has also been advocated.^[12] Two were performed in this series. As the quality of life assessment was not part of the scope of this study, one was unable to assess objectively the significance of this procedure. Suffice to say, it appeared esthetically better when compared preoperatively.

Neck dissection is indicated in high-grade tumors and positive nodal metastasis that were clinically or radiologically diagnosed. In addition, radiotherapy is reported to becoming an important aspect of parotid tumor treatment, especially as an adjunct tool.^[10,14] The significance of this could not be ascertained, as the two cases with postoperative radiotherapy did not survive to the mandatory 2-years OS or DFS. The flip side of which may point to the poor prognosis of high-grade tumors and nodal metastasis. In view of the prognostic implication of nodal metastasis already suggested in the literature.^[13]

In conclusion, the result of this study showed good clinical outcome, especially in the benign cases with length of surgery being a prognostic indicator. The comprehensive clinical outcome of the malignant cases could not be conclusively assessed due

to the small sample size despite the OS and DFS being 50% at 2-years follow-up. Suffice to say the length of surgery; high-grade variants and nodal metastasis appeared to be poor prognostic indicators.

It is however, this study's submission that a larger sample size with a 3–5 years OS and DFS analysis would constitute an exhaustive research. In addition, the inclusion of a quality of life assessment in the methodology would allow for a compelling clinical outcome evaluation.

Declaration of patient consent

The authors certify that they have obtained all appropriate patient consent forms. In the form the patient(s) has/have given his/her/their consent for his/her/their images and other clinical information to be reported in the journal. The patients understand that their names and initials will not be published and due efforts will be made to conceal their identity, but anonymity cannot be guaranteed.

Financial support and sponsorship

Nil.

Conflicts of interest

There are no conflicts of interest.

REFERENCES

1. Day TA, Deveikis J, Gillespie MB, Joe JK, Ogretmen B, Osguthorpe JD, *et al.* Salivary gland neoplasms. *Curr Treat Options Oncol* 2004;5:11-26.
2. Speight PM, Barrett AW. Salivary gland tumours. *Oral Dis* 2002;8:229-40.
3. Spiro RH. Salivary neoplasms: Overview of a 35-year experience with 2,807 patients. *Head Neck Surg* 1986;8:177-84.
4. de Oliveira FA, Duarte EC, Taveira CT, Máximo AA, de Aquino EC, Alencar Rde C, *et al.* Salivary gland tumor: A review of 599 cases in a Brazilian population. *Head Neck Pathol* 2009;3:271-5.
5. Tian Z, Li L, Wang L, Hu Y, Li J. Salivary gland neoplasms in oral and maxillofacial regions: A 23-year retrospective study of 6982 cases in an eastern Chinese population. *Int J Oral Maxillofac Surg* 2010;39:235-42.
6. Barnes L, Eveson JW, Reichart P, Sidransky D. *World Health Organization Classification of Tumours: Pathology and Genetics of Head and Neck Tumours*. Lyon: IARC Press; 2005. p. 209-82.
7. Guzzo M, Locati LD, Prott FJ, Gatta G, McGurk M, Licitra L. Major and minor salivary gland tumors. *Crit Rev Oncol Hematol* 2010;74:134-48.
8. Hodgkinson DJ, Woods JE. The influence of facial-nerve sacrifice in surgery of malignant parotid tumors. *J Surg Oncol* 1976;8:425-32.
9. Chung EJ, Lee SH, Baek SH, Kwon KH, Chang YJ, Rho YS. Oncological and functional results after the surgical treatment of parotid cancer. *Int J Oral Maxillofac Surg* 2015;44:16-22.
10. Bell RB, Dierks EJ, Homer L, Potter BE. Management and outcome of patients with malignant salivary gland tumors. *J Oral Maxillofac Surg* 2005;63:917-28.
11. Spector JG. Neural repair in facial paralysis: Clinical and experimental studies. *Eur Arch Otorhinolaryngol* 1997;254 Suppl 1:S68-75.
12. Spector JG, Lee P, Peterein J, Roufa D. Facial nerve regeneration through autologous nerve grafts: A clinical and experimental study. *Laryngoscope* 1991;101:537-54.
13. Fakhry N, Aldosari B, Michel J, Giorgi R, Collet C, Santini L, *et al.* Clinical and oncological outcomes after surgical excision of parotid gland tumours in patients aged over 80 years. *Int J Oral Maxillofac Surg* 2013;42:1385-90.
14. Upton DC, McNamar JP, Connor NP, Harari PM, Hartig GK. Parotidectomy: Ten-year review of 237 cases at a single institution. *Otolaryngol Head Neck Surg* 2007;136:788-92.