

One-stage Anastomotic Urethroplasty for Traumatic Urethral Strictures. January 2004–January 2013

Charles Azuwike Odoemene, Philip Okere¹

Department of Surgery, Urology Unit, Federal Teaching Hospital, Abakaliki, Ebonyi State, ¹Department of Radiation Medicine, UNTH, Ituku Ozzala, Enugu, Nigeria

ABSTRACT

Purpose: One-stage anastomotic urethroplasty is an attractive procedure for reconstructing the urethra following trauma. This prospective study highlights the advantages of the procedure and outcome of treatment. **Materials and Methods:** A total of 87 patients, age range 11–68 years with a mean of 35.4 years were included in the study. These patients were seen at two tertiary Institutions in South East Nigeria. The stricture lengths varied between 0.8 cm and 3.2 cm. All had suprapubic cystostomy initially followed by an end to end perineal anastomosis after thorough work up. Preoperatively 9 (10.3%) patients had impotence from the trauma. Postoperatively the patients were assessed with peri-catheter retrograde urethrogram, micturating cystourethrogram, and uroflowmetry. **Results:** All the patients were males. At 6 months, 13 out of 21 (62%) patients who had bulbo-prostatic anastomosis and 62 out of 66 (94%) patients that had bulbo-membranous, bulbo-bulbar anastomosis had satisfactory micturition with urine flow rate >15 ml/s. Totally, 12 (13.8%) patients had urine flow rate of <12 ml/s. At 1-year, there were 12 re-strictures, no urinary incontinence and four cases of a decrease in the strength of penile erection that needed no treatment. **Conclusion:** Delayed one-stage anastomotic urethroplasty provides for decreased incidence of postoperative morbidity, re-stricture, impotence and urinary incontinence for most short segment posttraumatic urethral strictures.

KEYWORDS: One-stage anastomotic urethroplasty, pelvic trauma, urethral trauma

INTRODUCTION

Posterior urethral trauma is classically associated with pelvic fractures^[1-6] with pelvic fracture incidence of approximately 20/100,000 in men and 29/100,000 in women in the Western world.^[2] These posterior urethral injuries occur in 3.5–19% males and 0–6% females^[5-7] with an overall peak of 25%.^[1,3,6,8] However, the traditional mechanism of injury has been called into question.^[7,9,10] The injury now is thought to be avulsion of the membranous urethra off the bulbous urethra, which may be partial or complete at the bulbo-membranous junction.^[7,9-12] Furthermore, the injury is not caused by pelvic fracture but due to disruption of the pelvic ring.^[12,13] Urinary bladder injuries occur in association with posterior urethral injuries in 10–20% of cases.^[3,6,7]

Address for correspondence:

Dr. Charles Azuwike Odoemene,
Department of Surgery, Urology Unit, Federal Teaching Hospital,
Abakaliki, Ebonyi State, Nigeria.
E-mail: odoemenec@yahoo.com

Access this article online

Quick Response Code:



Website: www.nigerianjsurg.com

DOI:
10.4103/1117-6806.162574

Anterior urethral trauma is mostly due to perineal straddle injury^[1,2,5-7,12] and traumatic urethral instrumentation.^[6,7,14]

Blood at the tip of the meatus is a cardinal sign of urethral trauma and is seen in 37–93% of posterior urethral trauma and 75% of anterior urethral trauma.^[5] In female patients, blood is present at the vaginal introitus in more than 80% of cases of pelvic fractures coexisting with urethral injuries.^[5,15] Blunt trauma accounts for more than 90% of urethral injuries.^[5,15] Wide arrays of the technique exist in the reconstructive surgery for urethral rupture. Excision and spatulated end-to-end anastomosis is the gold standard for single short traumatic stricture of bulbous urethra and distraction defects of posterior urethra with success rates of 98.8%,^[16] 95%,^[17] 92%, and 69% in some series.^[18]

This prospective study was to find out the outcome and complications in 87 patients who had delayed one stage perineal anastomotic urethroplasty post urethral rupture in two tertiary health institutions between January 2004 and January 2013.

This is an open access article distributed under the terms of the Creative Commons Attribution-NonCommercial-ShareAlike 3.0 License, which allows others to remix, tweak, and build upon the work non-commercially, as long as the author is credited and the new creations are licensed under the identical terms.

For reprints contact: reprints@medknow.com

How to cite this article: Odoemene CA, Okere P. One-stage anastomotic urethroplasty for traumatic urethral strictures. January 2004-January 2013. *Niger J Surg* 2015;21:124-9.

MATERIALS AND METHODS

All the patients had preliminary urinary diversion by way of suprapubic cystostomy using size 22/24F two-way Foley catheter. There was good history taking and thorough physical examination, more serious injuries were addressed and patient made stable before evaluation for urethral trauma. Micturating cystourethrogram and retrograde urethrogram were used to determine the site and extent of distraction defect/stricture. A detailed history of erectile function pre- and post-urethral trauma was sought and documented before urethroplasty.

Exclusions

- Trauma to the penile urethra
- Defects/strictures >3.5 cm
- Associated bladder/bladder neck injuries.

Eighty-seven male patients who met the inclusion criteria had delayed one stage anastomotic urethroplasty via the perineum during the study period. Data collected from the patients during the study were analyzed using both descriptive and inferential statistical analytical tools *viz*: Tables and pie chart. All the analyses were done using Statistical Package for Social Sciences (SPSS Version 17.0. Chicago).

Technique of urethroplasty

Before embarking on urethroplasty, any identified urinary tract infection was eliminated using appropriate antibiotics. The patient is placed in a lithotomy position after spinal anesthesia. Parenteral antibiotics depending on the sensitivity pattern and metronidazole were given with anesthesia. Via a midline perineal skin incision, the subcutaneous tissue and Cole's fascia are cut through exposing bulbospongiosus muscle. The later is separated with the bulbous urethra trauma in view [Figure 1]. Membranous/bulbous urethra is mobilized and the strictured segment and scar tissue excised completely. Proximal and distal urethral segments are spatulated dorsally and ventrally, respectively. Tension free mucosa to mucosa anastomosis of proximal and distal urethral

ends is commenced at 12 o'clock using 3/0 or 4/0 vicryl suture. After two anastomosis are carried out on either side, a size 16F 100% silicone catheter is introduced into the urinary bladder. The anastomosis is completed with the knots outside the urethral lumen [Figure 2]. The wound is closed leaving a wound drain. The later is removed by the 4th day posturethroplasty. Urine drainage is through the suprapubic cystostomy catheter and is removed after satisfactory micturition on removal of the urethral stent.

Assessment

Pericatheter retrograde urethrogram is done in the 3rd week after surgery to assess the integrity of the anastomosis [Figure 3]. If there is no leakage, the catheter is removed by the 4th week. If there is leakage, the catheter is left and removed at 5 weeks after ensuring no urinary tract infection. Micturating cystourethrogram is done in patients who did not do pericatheter contrast study on removal of the urethral stent. Uroflowmetry is done on removal of the catheter, at 6 months and at 12 months.

RESULTS

All the patients were males and 87 in number. The age range was 11–68 years with a mean of 35.4 years and standard deviation 10.5 years. All had one stage anastomotic urethroplasty by perineal approach during the study period of 9 years. Nine (10.3%) patients after the evaluation had erectile dysfunction following urethral trauma. Posturethroplasty four (4.6%) patients experienced a decrease in the quality of penile erection that needed no treatment while 74 (85.1%) patients retained their potency. Thirty-nine (44.8%) patients were in the fourth decade of life. Road traffic accident caused a urethral rupture in 46 (53%) patients followed by straddle injuries in 17 (19.5%) patients [Figure 4]. There were pelvic ring and sacroiliac joint disruptions in 31 (37%) patients [Table 1]. The site of posttraumatic stricture was bulbo-membranous in 39 (44.8%) patients, membranous in 17 (19.5%) patients, and bulbous 31 (35.6%) patients. Road traffic accident caused traumatic stricture in both membranous

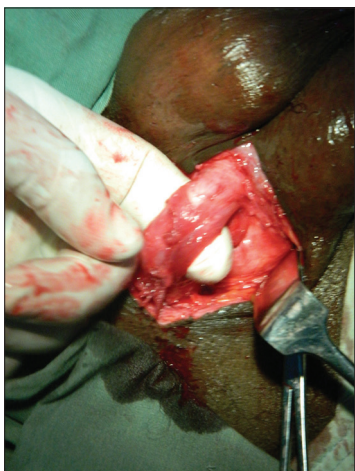

Figure 1: Bulbous urethra mobilized showing the stricture

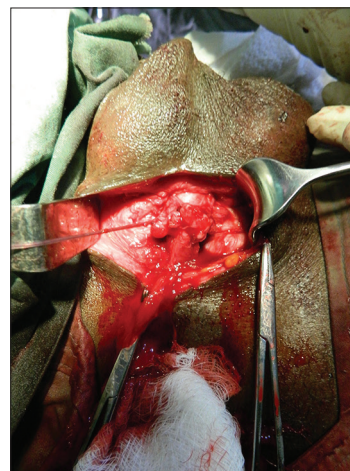


Figure 2: Anastomosis completed

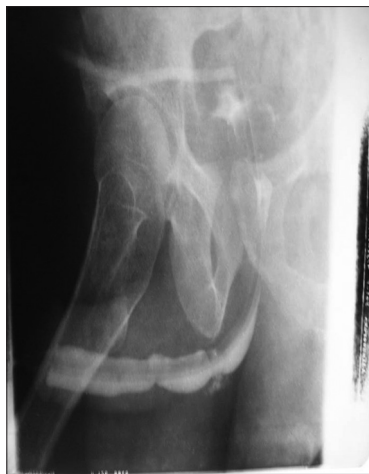

Figure 3: Post urethroplasty retrograde urethrogram

and bulbous segments of the urethra accounting for 52.8%. The stricture/defect length range was 0.8–3.2 cm with a mean of 1.9 cm. Thirty-one (35.6%) patients had bulbo-membranous anastomosis while 21 (24.2%) patients had bulbo-prostatic anastomosis. The remaining 31 (35.6%) had bulbo-bulbar anastomosis [Table 2].

On catheter removal, urine flow rate was >20 ml/s in 85 (97.7%) patients with satisfactory micturition. Two (2.3%) patients had urine retention as a result of neurogenic bladder.

At 6 months, 13 out of 21 (62%) patients who had bulbo-prostatic Anastomosis had satisfactory micturition with urine flow rate of >15 ml/s and remained so for the next 12 months. Furthermore, 62 out of 66 (94%) patients who had both bulbo-bulbar and bulbo-membranous anastomosis at 6 months, had urine flow rate of >17 ml/s, which was maintained till 12 months posturethroplasty. Thus, the success rates are 62% for bulbo-prostatic anastomosis and 94% for both bulbo-bulbar and bulbo-membranous anastomosis. At 5 years, 56 (64.3%) patients could be reached either through their mobile phones or at the urology clinic and micturition was satisfactory in all. Other patients were lost to follow-up. Success in this study is satisfactory micturition with urine flow rate of >15 ml/s posturethroplasty without further intervention either by dilatation or internal urethrotomy. Urethroplasty failure rate was 38.1% (8 patients) in those that had bulbo-prostatic anastomosis and 6.1% (4 patients) in those that had both bulbo-bulbar and bulbo-membranous anastomosis. In these patients, micturition was unsatisfactory, and flow rate was <12 ml/s.

Complications encountered in this study include scrotal swelling in 13 (15%) patients. The scrotal swelling was due to inflammatory edema arising from excessive dissection and handling of tissues during the urethroplasty. Wound infection in 5 (5.7%) patients, urinary tract infection in 11 (12.6%) patients, transient urinary incontinence in 7 (8%) patients, and re-stricture (8 membranous, 4 bulbous) in 12 (13.8%) patients.

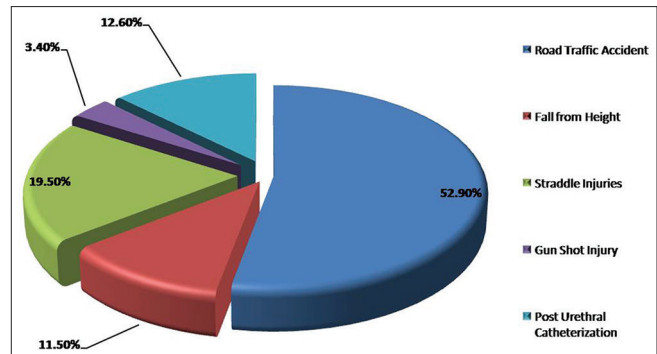


Figure 4: Etiology of injury

Table 1: Associated Injuries

Associated injuries	No of patients	Percentage
Pelvic fracture		
Pelvic ring fracture	26	37
Sacroiliac joint disruption	5	
Head injury	3	3.4
Rectal injury	2	2.3
Scrotal laceration	5	5.7
Impotence	9	10.3
Total	50	58.7

Table 2: Anastomotic sites

Type of anastomosis	No of patients	Percentage
Bulbo-prostatic	21	24.2
Bulbo-membranous	35	40.2
Bulbo-bulbar	31	35.6
Total	87	100

DISCUSSION

Urethral disruption following trauma is one of the most difficult conditions to manage in urology. Depending on the site and extent, various options are available for treatment. These include dilatation, urethral stenting, optical urethrotomy, perineal, urethral anastomosis, elaborate perineal, and perineal-abdominal transpubic procedures and substitution urethroplasty.^[19-24] The procedure adopted depends on various factors such as the site, length of defect, the extent of peri-urethral fibrosis, and genuine urethral stricture versus a distraction defect.^[19] Optical urethrotomy is appropriate in true strictures without breach of urethral epithelium and not effective in distraction defects where the proximal and distal ends are separated by scar/fibrotic tissue.^[19,25]

Tuner-Warwick in the 1970s popularized a delayed one-stage perineal approach of bulbo-prostatic anastomosis to bridge defects of 2.5 cm.^[26,27] We adopted this procedure in a prospective fashion in 87 patients to determine the outcome. However, defects/strictures in both the posterior and anterior urethra not more than 3.5 cm were included in the study. Furthermore, only strictures posterior to the bulbo-penile junction were involved in

the anastomosis. The main reason according to Chapple is that you cannot simply excise a stricture and restore continuity as in the gut without considering the impact of the urethral shortening on penile curvature during erection.^[24] Hence, penile urethral strictures were excluded.

All the patients had suprapubic cystostomy using sizes 22/24F 2 way Foley catheter pre delayed anastomosis. Use of such large caliber catheter makes it easy to pass a big size 30F sound via the cystostomy site with the tip palpated at the perineum before the commencement of the repair.^[28] Furthermore, the suprapubic catheter diverts urine from the injured urethra site while the patient stabilizes and recovers from associated injuries such as pelvic fracture, head injury before eventually facing the urologist with urethral defect/stricture, and its attendant problems of incontinence and impotence. Turner-Warwick correctly asserted that it is the urologist who will have to share the burden of the ultimate disability with the patient when the thoracic, abdominal, and even the orthopedic aspects are probably long forgotten.^[26]

The range of stricture length was 0.8–3.2 cm with a mean of 1.9 cm. A tension free one-stage anastomosis was achieved in all. The 3.2 cm stricture was in the bulbous urethra. Successful one stage anastomotic repair of 4.5 cm bulbous urethral stricture has been reported in other studies.^[16,17] The goal of urethroplasty for stricture is to provide an adequate caliber compliant and stable urethra.^[29-31] This is found in excision and end-to-end anastomosis and is regarded as gold standard.^[18,32] The elastic nature of the bulbous urethra makes it possible for a stretch of 2–4 cm to overcome a defect, even though 1 cm of this length is lost to spatulation.^[14,33] Adequate mobilization of the injured urethra was done in all the patients, excising all fibrous tissue before embarking on a tension free spatulated mucosa to mucosa anastomosis of proximal and distal urethral segments. The spatulation is critical in achieving a wide end to end anastomosis thereby overcoming any re-stenosis that may occur at the anastomotic site.^[14]

Four (46%) patients posturethroplasty experienced a decrease in the quality of erection that needed no treatment. Seventy four maintained their potency. An advantage of the perineal approach is this, once the dissection is strictly maintained in the midline the vascular supply and innervations of the corpora cavernosa can be spared thus averting erectile dysfunction. This has been noted in other studies.^[6,30,34] It was observed during follow-up that four out of the nine patients who had erectile dysfunction post urethral trauma, regained sexual activity 7–12 months post urethroplasty while the other five remained impotent. Koraitim and other authors also documented posturethroplasty regain of sexual function in some of their patients.^[23,35]

Furthermore, perineal anastomotic urethroplasty does not jeopardize the blood supply of the urethra. The corpus spongiosus has a bipedal blood supply and is partially dependent on retrograde flow from the dorsal artery of the penis when mobilized and detached from its proximal vascular supply.^[14,30,36]

Compromise of this distal circulation by trauma or distal urethral pathology leads to ischemic necrosis of the distal mobilized portion with obstructive sequelae of stricture.^[30]

Timing of urethroplasty after the patient had stabilized from associated injuries was determined in some patients by their economic status and was up to 24 months. Change of suprapubic catheters in these patients was not regular due to poor patient compliance. Furthermore, complications of catheterization such as hematuria, encrustations, and urinary tract infection occurred with the emergence of pathogens resistant to most of the antimicrobial agents. However, all urinary tract infections were treated before embarking on urethroplasty and the sensitivity pattern informed the use of antibiotics during and after surgery.

Success in this study was satisfactory urine flow rate ≥ 15 ml/s without any further intervention like dilatation or internal urethrotomy. This was noted in 13 (62%) out of 21 patients who had bulbo-prostatic anastomosis and in 62 (94%) out of 66 patients that had bulbo membranous, bulbo-bulbar anastomosis, respectively. Success rate for bulbo-prostatic anastomosis in this study is 62% when compared with the success rate of between 82% and 95% of the same operation in other studies.^[28,37-40] However, our success rate of 94% for bulbo-membranous and bulbous anastomosis in this study compared favorably with the success rates of between 91% and 98.8% for the same operation in other studies.^[16-18,36,41] The follow-up was up to 5 years in 56 (64.3%) patients who were seen in the clinic or contacted by a phone call and all had satisfactory micturition. However, there was a minimum follow-up of 14 months in all the patients posturethroplasty.

Re-stricture is suspected when the patient at follow-up presents with lower urinary tract symptoms and urine flow rate of < 15 ml/s. Confirmation was by retrograde urethrogram. Any patient posturethroplasty can have a re-stricture even after 10 years and must be followed up for life.^[27,32,41] A multiple linear regression analysis on the explicability of re-stricture tendency of the urethroplasty performed on the patients showed that, among site of the stricture, etiology of injury, age, and stricture length/defect, only the site of the stricture where the injury occurred (membranous, bulbo-membranous and bulbous) is significant (Beta 0.213, $P < 0.05$) at 5% level of significant. Other factors were not. This indicates that the initial site of the stricture had a significant impact on the patient's tendency of having a re-stricture after the urethroplasty. Other possible explanations for re-stricture are poor accessibility, inadequate excision of fibrous/scar tissue and inadequate mobilization of the distal bulbar segment resulting in anastomotic tension.^[42] Another critical factor favoring re-stricture in posterior urethroplasty in this study is nonuse of flexible cystoscope through the bladder neck during the surgery to visualize the proximal end of the urethral defect thus avoiding false passages.^[3] Meanwhile, out of the 12 (14%) patients who had re-stricture, eight were membranous while four others were bulbous. At Ibadan, a recurrent rate of 12.5% out of 16 patients that had urethroplasty

was recorded though the study was in children.^[43] Furthermore, a study at Nnewi got a restructure rate of 16.7% out of 12 patients that had urethroplasty.^[44]

Post urethroplasty urinary incontinence was noted in 7 (8%) patients and, which resolved within 7 months. The integrity of the distal sphincter is presumed to be compromised after posterior urethral trauma. Continence is solely maintained by the proximal internal sphincter. The proximal bladder neck sphincter and the distal sphincter mechanisms function independent of the other, and each is competent and independently capable of maintaining continence in the absence of the other.^[5,45] Future prostatectomy in these patients is not advised. However, some authorities have observed that function in the distal sphincter is preserved arguing that the site of urethral distraction is distal to it.^[9-11]

Other minor complications noted in this study, include scrotal swelling, wound infection, urinary tract infection, and urethro-cutaneous fistulae. They were successfully treated before the individual patient left the hospital.

CONCLUSION

The high and enduring success rates, low re-stricture rates, and minimal complications associated with one stage perineal anastomotic urethroplasty make it very attractive and the gold standard. It is recommended for use in reconstructing the ruptured urethra when the defect/stricture length permits.

Financial support and sponsorship

Nil.

Conflicts of interest

There are no conflicts of interest.

REFERENCES

- Ingram MD, Watson SG, Skippage PL, Patel U. Urethral injuries after pelvic trauma: Evaluation with urethrography. *Radiographics* 2008;28:1631-43.
- Mundy AR. Pelvic fracture injuries of the posterior urethra. *World J Urol* 1999;17:90-5.
- Hosseini J, Tavakkoli Tabassi K. Surgical repair of posterior urethral defects: Review of literature and presentation of experiences. *Urol J* 2008;5:215-22.
- Myers JB, McAninch JW. Management of posterior urethral disruption injuries. *Nat Clin Pract Urol* 2009;6:154-63.
- Martinez-Pineiro L. Urethral trauma. In: Hohenfellner M, Santucci RA, editors. *Emergencies in Urology*. 2007. p. 276-99.
- Chapple C, Barbagli G, Jordan G, Mundy AR, Rodrigues-Netto N, Pansadoro V, *et al*. Consensus statement on urethral trauma. *BJU Int* 2004;93:1195-202.
- Rosenstein DI, Alsikafi NF. Diagnosis and classification of urethral injuries. *Urol Clin North Am* 2006;33:73-85, vi.
- Hussain A, Pansota MS, Rasool M, Tabassum SA, Ahmad I, Saleem MS. Outcome of end-to-end urethroplasty in post-traumatic stricture of posterior urethra. *J Coll Physicians Surg Pak* 2013;23:272-5.
- Andrich DE, Mundy AR. The nature of urethral injury in cases of pelvic fracture urethral trauma. *J Urol* 2001;165:1492-5.
- Mouraviev VB, Santucci RA. Cadaveric anatomy of pelvic fracture urethral distraction injury: Most injuries are distal to the external urinary sphincter. *J Urol* 2005;173:869-72.
- Whitton JM, McAninch JW, Tanagho EA, Metro MJ, Rahman NU. Mechanism of continence after repair of posterior urethral disruption: Evidence of rhabdosphincter activity. *J Urol* 2008;179:1035-9.
- Mundy AR, Andrich DE. Urethral trauma. Part I: Introduction, history, anatomy, pathology, assessment and emergency management. *BJU Int* 2011;108:310-27.
- Andrich DE, Day AC, Mundy AR. Proposed mechanisms of lower urinary tract injury in fractures of the pelvic ring. *BJU Int* 2007;100:567-73.
- Mungadi IA, Mbibu NH. Current concepts in the management of anterior urethral strictures. *Niger J Surg Res* 2006;8:103-10.
- Perry MO, Husmann DA. Urethral injuries in female subjects following pelvic fractures. *J Urol* 1992;147:139-43.
- Eltahawy EA, Virasoro R, Schlossberg SM, McCammon KA, Jordan GH. Long-term followup for excision and primary anastomosis for anterior urethral strictures. *J Urol* 2007;177:1803-6.
- Santucci RA, Mario LA, McAninch JW. Anastomotic urethroplasty for bulbar urethral stricture: Analysis of 168 patients. *J Urol* 2002;167:1715-9.
- van den Heever AP, Lazarus J, Naude JH, Wiechers L, Tsheisi M. Retrospective outcome analysis of urethroplasty performed for various etiologies in a single South African centre. *Afr J Urol* 2012;18:127-30.
- Koraitim MM. Post-traumatic posterior urethral strictures: Preoperative decision making. *Urology* 2004;64:228-31.
- Koraitim MM. The lessons of 145 posttraumatic posterior urethral strictures treated in 17 years. *J Urol* 1995;153:63-6.
- Webster GD, Ramon J. Repair of pelvic fracture posterior urethral defects using an elaborated perineal approach: Experience with 74 cases. *J Urol* 1991;145:744-8.
- Turner-Warwick RT. Urethral stricture surgery. In: Glenn JF, editor. *Urological Surgery*, Philadelphia: J.B. Lippincott; 1983. p. 689-720.
- Morey AF, McAninch JW. Reconstruction of posterior urethral disruption injuries: Outcome analysis in 82 patients. *J Urol* 1997;157:506-10.
- Chapple C. Anterior urethral surgery: Current concepts and future directions. *Eur Urol* 2010;58:42-5.
- Mundy AR, Andrich DE. Urethral trauma. Part II: Types of injury and their management. *BJU Int* 2011;108:630-50.
- Turner-Warwick R. A personal view of the management of traumatic posterior urethral strictures. *Urol Clin North Am* 1977;4:111-24.
- Hafez AT, El-Assmy A, Sarhan O, El-Hefnawy AS, Ghoneim MA. Perineal anastomotic urethroplasty for managing post-traumatic urethral strictures in children: The long-term outcome. *BJU Int* 2005;95:403-6.
- Morey AF, McAninch JW. Reconstruction of posterior urethral disruption injuries: Outcome analysis in 82 patients. *J Urol* 1997;157:506-10.
- Barbagli G, Selli C, Tosto A. Reoperative surgery for recurrent strictures of the penile and bulbous urethra. *J Urol* 1996;156:76-7.
- Aghaji AE, Odoemene CA. One-stage urethroplasty for strictures: Nigerian experience. *Int J Urol* 2001;8:380-5.
- Ibrahim AG, Ali N, Aliyu S, Bakari AA. One-stage urethroplasty

- for strictures in maiduguri, north eastern Nigeria. ISRN Urol 2012;2012:847870.
32. Barbagli G, Palminteri E, Bartoletti R, Selli C, Rizzo M. Long-term results of anterior and posterior urethroplasty with actuarial evaluation of the success rates. *J Urol* 1997;158:1380-2.
 33. Andrich DE, Mundy AR. Urethral strictures and their surgical treatment. *BJU Int* 2000;86:571-80.
 34. Ennemoser O, Colleselli K, Reissigl A, Poisel S, Janetschek G, Bartsch G. Posttraumatic posterior urethral stricture repair: Anatomy, surgical approach and long-term results. *J Urol* 1997;157:499-505.
 35. Koraitim MM. On the art of anastomotic posterior urethroplasty: A 27-year experience. *J Urol* 2005;173:135-9.
 36. Morey AF, Kizer WS. Proximal bulbar urethroplasty via extended anastomotic approach - What are the limits? *J Urol* 2006;175:2145-9.
 37. Al-Rifaei MA, Zaghoul S, Al-Rifaei AM. Bulboprostatic anastomotic urethroplasty with preservation of potency: Anatomical study, operative approach and clinical results. *Scand J Urol Nephrol* 2005;39:163-8.
 38. Koraitim MM. Failed posterior urethroplasty: Lessons learned. *Urology* 2003;62:719-22.
 39. Aydos MM, Memis A, Yakupoglu YK, Ozdal OL, Oztekin V. The use and efficacy of the American Urological Association Symptom Index in assessing the outcome of urethroplasty for post-traumatic complete posterior urethral strictures. *BJU Int* 2001;88:382-4.
 40. Hosseini J, Tavakkoli Tabassi K. Surgical repair of posterior urethral defects: Review of literature and presentation of experiences. *Urol J* 2008;5:215-22.
 41. Andrich DE, Dungalison N, Greenwell TJ, Mundy AR. The long-term results of urethroplasty. *J Urol* 2003;170:90-2.
 42. Dakum NK, Ramyil VM, Amu CO. Outcome of urethroplasty for urethral stricture at Jos University Teaching Hospital. *Niger J Clin Pract* 2008;11:300-4.
 43. Shittu OB. Urethroplasty for strictures in Nigerian children. *Niger J Surg Res* 2002;4:80-3.
 44. Nwofor AM, Ugezu AI. Urethral stricture management. Experience at Nnewi South east Nigeria. *Afr J Urol* 2004;10:107-11.
 45. Turner-Warwick R. Observations on the treatment of traumatic urethral injuries and the value of the fenestrated urethral catheter. *Br J Surg* 1973;60:775-81.

