

The Utility of Digital Rectal Examination in Estimating Prostate Volume in a Rural Hospital Setting

EI Udeh, NK Dakum¹, SA Aderibigbe, JA Edeh²

Department of Surgery, University of Nigeria Teaching Hospital, Enugu, ¹Jos University Teaching Hospital, Jos, ²Enugu State University Teaching Hospital, Parklane, Enugu, Nigeria

ABSTRACT

Objectives: To determine the correlation between prostate volume estimated by digital rectal examination (DRE) and that estimated by abdominal ultrasound in the same patients. **Patients and Methods:** Men who presented to our urology outpatient clinic with lower urinary tract symptoms were recruited in this study. We estimated the prostate size by digital rectal examination using the sliding scale as a guide and subsequently measured the prostate volume by transabdominal ultrasound. **Results:** A total of 100 patients completed this study. The mean age was 65.6 ± 9.84 years. The Kappa's reliability test comparing the prostate size estimated by DRE and the prostate size measured by transabdominal ultrasound was 0.579832, the Kappa's standard error was 0.097768 and Kappa's *t* value was 5.93. The Kappa's reliability test fell into good agreement range (0.4–0.75). This is further validated by the Pearson's correlation test ascertaining correlation between Ultrasound and DRE and generated a correlation coefficient[®] of 0.59 ($P = 0.00$). This implies a high positive correlation between ultrasound estimated prostate volume and that estimated by DRE that is statistically significant ($P < 0.01$). **Conclusion:** Estimation of prostate volume by digital rectal examination is reliable. This is very important in an environment where esoteric laboratory facilities are not readily available, and the clinician has to depend mainly on his clinical acumen.

KEYWORDS: Digital rectal examination, prostate volume, rural hospital setting, utility

INTRODUCTION

Estimation of prostate volume has been found to be important for choosing a surgical technique (ranging from minimally invasive to open surgery) as well as medical treatment.^[1,2] It is also important for prediction of the duration of surgery and blood loss, especially for surgeons with little experience.^[3] Although prostate volume does not correlate with symptomatology, as patients with small prostate can have significant symptoms while those with large prostate mild symptoms, International prostate Symptom Score (IPSS) remains relevant in all settings in determining whether it is mild, moderate or severe benign prostatic hyperplasia (BPH). For the patients that may require

Address for correspondence:

Dr. Emeka ihechi Udeh,
Department of Surgery, University of Nigeria Teaching Hospital,
Ituku-Ozalla, Enugu.
E-mail: ihechiudeh@yahoo.com

Access this article online

Quick Response Code:



Website: www.nigerianjsurg.com

DOI:
10.4103/1117-6806.162570

medical therapy based on IPSS, the size of the prostate determines those that will benefit from combination therapy (alpha adrenergic blocker and 5 alpha reductase inhibitor).^[4,5]

Various methods have been applied in the past to estimate prostate size preoperatively. Prostate size estimation can be done clinically or with the aid of imaging techniques. Over the years, supremacy of imaging techniques has been established over clinical estimation of prostate size by digital rectal examination.^[6]

Initially, estimation of prostate volume was done by transabdominal ultrasound but this has transitioned to the use of transrectal ultrasound. With respect to prostate volume estimation there is no significant difference between measured prostate volumes;^[7] if the comfort of the patient is being considered, suprapubic ultrasound has an advantage over transrectal ultrasound (TRUS) since it is better tolerated.^[8]

In most rural hospital centers in Sub-Saharan Africa, contemporary imaging modalities are unaffordable and most times unavailable^[9] so relying on it to estimate prostate volume limits the surgeon. In such situations, relying on digital rectal estimation (DRE) becomes imperative. The issue becomes how reliable it is. A lot of measures have been undertaken to standardize DRE estimation of prostate volume.^[10,11] Notable is the grading scale^[11] which categorized the prostate volume using a range from zero to 4+. The grade is as follows: (1) Normal gland (20 g); about the size of a chest nut _____ 0. (2) Enlarged prostate gland (about

25 g); about the size of a plum and occupies a bit $< 1/4^{\text{th}}$ of the rectum lumen_____1+. (3) Enlarged prostate gland (about 50 g); about the size of a lemon and fills somewhat $> 1/2$ of the rectum_____2+. (4) Enlarged prostate gland (about 75 g); about the size of an orange and fills approximately three-fourth of the rectal diameter_____3+. (5) Enlarged prostate gland (about 100 g); may attain the size of a grape fruit and fills so much of the rectal lumen that adequate examination is difficult_____4+.

This study is aimed at determining the reliability of DRE in estimating prostatic volume using the sliding scale. Establishing the reliability of digital rectal examination in estimating prostate volume would lend more credence to using it as a substitute in areas where ultrasound is unavailable.

PATIENTS AND METHODS

A total of 150 patients who presented with lower urinary tract symptoms at the urology outpatient clinics in Jos University Teaching Hospital (JUTH) in 2008 were included in the study. The study was approved by the JUTH Ethical committee. Informed consent was obtained from all patients recruited for the study.

All consented patients with PSA greater than 4 ng/ml or abnormal digital rectal examination were subjected to transrectal biopsy specimen of the prostate for histological diagnosis. Those with biopsy evidence of prostate cancer detected at any point during the study were excluded. Fifty patients did not do an ultrasound so were excluded.

The prostatic volume determination was categorized into not significantly enlarged (prostate volume < 50 ml and significantly enlarged (prostate volume > 50 ml).

For each patient, a DRE was done by the same urologist (5 years' experience) and the volume of the prostate was estimated and categorized into not significantly enlarged or significantly enlarged using the grading scale.^[11]

1. Not significantly enlarged: equivalent to grade 0–1 (grading scale); equivalent to size of a chest nut; slightly protruding into rectum; below 50 ml
2. Significantly enlarged: equivalent to grade 2 (grading scale) to grade 3; fills somewhat $< 1/2$ of the rectum of the rectum to three-fourth of the rectum; above 50 ml.

Subsequently, patients were then sent for transabdominal suprapubic ultrasound that is done within a week following DRE. For the abdominal ultrasound, patients were requested to attend with a full bladder. In each patient, transabdominal ultrasound was performed with a GE logic S expert 052128 model ultrasound. Transabdominal ultrasound for all patients recruited for the study was performed by the same consultant radiologist (6 years' experience) to remove interobserver

difference, using a 3.5 MHz curvilinear scanner, with each patient scanned in the supine position. Prostate volume ($V \text{ cm}^3$) was then calculated using the formula $V = \alpha \times \beta \times \gamma \times \pi \ / 6$; where α is transverse diameter; β is anterior-posterior diameter; γ is the longitudinal diameter; $\pi \ / 6$ is 0.52.^[12]

The data generated in the study was analyzed by STATA/IC (Stata Corp LP, Texas USA) 13.1 and Microsoft excel sheet 2012 (Microsoft Campus, Thames Valley Park Reading, Berkshire, RG6 1WG); level of significance was set at a two-tailed $P < 0.01$. Kappa's reliability test was used to test for the level of agreement. A value of between 0.4 and 0.75 implies a significant agreement between the two variables. Pearson's correlation was used to assess the correlation between the two variables.

RESULTS

One hundred patients completed the study. The ages of the patients were between 49 and 78 years.

The mean age was 65.6 ± 9.84 years while the peak age group was 60–69 years [Figure 1.0].

The mean prostate volume based on transabdominal ultrasound estimation was 72.79 ± 44.38 ml and the range was 14.83–223.82 ml. The median prostate volume was 62 ml

Of the 100 patients, three had no significant prostate enlargement on both digital rectal examination and suprapubic ultrasound. One patient had significant prostate enlargement on suprapubic ultrasound only. Three patients had significant prostate enlargement on digital rectal examination only while 93 patients had significant prostate enlargement on both digital rectal examination and suprapubic ultrasound as shown in Figure 1.1.

In addition, following Kappa's reliability test for the above data, the Kappa's reliability test was 0.579832, the Kappa's standard error was 0.097768 and Kappa's t value was 5.93. The Kappa's reliability test fell into the good agreement range (0.4-0.75). This

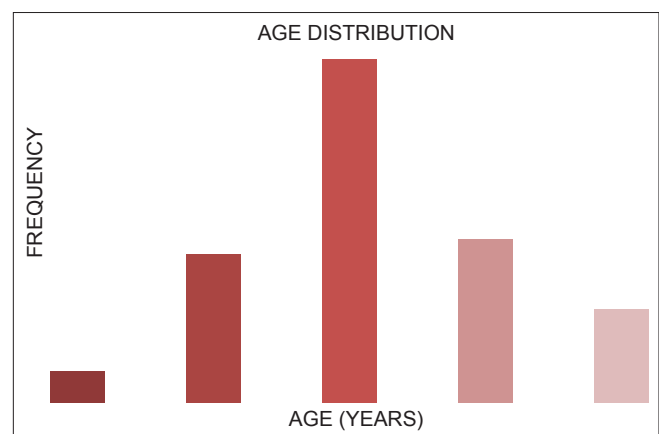


Figure 1.0: Age distribution of 100 patients with benign prostatic hyperplasia

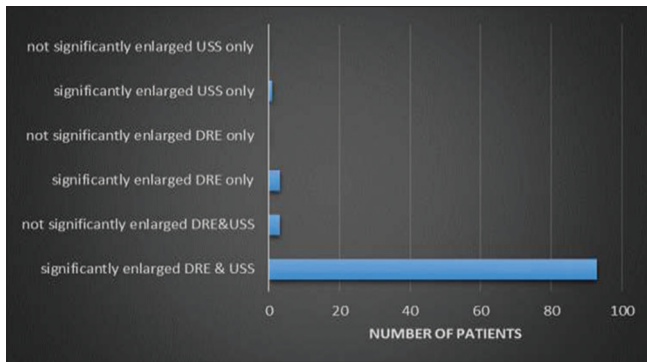


Figure 1.1: Bars depicting correlation between ultrasound and digital rectal examination

is further validated by the Pearson’s correlation test ascertaining correlation between Ultrasound and DRE and generated a correlation coefficient[®] of 0.59 ($P = 0.00$) as shown in Figure 1.2. This implies a high positive correlation between ultrasound estimated prostate volume and that estimated by DRE that is statistically significant ($P < 0.01$).

DISCUSSION

In this study, there was significant agreement in the accuracy of DRE in determining enlarged prostate compared to ultrasound. Both Varenhorst *et al.*^[13] and Cheng *et al.*^[14] in separate studies proved that DRE done by a urologist had a higher predictive value. This agrees with the findings of our study.

Various attempts have been made to standardize the outcome of the results following DRE.^[10,11] The grading scale is one of such methods that tried to standardize clinical estimation of prostate size.^[11]

Though, DRE is very important in initial evaluation of patients with lower urinary tract symptoms and suspected BPH, it is a poor predictor of actual size of prostate, compared to TRUS, computed tomography scan, or magnetic resonance imaging.^[6] A study by Streich *et al.*^[15] showed that DRE despite the high diagnostic value, for a large part is subjective and needs to be objectified by means of ultrasound examination. Prostate volume estimated with DRE is subject to interobserver variation.^[13] Estimation of prostate volume by DRE appears bigger than evaluated by TRUS.^[16] In this study, three patients’ prostate volumes were overestimated by DRE compared to Ultrasound.

Cheng *et al.*^[14] have shown that the trained urologist is more accurate in estimating prostate volume with DRE than a urology junior trainee, as the difference between their discrepancies is statistically significant. The difference between the discrepancies becomes insignificant if the trained urologist and the urology higher trainee are compared.

Although, evidences abound on the inferiority of determining prostate volume by DRE compared to imaging studies. It is of

.pworth uss DRE, obs sig star(5)		
	uss	DRE
uss	1.0000	
	100	
DRE	0.5931*	1.0000
	0.0000	
	100	100

Figure 1.2: Correlation between digital rectal examination and ultrasound prostate volume estimation

note to emphasize its value in a resource poor setting where such imaging studies are unavailable. More so, DRE estimated prostate volume has been proven by various studies including this study to correlate with prostate volume estimated by ultrasound if done by a urologist. As such relying on DRE in a resource poor setting may not be completely out of place. It is important to emphasize the importance of detecting significantly enlarged prostate in medical management. Significantly enlarged prostate (50 ml) respond effectively to combination therapy (alpha adrenergic blocker and 5-alpha reductase inhibitors).^[4,5] Any guide to identify patients who will benefit from such therapy will aid appropriate management of BPH. Arguably, giving combination therapy blindly to those with not significantly enlarged prostate in the absence of any reliable guide will increase the cost of medical management, which will further increase the financial burden on the already impoverished populace. A combination of IPSS to determine the severity of BPH and DRE estimated prostate volume to determine those with moderate or severe BPH who will benefit from combination therapy will be a possible guide for cost effective treatment for BPH in a rural setting.

Several studies have been done to assess the reliability of abdominal ultrasound in estimating prostate volume, and they demonstrated reliability.^[8,17] A local study conducted by Ibinaye *et al.*^[18] at UCH Ibadan also demonstrated that the abdominal ultrasound correlated well with TRUS in the measurement of prostate volume.

Separate studies where prostate volume estimated by transabdominal ultrasound was compared with the actual prostate size following prostatectomy showed significant correlation.^[19]

CONCLUSION

Estimation of prostate volume by digital rectal examination is reliable. This is very important in an environment where esoteric laboratory facilities are not readily available, and the clinician has to depend mainly on his clinical acumen.

REFERENCES

1. Madersbacher S, Marberger M. Is transurethral resection of the prostate still justified? *BJU Int* 1999;83:227-37.
2. Kurita Y, Ushiyama T, Suzuki K, Fujita K, Kawabe K. Transition zone ratio and prostate-specific antigen density: the index of response of benign prostatic hypertrophy to an alpha blocker. *Int J Urol* 1996;3:361-6.
3. Aus G, Bergdahl S, Hugosson J, Norlén L. Volume determinations of the whole prostate and of adenomas by transrectal ultrasound in patients with clinically benign prostatic hyperplasia: correlation of resected weight, blood loss and duration of operation. *Br J Urol* 1994;73:659-63.
4. Boyle P, Gould AL, Roehrborn CG. Prostate volume predicts outcome of treatment of benign prostatic hyperplasia with finasteride: meta-analysis of randomized clinical trials. *Urology* 1996;48:398-405.
5. Presti JC. Neoplasms of the prostate gland. In: Tanagho EA, McAninch JW, editors. *Smith's General Urology*. Singapore: McGraw-Hill Education; 2004. p. 753.
6. Roehrborn CG, Cynthia J, Girman CJ, Rhodes T, Karen A, Gerald NC. Correlation between prostate sizes estimated by digital rectal examination and measured by transrectal ultrasound. *Urology* 1997;49:548-57.
7. Prassopoulos P, Charoulakis N, Anezinis P, Daskalopoulos G, Cranidis A, Gourtsoyiannis N. Suprapubic versus transrectal ultrasonography in assessing the volume of the prostate and the transition zone in patients with benign prostatic hyperplasia. *Abdom Imaging* 1996;21:75-7.
8. Henneberry M, Carter MF, Neiman HL. Estimation of prostatic size by suprapubic ultrasonography. *J Urol* 1979;121:615-6.
9. Ostensen H. Developing countries. *Ultrasound Med Biol* 2000;26 Suppl 1:S159-61.
10. Yeboah ED. The prostate gland. In: Bodoie EA, editor. *Principles and Practice of Surgery Including Pathology in the Tropics*. 3rd ed. Ghana: Ghana Publishing Corporation; 2000. p. 850-7.
11. Grayhack JT, Mcvary KT, Kozlowski JM. Benign prostatic hyperplasia. In: Gillenwater JY, editor. 4th ed. USA: Lippincott Williams and Wilkins; 2002.
12. Aarnink RG, de la Rosette JJ, Debruyne FM, Wijkstra H. Formula-derived prostate volume determination. *Eur Urol* 1996;29:399-402.
13. Varenhorst E, Berglund K, Löfman O, Pedersen K. Inter-observer variation in assessment of the prostate by digital rectal examination. *Br J Urol* 1993;72:173-6.
14. Cheng WC, Ng FC, Chan KC, Cheung YH, Chan WL, Wong SW. Interobserver variation of prostatic volume estimation with digital rectal examination by urological staffs with different experiences. *Int Braz J Urol* 2004;30:466-71.
15. Streich U, Rockstroh H, Anger G, Weck B, Millner R. Objective determination of prostate size with ultrasound. *Z Urol Nephrol* 1980;73:577-81.
16. Smith HJ, Haveland H. Pre-operative and post-operative volumetry of the prostate by transabdominal ultrasonography. *Br J Urol* 1982;54:531-5.
17. Watanabe T, Miyagawa I. New simple method of transabdominal ultrasound to assess the degree of benign prostatic obstruction: size and horizontal shape of the prostate. *Int J Urol* 2002;9:204-9.
18. Ibinaye PO, Adeyinka AO, Obajimi MO. Comparative Evaluation of prostatic volume by transabdominal and transrectal ultrasonography in patients with prostatic hypertrophy in Ibadan. *Eur J Sci Res* 2005;10:1-2.
19. Abu-Yousef MM, Narayana AS. Transabdominal ultrasound in the evaluation of prostate size. *J Clin Ultrasound* 1982;10:275-8.

How to cite this article: Udeh EI, Dakum NK, Aderibigbe SA, Edeh JA. The utility of digital rectal examination in estimating prostate volume in a rural hospital setting. *Niger J Surg* 2015;21:111-4.

Source of Support: Nil, **Conflicts of Interest:** None declared.