

Endoscopic Evaluation of Upper and Lower Gastro-Intestinal Bleeding

Emeka Ray-Offor, Solomon N Elenwo

Department of Surgery, University of Port Harcourt Teaching Hospital and Digestive Disease Unit, Oak Endoscopy Centre, Port Harcourt, Rivers State, Nigeria

ABSTRACT

Introduction: A myriad of pathologies lead to gastro-intestinal bleeding (GIB). The common clinical presentations are hematemesis, melena, and hematochezia. Endoscopy aids localization and treatment of these lesions. **Aims:** The aim was to study the differential diagnosis of GIB emphasizing the role of endoscopy in diagnosis and treatment of GIB. **Patients and Methods:** A prospective study of patients with GIB referred to the Endoscopy unit of two health facilities in Port Harcourt Nigeria from February 2012 to August 2014. The variables studied included: Demographics, clinical presentation, risk score, endoscopic findings, therapeutic procedure, and outcome. Data were collated and analyzed using SPSS version 20 software. **Results:** A total of 159 upper and lower gastro-intestinal (GI) endoscopies were performed during the study period with 59 cases of GI bleeding. There were 50 males and 9 females with an age range of 13–86 years (mean age 52.4 ± 20.6 years). The primary presentations were hematochezia, hematemesis, and melena in 44 (75%), 9 (15%), and 6 (10%) cases, respectively. Hemorrhoids were the leading cause of lower GIB seen in 15 cases (41%). The majority of pathologies in upper GIB were seen in the stomach (39%): Gastritis and benign gastric ulcer. Injection sclerotherapy was successfully performed in the hemorrhoids and a case of gastric varices. The mortality recorded was 0%. **Conclusion:** Endoscopy is vital in the diagnosis and treatment of GIB. Gastritis and Haemorrhoid are the most common causes of upper and lower GI bleeding respectively, in our environment

KEYWORDS: Endoscopy, diagnosis and treatment, gastro-intestinal bleeding

INTRODUCTION

Gastro-intestinal bleeding (GIB) is a frequent cause of hospital admission and mortality worldwide.^[1] The trend in USA is a decline in the incidence of upper GIB probably due to frequent prescription of proton pump inhibitors and *Helicobacter pylori* eradication drugs but a rising trend in lower GIB from increased rectal and anal bleeding.^[2]

An accurate patient evaluation and appropriate early resuscitative measures before an endoscopic intervention are essential to decrease the morbidity and mortality.^[3] Minimally invasive endoscopic interventions such as injection therapy, thermal coagulation, rubber

Address for correspondence:

Dr. Emeka Ray-Offor,
Department of Surgery, University of Port Harcourt Teaching Hospital,
P.M.B.6173, Port Harcourt, Nigeria.
E-mail: erayoffor@yahoo.com

Access this article online

Quick Response Code:



Website: www.nigerianjsurg.com

DOI:
10.4103/1117-6806.162575

band, and clip application have been shown to decrease the mortality rate and the need for surgery and blood transfusions.^[4]

In this prospective study, we aim to study comparatively the differential diagnosis of GIB emphasizing the role of endoscopy in the diagnosis and treatment of gastro-intestinal (GI) hemorrhage in a regional Nigerian population.

PATIENTS AND METHODS

Study population

All consecutive patients presenting with symptoms of hematemesis, melena, and hematochezia to the endoscopy unit of two private health facilities in Port Harcourt, from February 2012 to August 2014 were studied. The patients presented primarily to the centers or were referred from health facilities in Port Harcourt metropolis in Rivers state Nigeria and nearby states as the endoscopes in the regional tertiary health facility were out of function during the study period.

This is an open access article distributed under the terms of the Creative Commons Attribution-NonCommercial-ShareAlike 3.0 License, which allows others to remix, tweak, and build upon the work non-commercially, as long as the author is credited and the new creations are licensed under the identical terms.

For reprints contact: reprints@medknow.com

How to cite this article: Ray-Offor E, Elenwo SN. Endoscopic evaluation of upper and lower gastro-intestinal bleeding. *Niger J Surg* 2015;21:106-10.

Equipment

The procedures were carried out with 13801 PKS video gastroscope, 13925 PKS video colonoscope, light source/insufflator pump, and camera unit all made by Karl Storz (Germany).

Upper gastro-intestinal endoscopy

Pre-procedure

There was a pre-procedure assessment with clinical and laboratory evaluation of patients. A baseline hemoglobin and screen tests for HIV 1 and II and hepatitis B surface antigen were done for all patients. A seropositive screen indicated extra protective measures including disposable gown, goggles, and double hand gloves as infection control measures. Pre-procedure abbreviated Rockall score was assigned as a predictor of endosurgical intervention and blood transfusion.^[5] Additional laboratory evaluation was done for patients with abbreviated Rockall score of >2 (high-risk) including liver function test, clotting profile, and serum electrolytes, urea, and creatinine. Child-Pugh risk stratification was applied in any case of variceal bleeding from portal hypertension. An informed consent was obtained after oral explanations. Furthermore, a printed information leaflet was given to those literate. The patients were fasted for a minimum of 5 h before the procedure for elective cases. The procedure was performed with 10% lignocaine spray to the pharynx and sedation with at least 2.5 mg of intravenous diazepam and hyoscine butylbromide 20 mg. Prophylactic antibiotic: Intravenous third generation cephalosporin-ceftriaxone 1 g stat, was logically administered in diabetics, immunosuppressed patients, and before interventional procedures for upper GIB. Total intravenous anesthesia with endotracheal intubation was used in cases of acute upper GI bleeding using Propofol.

Procedure

All procedures were performed by the same surgeon (ERO). A systematic examination of the upper digestive tract was performed with video recording of the procedure. Mucosal biopsy of any suspicious lesion was taken and sample transported to the pathologist in formalin solution.

Lower gastro-intestinal endoscopy

Pre-procedure

Routine tests as for upper GI endoscopy were performed and informed consent obtained as earlier stated. There was bowel preparation prior to lower GI endoscopy with polyethylene glycol or tabs bisacodyl and castor oil or colostomy washout with 2 days dietary restriction preceding elective cases. Conscious sedation was achieved with intravenous diazepam 2.5 mg and pentazocine 30 mg. Hyoscine butylbromide 20 mg; an anti-spasmodic was administered. Furthermore, prophylactic antibiotics as in upper GI endoscopy was logically given with the addition of IV metronidazole 500 mg to the regimen for sclerotherapy. About 50% dextrose solution was the sclerosant in all cases of

hemorrhoid. 4% formalin and 1:10,000 adrenaline solutions were used as sclerosants for intractable diffuse mucosal bleeding and angiodysplasia, respectively.

Procedure

All procedures were performed by the same surgeon (ERO). Systematic examination of indicated segment of the lower digestive tract was performed. On withdrawal of an endoscope, hemorrhoids were injected using sclerotherapy needle passed through the 2.8 mm instrument channel of the retroflexed endoscope. In some cases, flexible endoscopy was completed then a rigid proctoscope was inserted and a 25 G spinal needle used to inject each hemorrhoidal pillar proximal to the dentate line using 2 mls of 50% dextrose solution at each site.

Variables

These included data on the sociodemographics, clinical presentation, risk score, indications, endoscopic findings, therapeutic procedure, and outcome.

Statistical analysis

Data were collated and analyzed for sex, age distribution, and frequency of disease conditions using IBM SPSS version 20 (Chicago IL, USA).

RESULTS

A total of 103 upper and 56 lower GI endoscopies were performed during the study period. There were 59 endoscopies for GI bleeding (37.1%). Fifty of these were in males and 9 in females; a male to female ratio of 6:1. The age and sex distribution are shown in Table 1. The peak incidence was in the 6th decade followed by the fourth (mean age of 52.4 ± 20.6 years). Only one case was seen in the pediatric age group (13 years). The primary clinical presentation was hematochezia in 44 (75%) patients [Figure 1]. Hematemesis was seen in 9 (15%) and melena in 6 (10%) of cases.

A low-risk pre-procedure abbreviated Rockall score of ≤ 2 was recorded in all but 4 cases of upper GI bleeding (high-risk). There was a full admission, further laboratory investigation, and blood transfusion before endoscopy in these high-risk patients. All other cases were managed on an outpatient basis. Gastritis was the most common pathology seen in the upper GI endoscopies performed 4 (17.4%), closely followed by benign gastric ulcers and duodenitis [Table 2]. Injection sclerotherapy was successfully performed in a case of isolated gastric varices using 5 ml of 1:10,000 adrenaline solutions. There was no case of esophageal varices from portal hypertension. Open surgery was performed in a case of acute bleeding from an ulcerated sub-mucosal cyst in the region of the ampulla of Vater following unsuccessful endoscopic intervention.

In contrast, hemorrhoid was the most common cause of lower GI bleeding followed by diverticular disease [Table 3]. Twelve cases of hemorrhoids had injection sclerotherapy using

50% dextrose water after sigmoidoscopy or full colonoscopy in those with coexisting pathology [Figure 2]. There was rebleed in two cases (16.7%) during a 6-week follow-up, which required a

repeat sclerotherapy performed via a proctoscope. Furthermore, sclerotherapy was performed for a solitary case of angiodysplasia in the distal colon using 5 mls of 1:10,000 adrenaline. Four percent formalin instillation was used for diffuse intractable mucosal bleeding of radiation proctitis and postchemotherapy mucosal bleeding of metastatic rectal cancer with marginal improvement in their clinical condition. A snare polypectomy with heat therapy was done for a rectal polyp. All but 3 cases of lower GI bleeding were managed on an out-patient basis. Open surgery was performed in two of these three cases of acute lower GIB following unsuccessful endoscopic intervention: Profuse bleeding from proximal colon obscuring endoscopic view (right hemicolectomy) and a case of partially obstructing malignant tumor of the sigmoid colon that required a diverting loop colostomy.

There was no mortality recorded in this study.

Table 1: Sociodemographics of patients with GIB cases

Age group (years)	Male	Female	Total (%)
0-10	0	0	0 (0)
11-20	2	1	3 (5.0)
21-30	1	0	1 (2.0)
31-40	15	1	16 (27.0)
41-50	3	4	7 (12.0)
51-60	18	1	19 (32.0)
61-70	2	0	2 (3.0)
71-80	5	2	7 (12.0)
81-90	4	0	4 (7.0)
Total	50	9	59 (100)

GIB: Gastro-intestinal bleeding

Table 2: Site distribution of pathology in cases of suspected upper GIB

Site	Pathology	Frequency (state)	Sex		Percentage
			Male	Female	
Pharynx	Pharyngitis	1 (active bleeding)	-	1	4
Esophagus	Esophagitis	2 (nonbleeding)	1	1	10
	Mallory-Weiss tear	1 (active bleeding)	1	-	
Stomach	Gastritis	4 (nonbleeding)	3	1	39
	Gastric ulcer	3 (forrest III)*	3	-	
	Gastric varices	1 (active bleeding)	1	-	
Duodenum	Fundal polyp	1 (active bleeding)	1	-	22
	Duodenitis	3 (active bleeding)	3	-	
	Obscure duodenal bleeding	1 (active bleeding)	1	-	
	Ulcerated duodenal mass	1 (forrest Ib)	1	-	
None	No pathology seen	5 (nonbleeding)	5	-	22
Total		23	20	3	100

GIB: Gastro-intestinal bleeding, *Forrest III (Figure 3)

Table 3: Lower GI endoscopies showing pathologies seen and interventional procedures performed

Procedure	Pathology	Frequency	Interventional procedure			
			IS ^a	Polypectomy	FI ^b	
Colonoscopy	Colorectal cancer	3	-	-	-	
	Proctocolitis	3	-	-	-	
	Angiodysplasia	1	-	-	-	
	Obscure colonic bleeding	1	-	-	-	
	Normal study	3	-	-	-	
	Diverticular disease	1	-	-	-	
	Diverticular disease and hemorrhoid	2	2	-	-	
Sigmoidoscopy (via stoma)	Hemorrhoids only	6	6	-	-	
	Metastatic rectal cancer postchemoRX	1	-	-	1	
	Sigmoidoscopy (conventional)	Rectal polyp	1	-	1	-
		Radiation proctitis	1	-	-	1
		Angiodysplasia	1	1	-	-
		Aborted (poor bowel preparation)	1	-	-	-
		Hemorrhoids only	3	3	-	-
Proctocolitis		4	-	-	-	
Proctoscopy	Hemorrhoid and diverticular disease	1	1	-	-	
	Hemorrhoids	3	3	-	-	
Total		36	16	1	2	

^aIS: Injection sclerotherapy, ^b4% Formalin instillation, GI: Gastro-intestinal

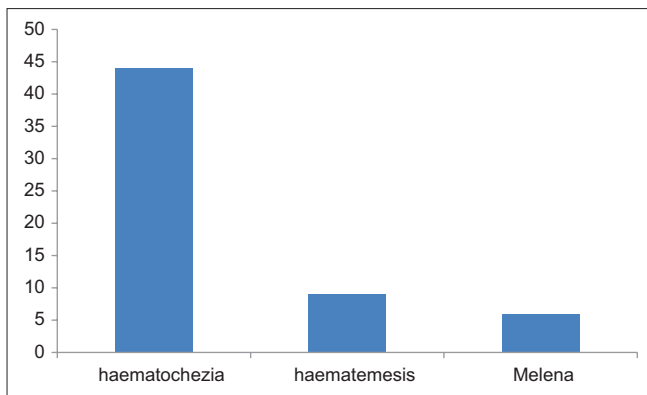


Figure 1: Clinical presentation of gastro-intestinal bleeding cases

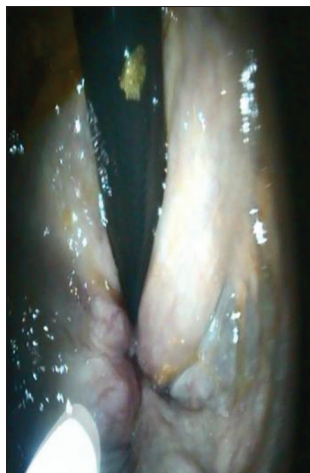

Figure 2: Injection sclerotherapy for internal hemorrhoid using retroflexed endoscope

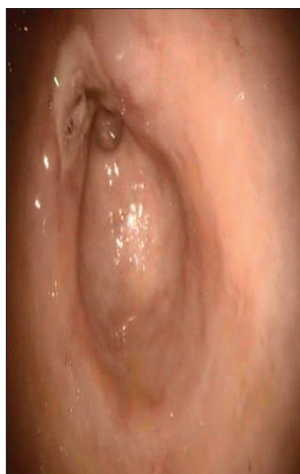

Figure 3: Forrest III gastric ulcer

DISCUSSION

Bleeding from the GI tract is a common cause of emergency hospital admission resulting in significant morbidity and mortality. The medical history, physical examination, and initial laboratory values are important in assessing resuscitation requirements,

triage, endoscopy timing, consultation requirements, and prognostication.^[6] In this study, the middle-aged and elderly patients (66%) were mostly affected with a peak in the 6th decade and predominance of males (85%). Olokoba *et al.* in Northwest Nigeria observed a similar age of peak incidence for upper and lower GIB.^[7,8] Yet a similar observation was recorded by Onyekwere *et al.* and Ajayi *et al.* from upper GI endoscopy and colonoscopy practice, respectively in the South-West of Nigeria.^[9,10] This deemphasizes regional variation in the disease condition among various populations in Nigeria.

Bleeding from the upper GI tract is reported to be approximately 4 times as common as bleeding from the lower GI tract.^[11] However, in our combined prospective study of upper and lower GI bleeding the reverse was the case. The most common presentation observed was hematochezia 44 (75%) patients. Hematemesis was seen in 9 (15%) cases and for melena 6 (10%) cases. The sight of an abnormal bleeding per os evokes significant anxiety. We observed a high acceptance of minimal access procedure (endoscopy) which offers an interventional option sparing patients the trauma of open surgery. Hemorrhoids were the most common cause of lower GIB in this study, which is similar to the findings from two tertiary health facilities with high turnover endoscopy units in Nigeria and Ghana.^[12,13] It was observed that the diverticular disease was the second most common cause of lower GIB. Manzoor *et al.*, in Pakistan also observed hemorrhoid to be the most common cause of lower GIB, with the least common etiology being a diverticular disease.^[14] In the US, diverticular diseases, internal hemorrhoids, and colorectal cancer are the common findings at colonoscopy.^[15]

The stomach was the most common site for upper GIB (39%) and gastritis, followed by gastric ulcers was the leading cause of upper GIB. Peptic ulceration in the duodenum or stomach is the condition most often responsible for life-threatening upper GI hemorrhage.^[16] In this study, there was no case of esophageal varices but a sole case of seropositivity to hepatitis B surface antigen in the mandatory pre endoscopy evaluation. The high endemicity of hepatitis B in the Far East and Southeast Asia, particularly, as well as South America, North Africa, Egypt, and other countries in the Middle East, often leads to liver decompensation and portal hypertension resulting in a high incidence of esophageal varices. In Northern Uganda where schistosomiasis in addition to hepatitis B infection is endemic esophageal varices were the leading cause of upper GIB.^[17,18]

Injection sclerotherapy is a cheap endoscopic hemostatic technique in non-variceal upper GIB with a success rate of 70–100% using several different agents.^[19] It proved effective in treating hemorrhoids and gastric varices. The basic mechanisms of action of these solutions include sclerosis, thrombosis (via endogenous clotting mechanisms or the formation of a plastic cast), and vascular tamponade. Four percent formalin instillation was used for intractable rectal bleeding for radiation proctitis and a case of post chemotherapy mucosal changes in metastatic rectal cancer with marginal improvement in condition.

The use of snare polypectomy with simultaneous diathermy heat application was successfully performed in a case of rectal polyp. Through-the scope and over-the-scope clips are also effective hemostatic agents in acute GI bleeding.^[20] In the setting of this study, availability, added the cost of endoscopy service from these effective devices to out-of-the pocket paying patients in a developing economy and expertise discouraged their use.

In approximately 5% of all patients with gastrointestinal hemorrhaging and anemia, standard evaluation with esophagogastroduodenoscopy and colonoscopy will not reveal a specific bleeding site.^[21] This was the case in 8 procedures (14%). It is well-known that the diagnostic yield and accuracy of endoscopy is usually greater within the first 24 h from onset of the bleeding. A late presentation was the trend in our study. This delay in presentation for evaluation allows for rapid healing of mucosal lesions. On the other end of the spectrum is obscure GIB, which often arises from the small bowel.^[22] This segment of the intestine is not readily accessible due to its intra-peritoneal location, excess mobility, and long length. We recorded a case of obscure lower GIB, which required exploratory laparotomy. The operative finding was a submucosal lipoma in the jejunum and pool of blood in the ascending colon. A resection of the involved segment of the jejunum with jejuno-jejunal anastomosis was performed in addition to a right hemi-colectomy. Pathology revealed an adenoma in the ascending colon. Currently, endoscopic innovations such as video capsule and double-balloon endoscopy have improved diagnostic yield in the small intestine.^[23] These are not readily available in our environment but of significance was the 0% mortality recorded in this study.

CONCLUSION

Endoscopy is vital in diagnosis and treatment of GIB. Gastritis and hemorrhoids are the most common causes of upper and lower GIB, respectively.

Financial support and sponsorship

Nil.

Conflicts of interest

There are no conflicts of interest.

REFERENCES

1. Fallah MA, Prakash C, Edmundowicz S. Acute gastrointestinal bleeding. *Med Clin North Am* 2000;84:1183-208.
2. El-Tawil AM. Trends on gastrointestinal bleeding and mortality: Where are we standing? *World J Gastroenterol* 2012;18:1154-8.
3. Cappell MS, Friedel D. Initial management of acute upper gastrointestinal bleeding: From initial evaluation up to gastrointestinal endoscopy. *Med Clin North Am* 2008;92:491-509, xi.
4. Adler DG, Leighton JA, Davila RE, Hirota WK, Jacobson BC, Qureshi WA, *et al.* ASGE guideline: The role of endoscopy in

- acute non-variceal upper-GI hemorrhage. *Gastrointest Endosc* 2004;60:497-504.
5. Stanley AJ, Dalton HR, Blatchford O, Ashley D, Mowat C, Cahill A, *et al.* Multicentre comparison of the Glasgow Blatchford and Rockall Scores in the prediction of clinical end-points after upper gastrointestinal haemorrhage. *Aliment Pharmacol Ther* 2011;34:470-5.
6. Kollef MH, O'Brien JD, Zuckerman GR, Shannon W. BLEED: A classification tool to predict outcomes in patients with acute upper and lower gastrointestinal hemorrhage. *Crit Care Med* 1997;25:1125-32.
7. Olokoba AB, Olokoba LB, Jimoh AA, Salawu FK, Danburam A, Ehalaiye BF. Upper gastrointestinal tract endoscopy indications in northern Nigeria. *J Coll Physicians Surg Pak* 2009;19:327-8.
8. Olokoba AB, Bojuwoye MO, Obateru OA. Lower gastro-intestinal tract bleeding in Ilorin, Nigeria. *Niger Med J* 2013;54:111-4.
9. Onyekwere CA, Hameed H, Anomneze EE, Chibututu C. Upper gastrointestinal endoscopy findings in Nigerians: A review of 170 cases in Lagos. *Niger Postgrad Med J* 2008;15:126-9.
10. Ajayi AO, Ajayi EA, Solomon OA, Udo E. Lower gastrointestinal bleeding: Spectrum of colonoscopy findings in Ado-Ekiti, Nigeria. *Int J Med Med Sci* 2014;6:128-33.
11. National Institute for Health and Care Excellence. Acute Upper Gastrointestinal Bleeding. June, 2012. Available from: <http://www.nice.org.uk/>. [Last accessed on 2014 Aug 29].
12. Alatise OI, Arigbabu AO, Agbakwuru EA, Lawal OO, Ndububa DA, Ojo OS. Spectrum of colonoscopy findings in Ile-Ife Nigeria. *Niger Postgrad Med J* 2012;19:219-24.
13. Dakubo J, Kumoji R, Naaeder S, Clegg-Lamptey J. Endoscopic evaluation of the colorectum in patients presenting with haematochezia at korle-bu teaching hospital accra. *Ghana Med J* 2008;42:33-7.
14. Manzoor A, Shah SA, Inam A. Etiologic Spectrum of Bleeding Per Rectum in Surgical Outpatient Department of a Tertiary Care Hospital. *Ann Pak Inst Med Sci* 2011;7:180-5, 180.
15. Gayer C, Chino A, Lucas C, Tokioka S, Yamasaki T, Edelman DA, *et al.* Acute lower gastrointestinal bleeding in 1,112 patients admitted to an urban emergency medical center. *Surgery* 2009;146:600-6.
16. Longstreth GF. Epidemiology of hospitalization for acute upper gastrointestinal hemorrhage: A population-based study. *Am J Gastroenterol* 1995;90:206-10.
17. Bwogi J, Braka F, Makumbi I, Mishra V, Bakamutumaho B, Nanyunja M *et al.* Hepatitis B infection is highly endemic in Uganda: findings from a national serosurvey. *Afr Health Sci* 2009;9: 98-108.
18. Alema ON, Martin DO, Okello TR. Endoscopic findings in upper gastrointestinal bleeding patients at Lacor hospital, northern Uganda. *Afr Health Sci* 2012;12:518-21.
19. Benedetti G, Sablich R, Lacchin T. Endoscopic injection sclerotherapy in non-variceal upper gastrointestinal bleeding. A comparative study of polidocanol and thrombin. *Surg Endosc* 1991;5:28-30.
20. Manta R, Galloro G, Mangiavillano B, Conigliaro R, Pasquale L, Arezzo A, *et al.* Over-the-scope clip (OTSC) represents an effective endoscopic treatment for acute GI bleeding after failure of conventional techniques. *Surg Endosc* 2013;27:3162-4.
21. American Gastroenterological Association medical position statement: Evaluation and management of occult and obscure gastrointestinal bleeding. *Gastroenterology* 2000;118:197-201.
22. Foutch PG. Angiodysplasia of the gastrointestinal tract. *Am J Gastroenterol* 1993;88:807-18.
23. Das K, Sarkar R, Dasgupta J, Ray S, Ghatak S, Das K, *et al.* Obscure GI bleeding in the tropics: Impact of introduction of double-balloon and capsule endoscopies on outcome. *Gastrointest Endosc* 2010;72:292-300.