

Broomstick Injuries to the Eye; an Emerging Cause of Blindness among Children in Nigeria

Catherine U Ukponmwan, Rita O Momoh

Department of Ophthalmology, University of Benin Teaching Hospital, Benin City, Nigeria

ABSTRACT

Background: Ocular trauma among children is responsible for a high incidence of uni-ocular blindness. **Objective:** To evaluate the pattern of presentation and complications from broomstick eye injury at University of Benin Teaching Hospital (UBTH), Benin City with a view to proffering solutions on ways to reduce this trend. **Materials and Methods:** The hospital records of all consecutive patients who suffered ocular trauma from broomstick injury and presented at the eye clinic of the UBTH between 2003 and 2014 were evaluated. Information retrieved from the case records included social demographic characteristics, interval between the occurrence of injury and presentation, mechanism of injury, activity at time of injury, examination findings, treatments and complications. Data were analyzed using SPSS, IBM, Chicago, USA. **Results:** A total of 20 eyes in 20 patients were seen. They were all children <14 years old. The mean age was 7.10 ± 4.03 (standard deviation) years. The male: female ratio was 3:1. Twelve children (60%) sustained trauma from broomstick shot as a missile with a rubber band and/or catapult sling by other children and siblings while at play. Ten children (50%) presented within 24 h of occurrence of the injury. Nineteen (95%, $n = 19$) of the children were blind at presentation in the affected eye with visual acuity ranging from count finger to no light perception. Ninety percent (90%) of the cases were open globe injuries. Only 10% ($n = 2$) were closed (lamellar) injuries. Most of the patients had multiple complications such as corneal laceration (80%), traumatic cataract (40%), endophthalmitis/panophthalmitis (55%) and orbital cellulitis (15%). **Conclusion:** Ocular trauma from broomstick results in devastating, penetrating eye injury with loss of vision. Young male children are vulnerable as targets of dangerous game-play. Primary prevention is important by sensitization of caregivers and children of the risks. There is a need for effective supervision of children when at play.

KEYWORDS: Broom stick, complications, eye, injuries

INTRODUCTION

Eye injuries remain a major public health problem globally. In 1992, Thylefors^[1] reported that in developing countries, ocular trauma represents about 5% of blindness cases. Ocular injuries are not only more common in developing countries, but also more severe in their effects.^[2] Eye injuries are related to particular occupations or cultural environments, so the type and prognosis of injuries seen in developing countries are not similar to those in industrialized countries.^[2]

Address for correspondence:

Prof. Catherine U Ukponmwan,
Department of Ophthalmology, University of Benin
Teaching Hospital, PMB 1111, Benin City, Nigeria.
E-mail: kateukiz@aol.com

Access this article online

Quick Response Code:	Website: www.nigerianjsurg.com
	DOI: ***

Ocular trauma among children is considered a very serious public health concern as it is responsible for a high incidence of uni-ocular blindness and less commonly bilateral blindness.^[3-5] The accruing child blind years often subject the child to a poor quality of life, affect educational and lifelong learning and significantly reduce empowerment opportunities for the child even if he/she survives to adulthood. Uni-ocular blindness also has a psychological effect on the child, Penetrating ocular injuries in particular often cause severe damage resulting in loss of vision or eye and quite a number of reports emphasize the high occurrence and frequent severity of eye injuries in children.^[6-9]

A wide variety of objects have been identified as agents of ocular trauma causing penetrating eye injuries in children; these include sharp objects such as pencils, sticks, twigs, sharp edges of toys, missiles from pellets and stone, metal rods. Two cases of broomstick eye injury were seen in a 6-year review in Port Harcourt, Nigeria as a cause of penetrating eye injury.^[7] None was seen in an earlier review of perforating eye injuries in children in Benin City, Nigeria between 1997 and 2001.^[4] Few case reports of broomstick eye injury have been reported from Ghana and South Africa.^[10,11]

The broom is a common household implement in Africa, used for household chores such as sweeping, brushing of floors and even cooking in some cultures. It is made from a bundle of broomsticks obtained from the raffia palm. A piece of broomstick can accidentally penetrate the eye if the broom is not handled properly. Short pieces from individual broomsticks are also used as missiles by children who aim it at the eyes of others using a rubber band [acting as a catapult, Figure 1], thus

penetrating the eye and causing severe penetrating injury to the eye. It can also become a foreign body lodged within the eye from this process. The broom is very dirty because of its usage and thus acts as a reservoir for many germs such as bacteria and fungi, leading to fulminating infection of the eye.

There has been a recent increase in the number of cases of broomstick injury of the eye in children presenting at the University of Benin Teaching Hospital (UBTH) in Benin City. The aim of this study is to determine the frequency of occurrence, pattern of presentation and complications from broomstick eye injury with a view to proffering solutions on ways to reduce this trend.

MATERIALS AND METHODS

The records of all consecutive patients presenting to the ophthalmologist through the hospital Accident and Emergency unit and directly to the eye clinic with ocular trauma from broomstick injury between January 2003 and June 2014 were reviewed. A total of 20 cases were identified. Relevant information was retrieved and transferred into a questionnaire that formed the database for analysis.

Patient demographic characteristics, interval between occurrence of injury and presentation to eye facility, mechanism of injury, activity at time of injury, visual acuity at presentation, examination findings and diagnosis, complications, treatments offered and follow-up events were documented.

Ocular trauma from broomstick in this study was classified using the Birmingham Eye Trauma Terminology system (BETTS).^[12] BETTS broadly classifies ocular trauma into open globe and closed globe injury. Closed globe injuries are classified into lamellar and contusion injuries while open globe injuries are classified into laceration and rupture injuries. Lacerations are further sub-classified into penetrating, perforating and retained intraocular foreign body (IOFB).



Figure 1: Rubber band used for shooting broomstick

The children were treated promptly as emergencies using departmental protocols comprising of systemic, sub-conjunctival injections and topical antibiotics such as ceftazidime, ciprofloxacin, gentamicin and antifungals such as ketoconazole, fluconazole, itraconazole, topical cycloplegic agents such as atropine or homatropine and intra-vitreous antibiotic injections when indicated. Surgical repair of corneal wounds and removal of retained IOFB of broomstick were also carried out when indicated.

Data were analyzed using SPSS, IBM, Chicago, USA.

Ethics approval for this study was obtained from the UBTH Ethics Committee.

RESULTS

A total of 20 eyes in 20 patients were seen. Patients who presented with broomstick injuries in the period under review were all children, <14 years old. The mean age was 7.10 ± 4.03 years (standard deviation) with a range of 1-year 3 months to 14 years. Males were more affected than females at a ratio of 3:1 [Table 1].

Broomstick eye injury at UBTH was rare prior to 2008 with only 1 case recorded in 2003, there has been one case per year in consecutive years since 2008 with an upsurge in 2011 of 9 cases or 45% of the patients and 3 cases each in 2013 and 2014 at the time of review. Twelve children (60%) sustained trauma from broomstick shot as a missile with a rubber band and/or catapult sling [Figure 1], often by an older male child and/or sibling, during games or at play. Five children accidentally fell upon or into the broom, 2 of the children sustained the injury from beating (flogging) with a broom by their teacher and parent and 1 child got injured from poor handling of the broom at chores. Half of cases ($n = 10$) presented to the eye facility within 24 h of injury and a further 40% presented within 7 days, only 10% ($n = 2$) presented after 1-week [Figure 2].

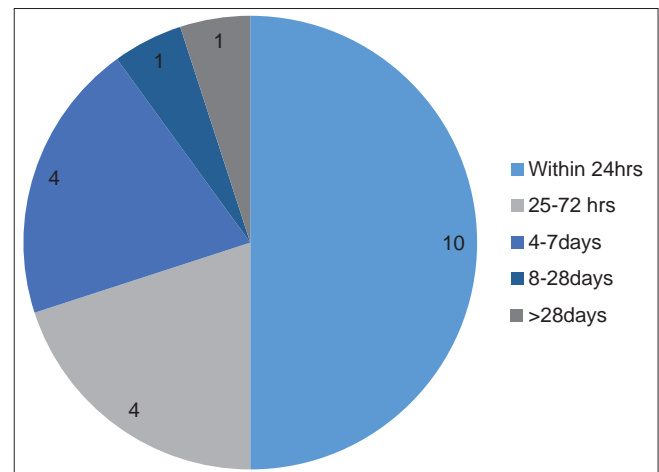


Figure 2: Interval between injury and presentation at eye facility

Ten (50%) of the children presented with no light perception (NLP) while another 30% ($m = 6$) were also blind with visual acuities ranging from counting fingers at 1 m to light perception. Vision could not be assessed in 3 of the children who were preverbal, and one of these was discharged against medical advice by the parents on 1st day of the presentation. Table 2 shows the visual acuities of the eyes at presentation and last follow-up visit to the eye clinic. The last follow-up visit ranged from 2 weeks to 10 months after presentation with a mean follow-up of 18 weeks.

Using the BETTS classification, 90% ($m = 18$) of the cases were open globe injuries ranging from penetrating (60%, $m = 12$), perforating (10%, $m = 2$) and retained intraocular foreign body of broomstick (20%, $m = 4$) injuries. Only 10% ($m = 2$) were closed (lamellar) injuries [Table 3].

Most of the children were admitted as emergencies through the accident and emergency unit of the hospital and all except one child who was discharged by the parents against medical advice, received a combination of two or more treatments which included topical, systemic and intra-vitreous injections of anti-microbials. Corneal repair with 9/0 nylon sutures and removal of intraocular foreign body was carried out as indicated for some of the children under general anaesthesia [Table 4].

Most of them had multiple complications such as corneal laceration (80%), traumatic cataract (40%), endophthalmitis and panophthalmitis affected 11 children (55%), and orbital cellulitis (15%). Other complications are shown in Table 5.

DISCUSSION

Broomstick ocular injury was more common in males than females and affected more children aged less than 10 years than older ones. These findings are similar to those of other studies in Nigeria and globally where males have been shown to be more prone to injuries as they are more daring, rough and playful.^[7,10,13] Young children often are more prone also because they are naïve and more vulnerable to being victims during rough games than older children who are stronger, wiser and able to protect themselves. Young children are less aware of the consequences of rough games and ocular trauma.

Half of the cases presented in hospital within 24 h, this proportion is higher than previous reports of ocular injuries from Nigeria and Ghana where there was delay in presentation of more than 24 h in up to 91% of cases.^[7,9,10,14] This may be an indication of the severity, pain, loss of vision and anxiety associated with the injury, especially as it involved young children and parents are likely to seek help immediately at such instances.

There was a report of 11 cases of broomstick ocular injury in 1-year from Ghana, but to our knowledge our case series represent the highest numbers (19 cases in 6.5 years, i.e., 2008–2014) documented in Nigeria, especially in 2011 when there were

9 cases and it contrasts with a much lower proportion reported from Port Harcourt of 2 cases in 6 years.^[7,10] This period (2011) coincided with an era of intense political campaigns and rallies for gubernatorial elections by a popular political party in the state that uses the broom as its party symbol. Party members and supporters were required to carry brooms at rallies and party events as a sign of solidarity and there were anecdotal reports of increased cost and scarcity of brooms initially, and thereafter, increased production to meet demand. This may have increased the exposure and risks to broomstick injury in the state during that period.

Table 1: Sex and age distribution of cases

Profile	Frequency	Percentage
Sex		
Male	15	75.0
Female	5	25.0
Age group (years)		
0-5 years	9	45.0
6-10 years	5	25.0
11-15 years	6	30.0
Total	20	100.0

Table 2: Visual acuity at presentation in the eye clinic and follow-up

Visual acuity (affected eye)	At presentation <i>n</i> (%)	At last follow-up visit <i>n</i> (%)
NLP	10 (50.0)	11 (55.0)
LP-HM	5 (25.0)	4 (20.0)
CF-3/60	1 (5.0)	1 (5.0)
>6/18	1 (5.0)	2 (10.0)
Not assessed	3 (15.0)	2 (10.0)
Total	20 (100.0)	20 (100.0)

NLP: No light perception, LP: Light perception, HM: Hand movement, CF: Count finger

Table 3: Type of injury from examination and diagnosis (BETTS)

Type of injury	Frequency ($n=20$) (%)
Open globe (laceration)	18 (90.0)
Closed globe (lamellar laceration)	2 (10.0)
Laceration injuries ($n=18$) (%)	
Penetrating	12 (66.7)
Perforating	2 (11.1)
Retained IOFB	4 (21.1)

BETTS: Birmingham Eye Trauma Terminology system; IOFB: Intraocular foreign body

Table 4: Treatment given

Treatment	Frequency ($n=20$)*	Percentage/cases
Topical antibiotics/ cycloplegics/antifungals	20	100.0
Systemic antibiotics	15	75.0
Intra-vitreous injections	8	40.0
Removal of retained IOFB (broomstick)	4	20.0
Corneal repair	4	20.0

IOFB: Intraocular foreign body *number of patients

Table 5: Complications of broomstick eye injury

	Frequency	Percentage/cases
Initial complication (anterior segment) (n=20)		
Corneal laceration/perforation	16	80.0
Traumatic cataract	8	40.0
Uveal prolapse	3	15.0
Hyphema	3	15.0
Stromal abscess/hypopyon	3	15.0
Lens subluxation	2	10.0
Initial complication (posterior segment) (n=18)		
Endophthalmitis	8	44.4
Panophthalmitis	3	16.7
Orbital cellulitis	3	16.7
Retinal detachment	2	11.1
Ocular hypotony	1	5.6
Vitreous hemorrhage	1	5.6
Complications at last follow-up visit (n=20)		
Corneal opacity	10	50.0
Cataract	6	30.0
Phthisis bulbi/enophthalmos	5	25.0
RD/choroidal detachment	4	20.0
Occlusio/seclusio pupillae	4	20.0
Staphyloma	1	5.0

The most common mechanism of injury was broomstick used as a missile with a catapult or rubber sling, during play or games. This could be as a result of deliberate mischief by the children and lack of awareness of the risks of both children and parents. The implication is that there is poor or no supervision of children in these settings, and this is likely due to the prevailing socioeconomic and cultural environment of these children.

Most injuries were open globe injuries from penetrating and retained IOFB, this is not surprising as the broomstick is a pointed sharp object that can easily penetrate a soft tissue such as the eye, especially when shot as a projectile.

Visual acuity at initial presentation was very poor with almost all cases blind. This is likely due to the severity of injuries and immediate complications which were mostly multiple and included devastating blinding complications such as endophthalmitis, panophthalmitis and orbital cellulitis. This is also not unexpected as the broom is a dirty household implement and reservoir of microorganisms such as bacteria and fungi. This finding of blinding complications is similar but higher than that reported from Ghana where 50% of cases developed monocular blindness.^[10]

Visual acuity did not improve at last follow-up, however, we cannot adequately compare with other studies because of the highly variable duration of follow-up we had and pending treatments such as cataract surgery that were not carried out in these patients, which was often due to patient-related factors such as cost and lack of motivation.

Early presentation of patients in this study to the facility did not appear to improve visual outcome and this is most probably an indication of the rapidly, fulminating nature of ocular infections such as endophthalmitis and severity of complications that included retinal detachment. The standardized protocol in our center for the management of ocular injuries including broomstick injury to the eye was applied in the management of these patients. This included intra-vitreous tap for microscopy, culture and sensitivity and intra-vitreous injections of appropriate antibiotics such as ceftazidime and vancomycin. Topical and systemic antifungal agents were also instituted. The poor visual outcome in the patients in this study despite the intensive management could be due to the poor initial visual acuity and the severity of the injury. The initial presenting visual acuity in 50% of the children presented was NLP, and another 30% had an initial visual acuity ranging from counting finger at 1 m to light perception. Lieb *ds* 'k.^[15] reported that the clinical features associated with good visual outcome in open globe injuries were better presenting visual acuity, culture of nonvirulent organism, lack of retinal detachment, absence of clinical endophthalmitis and shorter wound length. Another study from Southern Israel also found that the most important prognostic factors in open globe injury were the initial visual acuity, eyelid injury and retinal detachment.^[16]

Study limitations

This was a retrospective series and as such there was no documentation of adequately defined social, educational and economic parameters for these patients. This data may play an important role in understanding and explaining the findings observed.

A prospective study is recommended to address these issues.

CONCLUSION AND RECOMMENDATIONS

Broomstick shot as a projectile missile causes devastating and multiple ocular complications resulting in rapid and immediate loss of vision. Early presentation to the hospital does not appear to improve the prognosis for vision. Such injuries often affect younger, male children than older ones and are usually sustained during misguided play or games by children who are both victims and perpetrators.

Primary prevention offers the only hope for control and reduction of blindness occurring from such injuries. It is recommended that effective health education (HE) be used by eye health stakeholders to highlight these risks from brooms that are such common household implements. This HE should be focused on children in relevant fora such as religious (Sunday schools), educational (school clubs) and cultural meeting groups, to adequately disseminate this information. Parents and care givers should also be enlightened on these risks and the need for enhanced supervision of children especially at play. Loose pieces of broom should be

immediately picked up and discarded safely to prevent easy access by children and catapults games should be strongly discouraged. Governments and political groups should be enlightened about the possible implications of their activities and advised to sponsor messages in the media to raise awareness about these risks when necessary, to reduce the incidence of broomstick related injuries.

REFERENCES

- Thylefors B. Epidemiological patterns of ocular trauma. *Aust N Z J Ophthalmol* 1992;20:95-8.
- Négrel AD. Magnitude of eye injuries worldwide. *Community Eye Health J* 1997;10:49-53.
- Thylefors B, editor. Ocular trauma. In: *Strategies for Prevention of Blindness in National Programmes – A Primary Health Care Approach*. Geneva: World Health Organisation; 1997. p. 74-80.
- Otoibhi SC, Osahon AI. Perforating eye injuries in children in Benin City, Niger *J Biomed Sci* 2003;2:40-5.
- Lithander J, Al Kindi H, Tönjum AM. Loss of visual acuity due to eye injuries among 6292 school children in the Sultanate of Oman. *Acta Ophthalmol Scand* 1999;77:697-9.
- Osahon AI, Dawodu OA. Pattern of eye diseases in children in Benin City, Nigeria: A hospital-based study. *Trop Doct* 2002;32:158-9.
- Omobolanle AA, Henrietta N. Pattern of paediatric corneal laceration injuries in the University of Port Harcourt teaching hospital, Rivers state, Nigeria. *BMC Res Notes* 2012;5:683.
- Kyari F, Alhassan MB, Abiose A. Pattern and outcome of paediatric ocular trauma – A 3-year review at National Eye Centre, Kaduna. *Niger J Ophthalmol* 2000;8:11-6.
- Ashaye AO. Eye injuries in children and adolescents: A report of 205 cases. *J Natl Med Assoc* 2009;101:51-6.
- Essuman VA, Ntim-Amponsah CT. Preventing broomstick eye injuries in children in Accra. *Community Eye Health J* 2004;17:46.
- Grieshaber MC, Stegmann R. Penetrating eye injuries in South African children: Aetiology and visual outcome. *Eye (Lond)* 2006;20:789-95.
- Kuhn F, Morris R, Witherspoon CD. Birmingham Eye Trauma Terminology (BETT): Terminology and classification of mechanical eye injuries. *Ophthalmol Clin North Am* 2002;15:139-43, v.
- Onwasigwe EN, Umeh RE, Onwasigwe CN. Ocular injury in children. *Niger J Ophthalmol* 1994;2:9-17.
- Ukponmwan CU, Akpe AB. Aetiology and complications of ocular trauma. *Niger J Surg Sci* 2008;18:92-7.
- Lieb DF, Scott IU, Flynn HW Jr, Miller D, Feuer WJ. Open globe injuries with positive intraocular cultures: Factors influencing final visual acuity outcomes. *Ophthalmology* 2003;110:1560-6.
- Knyazer B, Bilenko N, Levy J, Lifshitz T, Belfair N, Klemperer I, *et al*. Open globe eye injury characteristics and prognostic factors in southern Israel: A retrospective epidemiologic review of 10 years experience. *Isr Med Assoc J* 2013;15:158-62.

How to cite this article: ????

Source of Support: Nil, Conflicts of Interest: None declared.