

# Spectrum of Diseases and Diagnostic Values of Ultrasound in Adult Patients with Nontraumatic Acute Abdomen in a Nigerian Tertiary Health Facility

Bimbo Ayoola Ashaolu, Mopelola Christianah Asaleye, Adebayo Victor Adetiloye, Isaac Olusegun Alatise<sup>1</sup>

Departments of Radiology and <sup>1</sup>Surgery, College of Health Sciences, Obafemi Awolowo University, Ile-Ife, Osun, Nigeria

## ABSTRACT

**Aim and Objective:** The purpose of this study was to determine the spectrum of disease on abdominal ultrasound (US) and the diagnostic efficacy of US in adult patients with nontraumatic acute abdomen at Obafemi Awolowo University Teaching Hospitals Complex (OAUTHC), Ile-Ife. **Materials and Methods:** The study population included consecutive 150 adult patients aged 15 years and above presenting with nontraumatic acute abdomen via the adult emergency unit or as inpatients referred to the Radiology Department of OAUTHC, Ile-Ife for abdominal US. MINDRAY D.C-6 real-time US scanner with 3.5, 5.0, and 7.5 MHz probes and Doppler facilities were used to assess the intra-abdominal organs and the findings were compared with the clinical and surgical findings in those cases that were operated. **Results:** The common spectrum of diseases encountered on US in this study included appendicitis (66 [44%]), ectopic pregnancy (34 [22%]), intestinal obstruction (13 [8.7%]) while the least finding was renal abscess 1 (0.7%). The correlation of US findings with surgical findings in this study showed sensitivity, specificity, and kappa agreement for appendicitis of 83.3%, 100.0%, and 0.808; ectopic pregnancy of 100.0%, 97.8%, and 0.958; acute cholecystitis of 100.0%, 100.0%, and 1.0. However, perforated viscus showed the least sensitivity (60.0%), specificity (99.2%), and kappa agreement 0.654. All the disease entities showed good kappa agreement beyond chance, and they were all statistically significant ( $P < 0.001$ ). **Conclusions:** This study has shown a relatively high sensitivity, specificity and diagnostic accuracy of US in cases of nontraumatic acute abdomen in a careful hand. We, therefore, recommended that these advantages of US should be capitalized upon in settings where other advanced diagnostic modalities are not available.

**KEYWORDS:** Accuracy, acute abdomen, Nigeria, spectrum, ultrasound

## INTRODUCTION

Acute abdomen is a term used to encompass a spectrum of surgical, medical and gynecological conditions, ranging from trivial to life-threatening conditions, which require hospital admission, investigations, and treatment.<sup>[1]</sup> It also refers to the clinical situation in which an acute change in the condition of the intra-abdominal organs, usually related to inflammation or infection, demands immediate and accurate diagnosis.<sup>[2]</sup>

### Address for correspondence:

Dr. CM Asaleye,  
Department of Radiology, Obafemi Awolowo  
University, P.O. Box 1001, Ile-Ife, Osun, Nigeria.  
E-mail: casaleye@yahoo.com

### Access this article online

<b>Quick Response Code:</b>	<b>Website:</b> www.nigerianjsurg.com
	<b>DOI:</b> *****

Acute abdominal pain is the most common physical complaint accounting for 5–10% of all emergency department visits as well as the leading cause of hospital admissions in the United States.<sup>[3,4]</sup> Acute abdomen has a sudden onset, can persist for several hours to days and is associated with a wide variety of clinical features which are specific to underlying condition or disease.<sup>[5]</sup> However, despite its frequent occurrence, it is sometimes difficult to manage because no matter how thorough the work-up is, specific diagnosis is not possible in 30% of cases.<sup>[6]</sup>

Conditions resulting in acute abdomen can cause serious complications or even death, especially if there is a delay in diagnosis and appropriate therapy, hence the necessity for early diagnosis. The causes are numerous, from the relatively trivial to immediately life-threatening ones and attempts to reach a diagnosis must sometimes be curtailed in the interest of immediate treatment.<sup>[7]</sup> The commonly observed conditions are appendicitis, intestinal obstruction, and gynecological pathologies, with acute appendicitis being the most commonly occurring abdominal acute condition in emergency departments.<sup>[8-10]</sup>

Of all the imaging procedures available for the evaluation of an acute nontraumatic abdomen, ultrasound scan (USS) appears to be the first line modality because it is easily available, cost-effective, portable, easily reproducible, noninvasive, requires minimal patient preparation and has no known side effects.<sup>[11,12]</sup> The issue of cost and availability become very important in

resource-poor setting where patients pay out of pocket for treatment received. Furthermore, USS offers a real-time dynamic examination, and this characteristic conveys dynamic information about bowel motility and changes in position as well as to depict blood flow.<sup>[13]</sup> This characteristic is very important in the evaluation of some causes of acute abdomen that may impair peristalsis, including small-bowel obstruction, ischemia, enteritis, and inflammatory processes like acute appendicitis.

Several studies have evaluated the diagnostic accuracy of abdominal USS in acute abdomen and have found high sensitivity and specificity.<sup>[13-17]</sup> It has also been shown to be better than clinical diagnosis in all ramification.<sup>[12-14]</sup> Unfortunately, most of the studies were done outside the shore of Nigeria. A Nigerian study with a similar objective showed low diagnostic accuracy of USS in acute appendicitis.<sup>[9]</sup> This may be due to the resolution of the USS facility that was used in the previous study. Hence, the need to re-evaluate the diagnostic accuracy of USS among Nigerian patients becomes very apparent. The purpose of this study was to identify by ultrasound (US) the spectrum of diseases in adults with nontraumatic acute abdomen at Obafemi Awolowo University Teaching Hospitals Complex (OAUTHC), Ile-Ife; and to correlate the US findings with the surgical findings with the aim to ascertain the diagnostic accuracy of abdominal US in the setting of acute abdomen.

## MATERIALS AND METHODS

### Study setting and design

This is a prospective cross-sectional study that was carried out at the Radiology Department of OAUTHC, Ile-Ife from June 2010 to May 2011.

### Study population

The study subjects were made up of consecutive 150 patients aged 15 years and above who were referred to the Radiology Department of OAUTHC with symptoms and signs of acute abdomen of nontraumatic origin. Patients who had previous surgery were excluded from the study.

### Study technique

They were sonographically evaluated with MINDRAY (USA Inc) real-time USS model DC-6 with Doppler facilities, probes with frequencies of 3.5, 5, and 7.5 MHZ with US acoustic gel. Normal abdominal protocol for scanning the abdomen including fasted state and distended urinary bladder was skipped because of the acute presentation of the cases. However, for equivocal cases modifications like instilling normal saline via urethral catheter was used to distend the urinary bladder which served as an acoustic window for USS and helped to displace the bowel loops from the area of interest especially when scanning for pelvic organs such as the uterus, vagina, adnexae, prostate gland, and rectum. Patients with right hypochondrial pain underwent a preliminary scan, when they could not comply with the fasting protocol which

was later repeated during fasting to confirm the finding. In equivocal cases, they were requested to come back for a repeat scan as soon as they were stabilized. Coupling gel was applied to the exposed abdomen from below the diaphragm to the symphysis pubis.

Most of the USS were performed by the first authors, and the scanning was done supine in both longitudinal and transverse planes. The longitudinal scan was done starting from the midline to the lateral margin, taking one side at a time, and moving at about 1 cm intervals. A transverse scan of the area of interest was also done, moving from midline to the lateral margin also taking one side at a time and moving at about 1 cm intervals.

Sonographic features indicating the following abnormalities were looked for: Inflammation and fluid collections. The inflammatory features identified were: Tenderness, reduction or increased in the echo pattern if it is acute or chronic, respectively, increase in organ or tissue size.<sup>[18]</sup> Collections were identified by their anechoic and/or mixed density characteristics. Vascular assessment with Doppler USS was done where necessary. In situations where measurements were required, such were taken thrice, and the average of the three measurements was taken in order to get the value as accurate as possible.

### Statistical analysis

The essential information was entered into the computer spreadsheet. The US findings were compared with surgical, medical and/or clinical findings where applicable. Statistical package for social sciences (SPSS) for windows version 16.0 (SPSS Inc.) was used to analyze the data using the appropriate descriptive and inferential statistical methods and displayed by means of varied statistical presentations. The degree of agreement of the various clinically related procedure tools in terms of a specific diagnosis was determined by the use of Kappa statistics, which indicated the degree of agreement beyond chance. The Kappa value could range from 0 to 1. Statistical significance was set at  $O < 0.05$ . Diagnostic performance markers were sensitivity, specificity, positive predictive value (PPV), negative predictive value, and diagnostic accuracy.

### Ethical consideration

Written informed consent was obtained from all the study subjects and approval for the study was obtained from the Hospital Ethical and Research Committee of the OAUTHC, Ile-Ife, Osun State.

## RESULTS

During the study period, 150 patients with nontraumatic acute abdomen were investigated. The ages of the patients ranged from 15 years to 73 years, with a mean age of  $32.5 \pm 13.8$  years. The age range of 20–29 years had the highest frequency of 51 (34.0%) patients. This was followed by 30–39 years which had a frequency of 35 (23.3%) patients. The lowest frequency was found in ages

70 years and above which had a frequency of 3 (2.0%) patients. The females had a frequency of 86 (57.3%) patients while the males had 64 (42.7%) patients [Table 1].

The most common clinical indication for US in this study was appendicitis, with a total of 72 (48%) patients. This was followed by ectopic pregnancy which had 27 (18%) patients. Renal abscess and hepatitis were the least common cause of acute abdomen necessitating investigations by US. In between these were some other causes of nontraumatic acute abdomen, [Figure 1].

Following ultrasonographic evaluation of the patients, acute appendicitis had the highest US diagnosis of nontraumatic acute abdomen with a frequency of 66 (44%) patients. The age ranges 20–29 years had the highest frequency of acute appendicitis, followed by age range 10–19 years, with the least frequency found in ages 70 and above. Appendicitis was the most common among men (41 [64.1%]) [Table 2a and b]. The ultrasonographic features of appendicitis which were later confirmed at surgery include probe tenderness, increased appendiceal wall thickness, decreased peristalsis, hyperechoic periappendiceal fat, fluid collections [Figure 2], and appendicolith with characteristic target sign on transverse scan [Figure 3]. Their respective frequency was 100%, 83.3%, 83.3%, 66.7%, 16.7%, and 13.9% [Figure 4].

**Table 1: Sex distribution by age**

Age (years)	Frequency (%)		
	Male	Female	Total
<20	15 (23.4)	10 (11.6)	25 (16.67)
21-30	19 (29.7)	32 (37.2)	51 (34.0)
31-40	13 (20.3)	22 (25.6)	35 (23.3)
41-50	7 (10.9)	11 (12.8)	18 (12.0)
51-60	6 (9.9)	4 (4.7)	10 (6.7)
61-70	3 (4.7)	5 (5.8)	8 (5.3)
≥70	1 (1.6)	2 (2.3)	3 (2.0)
Total	64 (100.0)	86 (100.0)	150 (100.0)

**Table 2a: Age distribution by US diagnosis**

USS diagnosis	Age group (years)							Total
	<20	21-30	31-40	41-50	51-60	61-70	≥70	
Appendicitis	15 (60.0)	21 (41.2)	13 (37.1)	9 (50.0)	4 (40.0)	3 (37.5)	1 (33.3)	66 (44.0)
Ectopic	1 (4.0)	16 (31.4)	13 (37.1)	4 (22.2)	0 (0.0)	0 (0.0)	0 (0.0)	34 (22.7)
PID	0 (0.0)	2 (3.9)	3 (8.6)	0 (0.0)	0 (0.0)	0 (0.0)	0 (0.0)	5 (3.3)
Perforated viscus	1 (4.0)	1 (1.96)	0 (0.0)	1 (5.6)	2 (20.0)	1 (12.5)	0 (0.0)	6 (4.0)
Intestinal obstruction	3 (12.0)	3 (5.9)	2 (5.7)	0 (0.0)	2 (20.0)	2 (25.0)	1 (33.3)	13 (8.7)
Ovarian lesion	2 (8.0)	1 (2.0)	1 (2.9)	1 (5.6)	0 (0.0)	0 (0.0)	0 (0.0)	5 (3.3)
Appendiceal mass	0 (0.0)	0 (0.0)	0 (0.0)	1 (5.6)	1 (10.0)	0 (0.0)	1 (33.3)	3 (2.0)
Renal abscess	0 (0.0)	0 (0.0)	1 (2.9)	0 (0.0)	0 (0.0)	0 (0.0)	0 (0.0)	1 (0.7)
Cholecystitis	0 (0.0)	2 (3.9)	1 (2.9)	0 (0.0)	1 (10.0)	2 (25.0)	0 (0.0)	6 (4.0)
Renal calculus	1 (4.0)	1 (2.0)	1 (2.9)	0 (0.0)	0 (0.0)	0 (0.0)	0 (0.0)	3 (2.0)
No remarkable finding	2 (8.0)	4 (7.9)	0 (0.0)	2 (11.2)	0 (0.0)	0 (0.0)	0 (0.0)	8 (5.3)
Total	25	51	35	18	10	8	3	150 (100.0)

USS: Ultrasound scan, PID: Pelvic inflammatory disease, US: Ultrasound

The next common US findings of nontraumatic acute abdomen were an ectopic pregnancy which had a frequency of 34 (22%) patients. The highest frequency of ectopic pregnancy was found among the age group 20–29 years, followed by the age group 30–39 years, the least incidence was found among the age group 10–19 years. Expectedly, no case of ectopic pregnancy above 50 years.

Intestinal obstruction was the next common cause of nontraumatic acute abdomen with the highest frequency found among the age groups (10–19) and (20–29) years with the least incidence also noted among the age group 70 years and above. Patients with no remarkable US findings had a frequency of 8 (5.3%) patients of which 6 (75.0%) were female. Renal abscess had the least frequency of 1 (0.7%) patient.

In all, definitive surgical diagnosis was made in 124 (82.7%) out of the 150 patients. The remaining 26 (17.3%) patients were managed conservatively. Outcome at surgery showed that appendicitis had the highest frequency with 72 (58.1%) patients, out of which 12 (17.0%) patients had a ruptured appendix. This was followed by ectopic pregnancy which had a frequency of 31 (25.0%) patients and was also noted to most common on the right side (68.0%). The frequencies and percentages of other causes of acute abdomen in this study are shown in Table 3a. Of the 72 patients who had appendectomy, 40 (62.5%) patients were males while 32 (37.2%) patients were females [Table 3b].

The correlation of US findings with surgical findings in this study showed high US diagnostic performance markers in most of the cases of nontraumatic acute abdomen, except in perforated viscus where a moderate sensitivity was noted. All the disease entities showed good kappa agreement beyond chance, and they were all statistically significant ( $O < 0.001$ ) [Table 4].

It was also noted that the clinical findings correlate favorably well with US findings in most of the cases of nontraumatic acute abdomen except in perforated viscus where the sensitivity and

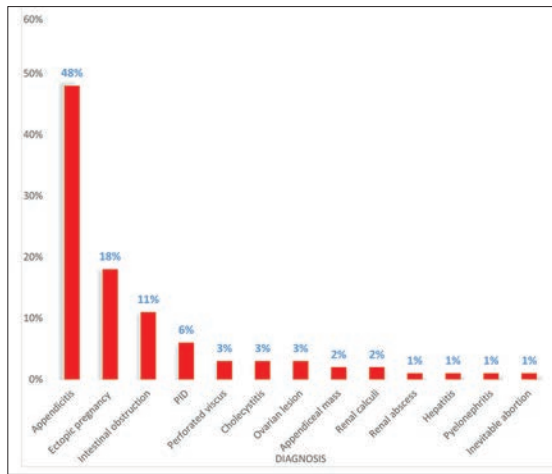


Figure 1: Indications for ultrasound of nontraumatic cases

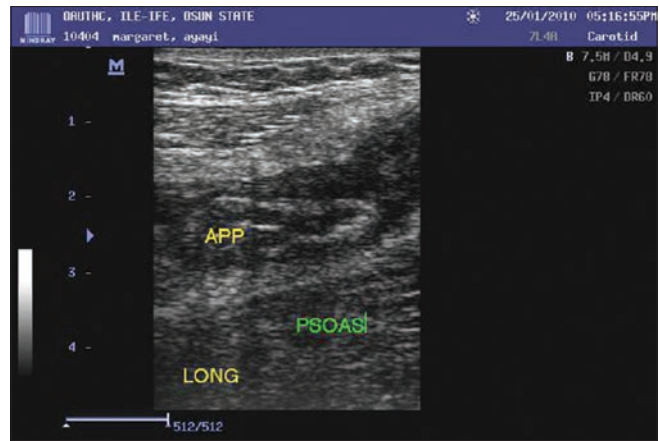


Figure 2: Longitudinal sonogram showing periappendiceal fluid collection in a ruptured appendix

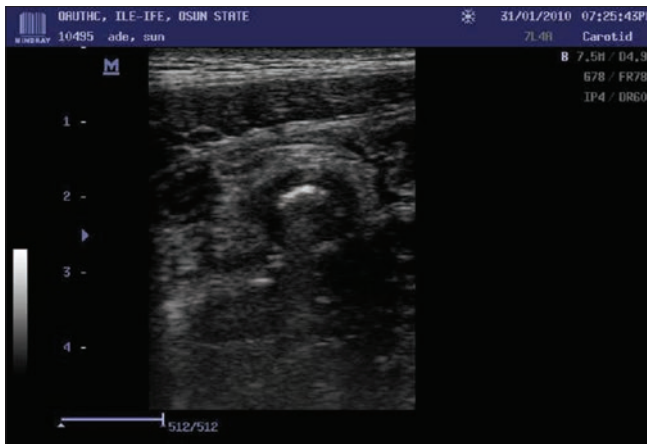

Figure 3: Transverse sonogram of an inflamed appendix with appendicolith showing a characteristic target sign

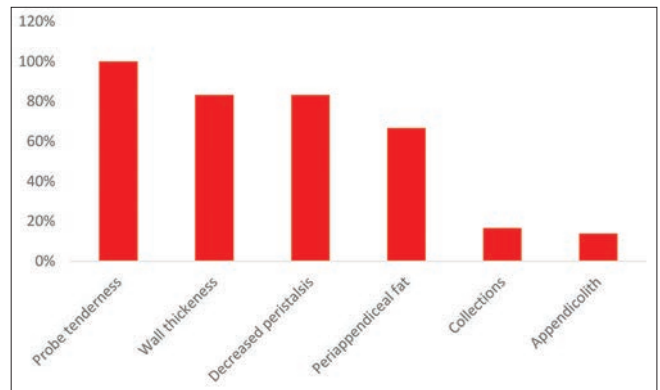


Figure 4: Frequency of ultrasound features of surgically diagnosed appendicitis

Table 2b: Sex distribution by US diagnosis

USS diagnosis	Sex		
	Male	Female	Total
Appendicitis	41 (64.1)	25 (29.1)	66 (44.0)
Ectopic	0 (0.0)	34 (39.5)	34 (22.7)
PID	0 (0.0)	5 (5.8)	5 (3.3)
Perforated viscus	4 (6.3)	2 (2.3)	6 (4.0)
Intestinal obstruction	8 (12.5)	5 (5.8)	13 (8.7)
Ovarian lesion	0 (0.0)	5 (5.8)	5 (3.3)
Appendiceal mass	2 (3.1)	1 (1.2)	3 (2.0)
Renal abscess	0 (0.0)	1 (1.2)	1 (0.7)
Cholecystitis	3 (4.7)	3 (3.49)	6 (4.0)
Renal calculus	3 (4.7)	0 (0.0)	3 (2.0)
Normal scan	2 (3.1)	6 (7.0)	8 (5.3)
Total	64	86	150 (100.0)

USS: Ultrasound scan, PID: Pelvic inflammatory disease, US: Ultrasound

PPV were low with a value of 33.3% and 40.0%, respectively. All the disease entity showed good kappa agreement beyond chance except in perforated viscus where it was noted to be fair. They were all statistically significant [Table 5].

## DISCUSSION

Acute abdomen in an emergency setup has become one of the most important and routinely encountered emergencies with patients presenting with a variety of symptoms. The patterns of disease have been found to vary according to the sociodemographic factors (sex and age), and in this study population the highest incidence of nontraumatic acute abdomen was found in patients within the age range of 20–29 years (34%). This was noted to be in concordance with findings of earlier workers, where the highest incidence of acute abdomen was found within the age range of 21–30 years (27.81%).<sup>[5]</sup> However, a contrasting finding was noted in the studies conducted in the western world where the incidence was found to be the highest in the age 45–60 years.<sup>[19]</sup> No obvious reason(s) can be adduced for this discrepancy, though geographical, racial, and dietary differences could probably be responsible.

There were more females than males in this study, which is in disagreement with the studies done by Prasad *et al.*,<sup>[11]</sup> and Memon *et al.*,<sup>[5]</sup> where more males were found probably due to the few cases of gynecological emergencies and exclusion of gynecological emergencies noted, respectively, in their studies. Acute appendicitis was the most common cause of acute abdomen in this study.



Table 3a: Age distribution by surgical diagnosis

Diagnosis	Age group (years)							Total
	<20	21-30	31-40	41-50	51-60	61-70	≥70	
Appendicitis	18 (72.0)	24 (47.1)	13 (37.1)	10 (55.6)	3 (30.0)	2 (25.0)	2 (66.7)	72 (48.0)
Ectopic	1 (4.0)	16 (31.4)	12 (34.3)	2 (11.1)	0 (0.0)	0 (0.0)	0 (0.0)	31 (20.7)
Perforated viscus	0 (0.0)	1 (2.0)	0 (0.0)	2 (11.1)	2 (20.0)	0 (0.0)	0 (0.0)	5 (3.3)
Intestinal obstruction	2 (8.0)	1 (2.0)	1 (2.9)	0 (0.0)	1 (10.0)	0 (0.0)	1 (33.3)	6 (4.0)
Ovarian lesion	0 (0.0)	2 (3.9)	1 (2.9)	1 (5.7)	0 (0.0)	0 (0.0)	0 (0.0)	4 (2.7)
Appendiceal mass	0 (0.0)	0 (0.0)	0 (0.0)	1 (5.7)	1 (10.0)	0 (0.0)	0 (0.0)	2 (1.3)
Renal abscess	0 (0.0)	0 (0.0)	1 (2.9)	0 (0.0)	0 (0.0)	0 (0.0)	0 (0.0)	1 (0.7)
Cholecystitis	0 (0.0)	0 (0.0)	1 (2.9)	0 (0.0)	0 (0.0)	1 (12.5)	0 (0.0)	2 (1.3)
No surgery	4 (16.0)	7 (13.7)	6 (15.0)	2 (11.1)	5 (62.5)	5 (62.5)	0 (0.0)	27 (18.0)
Total	25	51	35	18	10	8	3	150 (100.0)

Table 3b: Sex distribution by surgical diagnosis

Diagnosis	Sex		
	Male	Female	Total
Appendicitis	40 (62.5)	32 (37.2)	72 (48.0)
Ectopic	0 (0.0)	31 (36.1)	31 (20.7)
Perforated viscus	3 (4.7)	2 (2.3)	5 (3.3)
Intestinal obstruction	5 (7.8)	1 (1.2)	6 (4.0)
Ovarian lesion	0 (0.0)	4 (4.7)	4 (2.7)
Appendiceal mass	2 (3.1)	0 (0.0)	2 (1.3)
Renal abscess	0 (0.0)	1 (1.2)	1 (0.7)
Cholecystitis	2 (3.1)	0 (0.0)	2 (1.3)
No surgery	11 (17.2)	16 (18.6)	27 (18.0)
Total	64	86	150 (100.0)

This is consistent with findings from other studies carried out by Memon *ds*  $\mathcal{L}$ .<sup>[5]</sup> and Pintado-Garrido *ds*  $\mathcal{L}$ .<sup>[20]</sup> There were more males than females who presented with acute appendicitis which is in concordance with the study done by Memon *ds*  $\mathcal{L}$ .<sup>[5]</sup> Acute appendicitis was noted in this study to be common in 20–29 years age groups and less common in the elderly age group of 70 years and above which is in agreement with what was noted in the study done by Pintado-Garrido *ds*  $\mathcal{L}$ .<sup>[20]</sup> where it was frequently seen during the second and third decade of life and less frequently among the elderly.

The sensitivity and specificity of ultrasonography in diagnosing acute appendicitis in this study were 83.3% and 100.0%, respectively. Comparing this with a study done by Prasad *ds*  $\mathcal{L}$ ,<sup>[1]</sup> with sensitivity and specificity of 66.6% and 100%, the sensitivity of acute appendicitis was found to be very remarkable. However, in a study done by Pintado-Garrido *ds*  $\mathcal{L}$ ,<sup>[20]</sup> the sensitivity and specificity (83.7% and 97.4%) were almost similar to the values noted in this study. A contrasting diagnostic accuracy of diagnosing acute appendicitis was observed in the study done by Garba and Chom<sup>[17]</sup> Their diagnostic accuracy of acute appendicitis by US was 24.4% in contrast with 90.3% in this study. This could be attributed to observer error and possibly resolution of the US machine and probe. Low resolution US machine, inappropriate probes of suitable frequencies, and poor clinical history to guide the operator particularly in cases of self-referral by patients were noted in their study.<sup>[17]</sup> In this index study, however, most of the procedure were performed by the first author which help to reduce

observer error. Similarly, a high resolution US machine was utilized for the study. All together, these factors may be responsible for high diagnostic accuracy obtained in this study.

Ectopic pregnancy was the next common cause of nontraumatic acute abdomen diagnosed by US. Ectopic pregnancies were noted to be commoner on the right side which is similar to the trend all over the world.<sup>[21-23]</sup> This right-sided preponderance has been attributed to appendicitis.<sup>[23]</sup> It has been found that chronic inflammatory response from appendicitis can cause adhesions in the right iliac fossa leading to susceptibility to ectopic pregnancy. The age range of 20–29 years had the highest frequency of 16 (31.4%) patients with ectopic pregnancy, which was in keeping with the findings in the study done by Udigwe *ds*  $\mathcal{L}$ .<sup>[21]</sup> where their peak age group was 26–30 years and in the reproductive age groups. In this study, US had high sensitivity (100%), specificity (97.8%) and was of high diagnostic accuracy in detecting ectopic pregnancy. This was in high agreement with the study done by Prasad *ds*  $\mathcal{L}$ .<sup>[1]</sup> Valenzano *ds*  $\mathcal{L}$ ,<sup>[24]</sup> gave a discordant findings to the findings of this index study. They reported low sensitivity of transabdominal ultrasonography for ectopic pregnancy and subsequently recommended transvaginal ultrasonography when ectopic pregnancy is suspected.

Intestinal obstruction was the third common cause of nontraumatic acute abdomen in this study diagnosed by US. Of the thirteen patients sonographically diagnosed to have intestinal obstruction, 6 patients were confirmed by surgery while 4 were managed conservatively. The remaining 3 patients who had sonographic features of intestinal obstruction were confirmed at surgery to be cases of a ruptured appendix in two and one case of perforated posterior wall of the uterus, respectively. The sensitivity and specificity of US in detecting intestinal obstruction is high, 100% and 97.5%, respectively. In recent years, intestinal sonography has gained in acceptance for assessment bowel obstruction owing to technologically advanced equipment that improved resolution capability with good cross-sectional imaging of the gut wall and display of the transmural aspects of inflammation. In addition, the possibility of assessing intestinal morphology and motility during real-time US observation with no discomfort for the patient makes it a suitable diagnostic procedure in the case of an acute setting such as intestinal obstruction.<sup>[9]</sup> Similar to the findings of this study previous

**Table 4: Correlation of US diagnosis with surgical findings**

Variable	Surgical findings (%)									
	US diagnosis	Appendicitis	Ectopic	PID	Perforated viscus	Intestinal obstruction	Ovarian lesion	Appendiceal mass	Renal mass	Cholecystitis
Accuracy		90.3	98.4	99.2	97.6	97.6	98.4	99.2	100.0	100.00
PPV		100.0	94.0	50.0	75.0	66.7	75.0	66.7	100.0	100.0
NPV		81.3	100.0	100.0	98.3	100.0	99.2	100.0	100.0	100.0
Sensitivity		83.3	100.0	100.0	60.0	100.0	75.0	100.0	100.0	100.0
Specificity		100.0	97.8	99.1	99.2	97.5	99.2	99.2	100.0	100.0
Agreement		k=0.808 P<0.001	k=0.958 P<0.001	k=0.663 P<0.001	k=0.654 P<0.001	k=0.788 P<0.001	k=0.742 P<0.001	k=0.796 P<0.001	k=1.000 P<0.001	k=1.000 P<0.001

PID: Pelvic inflammatory disease, NPV: Negative predictive value, PPV: Positive predictive value, US: Ultrasound

**Table 5: Correlation of clinical diagnosis with US diagnosis**

Variable	US diagnosis (%)										
	Clinical diagnosis	Appendicitis	Ectopic	PID	Perforated viscus	Intestinal obstruction	Ovarian mass	Appendiceal mass	Renal mass	Cholecystitis	Renal calculus
Accuracy		90.4	94.0	98.0	95.3	95.3	98.6	98.6	100.0	99.3	100.0
PPV		86.1	96.3	62.5	40.0	68.8	80.0	66.7	100.0	100.0	100.0
NPV		94.9	93.5	100.0	97.2	98.5	99.3	99.3	100.0	99.3	100.0
Sensitivity		94.0	76.5	100.0	33.3	84.6	80.0	66.7	100.0	83.3	100.0
Specificity		88.1	99.1	97.9	97.9	96.4	99.3	99.3	100.0	100.0	100.0
Agreement		k=0.812 P<0.001	k=0.815 P<0.001	k=0.759 P<0.001	k=0.34 P<0.001	k=0.733 P<0.001	k=0.793 P<0.001	k=0.660 P<0.001	k=1.000 P<0.001	k=0.906 P<0.001	k=1.000 P<0.001

PID: Pelvic inflammatory disease, NPV: negative predictive value, PPV: Positive predictive value, US: Ultrasound

report had recorded high diagnostic accuracy for transabdominal ultrasonography in patients with intestinal obstruction.<sup>[25]</sup>

Sonographic findings of acute cholecystitis in this study were in concordance with several other literature findings. The sensitivity, specificity, and diagnostic accuracy were 100%, respectively. However, a comparative study done by Bree<sup>[26]</sup> showed lower values of 93%, 53% and 68% respectively in the above-mentioned diagnostic markers. This was adduced to the inability of ultrasonography to differentiate between acute cholecystitis and the incidental finding of gallstones in patients with another cause of right hypochondrial pain.<sup>[26]</sup>

The US findings of cases of pelvic inflammatory disease (PID) are nonspecific as the appearance can be a differential diagnosis in some acute abdominal conditions like postabortal sepsis. This was the finding in the study done by Adetiloye and Dare.<sup>[27]</sup> Other acute abdominal conditions such as ectopic pregnancy and perforated viscus can give similar sonographic findings of PID. In this study, PID was diagnosed based on the clinical details, sonographic findings, and subsequent response to management.

The US findings of renal calculus documented in this study were similar to the previous report.<sup>[28]</sup> US also helps to rule out other possible differentials such as abdominal aortic aneurysm or cholelithiasis which can be clinically mistaken for acute renal colic. In detecting renal calculi, US had a high sensitivity and specificity of 100% each. A comparative study done by Malik and Zakar<sup>[28]</sup> showed a lower sensitivity and specificity, 80% and 98%, respectively, though no obvious reason could be adduced for these findings.

The sonographic appearance of renal abscess seen as a cause of acute abdomen was a well-defined cortical cystic lesion with low level internal echoes although other sonographic features such as poorly defined, complex cystic mass, with internal echogenic fluid may also be present.<sup>[29]</sup> The diagnosis of acute pyelonephritis is usually based on clinical and laboratory findings and imaging is primarily to detect complications. However, renal US is commonly normal in uncomplicated acute pyelonephritis.<sup>[30]</sup> This was in agreement with the two cases seen in this study. Except for the marked probe tenderness in the renal angle, the sonographic findings were normal. These patients were managed conservatively, responded to treatment and subsequently discharged home.

We found least performance of US in perforated viscus in this study. Perforated viscus often results in massive intraperitoneal free air. Intraperitoneal free air in turn lead to scattering of the US waves at the interface of soft tissue and air which is accompanied by reverberation of the waves between the transducer and the air.<sup>[31]</sup> This, typically, results in a high-amplitude linear echo (increased echogenicity of a peritoneal stripe) accompanied by posterior artifactual reverberation echoes with characteristic comet-tail appearance. This may explain why diagnostic accuracy of US could be low. Maneuvers that can help improve US sensitivity in perforated viscus include positional change and the use of linear-array transducers.<sup>[31,32]</sup>

Despite the impressive findings recorded in this index study, it has some inherent defects which will affect the interpretation of the results. This includes the fact that it is a single center report. Histopathology reports, as well as the follow-up data, were

not recorded for any the patient. Similarly, no ideal abdominal preparations were recommended to patient because of the acuteness of the clinical conditions. This was seen in some conditions where excessive intraluminal gas caused poor visibility of organs. Marked probe tenderness over the diseased organ was a great challenge in compressing the surrounding bowel loops particularly in acute appendicitis. It was also noted that in obese patients, the appendix was poorly visualized due to the excessive intra-abdominal fat. We suggest a multicenter study to validate the finding of this study. Nevertheless, this study showed the role of US in the management of nontraumatic acute abdomen in adult patients. The results found in this study have shown a relatively high sensitivity, specificity, and diagnostic accuracy of US in cases of nontraumatic acute abdomen.

## CONCLUSION

This study group of patients with nontraumatic acute abdomen requiring prompt diagnosis, ultrasonography is an outstanding imaging modality which has helped the managing physicians and surgeons in arriving at early diagnosis. It has also been shown in this study to have high sensitivity, specificity, and diagnostic accuracy. We recommend that ultrasonography should be the first investigation of choice for patients with nontraumatic acute abdomen.

## REFERENCES

- Prasad H, Rodrigues G, Shenoy R. Role of ultrasonography in nontraumatic acute abdomen. *Int J Radiol* 2007;5:2-7.
- Kauffman GL. Acute abdomen In: Corson JD, Williamsons RC, editors. *Surgery*. 1<sup>st</sup> ed. Spain: Mosby International Limited; 2001. p. 1-14.
- White MJ, Council FL. Trouble shooting acute abdominal pain. *Emerg Med* 2002;34:34-42.
- Martin RF, Rossi RL. The acute abdomen. An overview and algorithms. *Surg Clin North Am* 1997;77:1227-43.
- Memon AA, Bhutto AA, Shaikh SG, Jokhio A, Soomro Q. Spectrum of diseases in patients with non-traumatic acute abdomen. *J Liaquat Univ Med Health Sci* 2008;7:180-3.
- Powers RD, Guertler AT. Abdominal pain in the ED: Stability and change over 20 years. *Am J Emerg Med* 1995;13:301-3.
- Cope Z. The Principles of diagnosis in acute abdominal disease In: Cope's Early Diagnosis of the Acute Abdomen. 19<sup>th</sup> ed. New York: Oxford University Press; 1996. p. 3-18.
- Asif M, Almas D, Hashmi JS. Acute abdomen; causes. *Prof Med J* 2008;15:120-4.
- Makanjuola D. The value of ultrasonography in the x-ray negative non-traumatic acute abdomen. *West Afr J Med* 1998;17:75-80.
- Birnbaum BA, Wilson SR. Appendicitis at the millennium. *Radiology* 2000;215:337-48.
- Kessler N, Cyteval C, Gallix B, Lesnik A, Blayac PM, Pujol J, et al. Appendicitis: Evaluation of sensitivity, specificity, and predictive values of US, Doppler US, and laboratory findings. *Radiology* 2004;230:472-8.
- Puylaert JB. Ultrasonography of the acute abdomen: Gastrointestinal conditions. *Radiol Clin North Am* 2003;41:1227-42, vii.
- Mazzei MA, Guerrini S, Cioffi Squitieri N, Cagini L, Macarini L, Coppolino F, et al. The role of US examination in the management of acute abdomen. *Crit Ultrasound J* 2013;5 Suppl 1:S6.
- Dhillon S, Halligan S, Goh V, Matravers P, Chambers A, Remedios D. The therapeutic impact of abdominal ultrasound in patients with acute abdominal symptoms. *Clin Radiol* 2002;57:268-71.
- McGrath FP, Keeling F. The role of early sonography in the management of the acute abdomen. *Clin Radiol* 1991;44:172-4.
- Nural MS, Ceyhan M, Baydin A, Genc S, Bayrak IK, Elmali M. The role of ultrasonography in the diagnosis and management of non-traumatic acute abdominal pain. *Intern Emerg Med* 2008;3:349-54.
- Garba ES, Chom ND. Ultrasound in the diagnosis of appendicitis: A plea for caution. *Niger J Surg Res* 2006;8:132-4.
- Stavros AT, Rapp CL, Thickman D. Sonography of inflammatory conditions. *Ultrasound Q* 1995;13:1-26.
- Svanes C, Salvesen H, Espehaug B, Søreide O, Svanes K. A multifactorial analysis of factors related to lethality after treatment of perforated gastroduodenal ulcer 1935-1985. *Ann Surg* 1989;209:418-23.
- Pintado-Garrido R, Moyadelacalle M, Sanchez-Ramon S, Castro Villamor MA, Plaza Lomos S, Mendo Gonzalez M. Indication and usefulness of ultrasonography for suspected acute appendicitis at the emergency department. *Emergencias* 2008;20:81-6.
- Udigwe GO, Umeononihu OS, Mbachi II. Ectopic pregnancy: A 5 year review of cases at Nnamdi Azikiwe University Teaching Hospital (NAUTH) Nnewi. *Niger Med J* 2010;51:160-3.
- Gharoro EP, Igbafe AA. Ectopic pregnancy revisited in Benin City, Nigeria: Analysis of 152 cases. *Acta Obstet Gynecol Scand* 2002;81:1139-43.
- Nordenskjöld F, Ahlgren M. Risk factors in ectopic pregnancy. Results of a population-based case-control study. *Acta Obstet Gynecol Scand* 1991;70:575-9.
- Valenzano M, Anserini P, Remorgida V, Brasca A, Centonze A, Costantini S. Transabdominal and transvaginal ultrasonographic diagnosis of ectopic pregnancy: Clinical implications. *Gynecol Obstet Invest* 1991;31:8-11.
- Kohn A, Cerro P, Milite G, De Angelis E, Prantera C. Prospective evaluation of transabdominal bowel sonography in the diagnosis of intestinal obstruction in Crohn's disease: Comparison with plain abdominal film and small bowel enteroclysis. *Inflamm Bowel Dis* 1999;5:153-7.
- Bree RL. Further observations on the usefulness of the sonographic Murphy sign in the evaluation of suspected acute cholecystitis. *J Clin Ultrasound* 1995;23:169-72.
- Adetiloye VA, Dare FO. Sonographic evaluation of induced abortion - Experience in Nigeria. *Afr J Med Med Sci* 1998;27:155-9.
- Malik T, Zakar A. Ultrasonography; Diagnostic role of in acute abdomen (non gynaecological causes). *Prof Med J* 2008;15:26-32.
- House MK, Gibson RN. Ultrasound diagnostic capabilities in native kidney disease. *Saudi J Kidney Dis Transpl* 2004;15:251-6.
- Brant WE. *The Core Curriculum Ultrasound*. 2<sup>nd</sup> ed. Philadelphia: Lippincott Williams and Wilkins; 2001. p. 130.
- Hefny AF, Abu-Zidan FM. Sonographic diagnosis of intraperitoneal free air. *J Emerg Trauma Shock* 2011;4:511-3.
- Chadha D, Kedar RP, Malde HM. Sonographic detection of pneumoperitoneum: An experimental and clinical study. *Australas Radiol* 1993;37:182-5.

How to cite this article: ????

Source of Support: Nil, Conflicts of Interest: None declared.