

## **Kolaviron, a biflavonoid complex from *Garcinia kola* seeds, ameliorates ethanol-induced reproductive toxicity in male wistar rats**

**\* Oluwatosin A. Adaramoye and Muritala Arisekola**

*Drug Metabolism and Toxicology Research Laboratories, Department of Biochemistry,, College of Medicine, University of Ibadan, Ibadan Nigeria.*

**Summary:** In previous studies, we established that kolaviron (KV) (a biflavonoid from *Garcinia kola* seeds) elicited anti-oxidative and hepatoprotective effects in Wistar rats chronically treated with ethanol. The present study investigates the possible ameliorative effect of KV against ethanol-induced reproductive toxicity in male Wistar rats. Twenty-eight rats were randomly divided into four groups of seven animals each; Group 1 (control) was administered corn oil, group 2 was given 45% v/v ethanol at 3g/kg body weight, group 3 received ethanol and KV (200mg/kg) simultaneously and group 4 received KV alone. All drugs were given daily by oral gavage for 21 consecutive days. Ethanol treatment resulted in a significant ( $p < 0.05$ ) decrease in relative weight of testis of the animals. In the spermatozoa, ethanol intoxication resulted in 54%, 21% and 38% decreases in testicular protein content, sperm motility and count, respectively. In addition, ethanol administration enhanced lipid peroxidation (LPO) process assessed by the accumulation of malondialdehyde (MDA) in the testis. Precisely, MDA level was increased by 121% in the testis of ethanol-treated rats relative to the control. Furthermore, levels of testicular glutathione and activities of testicular antioxidant enzymes such as superoxide dismutase and catalase were significantly ( $p < 0.05$ ) reduced in ethanol-treated rats. Histopathology showed extensive degenerative changes in seminiferous tubules and defoliation of spermatocytes in testis of ethanol-treated rats. Interestingly, co-administration of KV with ethanol led to almost complete inhibition of testicular LPO thereby enhancing antioxidant status of the testis. Overall, KV ameliorates ethanol-induced toxic assault on testis and improves seminal qualities of the rats.

**Keywords:** Kolaviron, Testis, Ethanol, Reproduction, Toxicity

©Physiological Society of Nigeria

\*Address for correspondence: [aoadaramoye@yahoo.com](mailto:aoadaramoye@yahoo.com) Phone: 234-808-838-2846; Fax: 234-2-810-3043

Manuscript Accepted: January, 2013

### **INTRODUCTION**

Ethanol is among the most widely abused drug, which can suppress reproductive function and sexual behaviour (Fadem, 1993). Ethanol is a testicular toxin and causes fertility abnormalities with low sperm count and impaired sperm motility in men (Maneesh *et al.*, 2006). Alcohol abuse may lead to testicular atrophy, feminization, and infertility in alcoholic men (Van Thiel *et al.*, 1980). Infertility is a major problem in up to 15% of the sexually active population and male factor is responsible in 50% of these cases (WHO, 1999). Chronic exposure to alcohol may result in pathophysiologic changes in cellular function caused by alcohol itself or the effects of its metabolites like acetaldehyde (Martinez *et al.*, 2009). In addition, ethanol exposure adversely affects the secretory function of Sertoli cells (Zhu *et al.*, 1997), disrupts the blood-testes barrier (Farghali *et al.*, 1991), enhances testicular malondialdehyde and reduces testicular glutathione levels (Rosenblum *et al.*, 1985). Also, ethanol exposure inhibits the

development of maturing germ cells or enhances their degeneration and promotes apoptosis of testicular germ cells (Zhu *et al.*, 2000).

Recently, there has been an upsurge of interest in the therapeutic potentials of medicinal plants as antioxidants in alleviating oxidative stress-induced pathologies (Lans *et al.*, 2007; Lee *et al.*, 2007). Medicinal plants with their active components are particularly attractive since they exhibit various pharmacological properties. Kolaviron (KV) (Figure 1) is a biflavonoid complex isolated from the seeds of *Garcinia kola*. This seed is eaten raw by Southern Nigerians with the belief that it promotes longevity. Extracts of the plant are used in traditional African medicine for the treatment of laryngitis, cough and liver diseases (Iwu and Igboko, 1982). Experimentally, KV has been reported to prevent hepatotoxicity mediated by several toxins (Adaramoye and Adeyemi, 2006a). KV is known to exhibit hypoglycemic effects in normal, alloxan and streptozotocin-diabetic animals (Iwu *et al.*, 1990; Adaramoye and Adeyemi, 2006b). KV also elicits

strong antioxidant activity in *in vivo* and *in vitro* models (Adaramoye *et al.*, 2005). We showed that KV ameliorated male reproductive toxicity in rats subjected to sub-lethal dose of gamma radiation (Adaramoye *et al.*, 2010), thus providing a background to explore the possible ameliorative effects of this biflavonoid complex in testis of rats chronically dosed with ethanol.

## MATERIALS AND METHODS

**Chemicals.** Glutathione, hydrogen peroxide, 5,5'-dithio-bis-2-nitrobenzoic acid (DTNB) and epinephrine were purchased from Sigma Chemical Co., Saint Louis, MO USA. Absolute ethanol, trichloroacetic acid (TCA) and thiobarbituric acid (TBA) were purchased from British Drug House (BDH) Chemical Ltd., Poole, UK. Other chemicals were of analytical grade and purest quality available.

### Plant material and extraction

*Garcinia kola* seeds (*Guttiferae heckel*) seeds were purchased from a local vendor in Ibadan, Nigeria. Kolaviron was extracted from the fresh seeds of the Kola (3.5 kg) and characterized according to the method of Iwu *et al.*, (1990), briefly, powdered seeds were extracted with light petroleum ether (b.p. 40–60°C) in a soxhlet extractor for 24 hr. The defatted, dried marc was repacked and then extracted with methanol. The extract was concentrated and diluted to twice its volume with distilled water and extracted with ethyl acetate (6.250 litres). The concentrated ethyl acetate fraction gave a yellow solid known as kolaviron (Figure 1). The purity and identity of kolaviron was determined by subjecting it to thin-layer chromatography (TLC) using Silica gel GF 254-coated plates and, solvent mixture of methanol and chloroform in a ratio 1:4 v/v. The separation revealed the presence of three bands which were viewed under UV light at a wavelength of 254 nm with RF values of 0.48, 0.71 and 0.76 (Adaramoye *et al.*, 2005). The yield of the preparation was 6%.

**Animals.** Inbred old male Wistar rats weighing between 180 and 200g were purchased from the animal house of the Department of Veterinary Physiology, Biochemistry and Pharmacology, University of Ibadan, Nigeria. Animals were kept in ventilated cages at room temperature (28-30°C) and maintained on laboratory chow (Ladokun Feeds, Ibadan, Nigeria) and water *ad libitum*. Rats handling and treatments conform to guidelines of the National Institute of Health (NIH publication 85-23, 1985) for laboratory animal care and use.

**Study Design.** Twenty-eight male albino rats (Wistar strain) were randomly distributed into four groups of seven animals each. Animals were given a period of two weeks for acclimatization before the experiment. The first group served as the control and was given

corn oil (Vehicle for drugs). The second group received 45%<sup>v/v</sup> ethanol at 3g/kg body weight (Adaramoye *et al.*, 2009), third group received ethanol and kolaviron (KV) simultaneously, while the fourth group received KV alone. KV was given at a dose of 200 mg/ kg body weight to the animals (Adaramoye *et al.*, 2009). KV was prepared with corn oil, and absolute ethanol (90%) was diluted with distilled water to 45%. Drugs were given daily by oral gavage for twenty-one consecutive days.

**Preparation of tissues.** Rats were sacrificed 24 hours after the last dose of drugs and, an overnight fast by cervical decapitation. Testes were quickly removed and washed in ice-cold 1.15% KCl solution, dried and weighed. Whole right side testes were fixed in Bouin's solution and used for histopathological analysis. Other testes were homogenized in 4 volumes of 50mM phosphate buffer, pH 7.4 and centrifuged at 10,000 g for 15 minutes to obtain post-mitochondrial supernatant fraction (PMF). The samples were stored at – 80°C until used.

**Preparation of Serum.** Blood was collected from the heart of the animals into plain centrifuge tubes and was allowed to stand for 1 hour. Serum was prepared by centrifugation at 3,000 g for 15 minutes in a Beckman bench centrifuge. The clear supernatant was used for the estimation of serum enzymes activities.

**Biochemical assays.** Protein levels in the samples were assayed by the method of Lowry *et al.*, (1951) using bovine serum albumin as standard. The estimation of serum alkaline phosphatase (ALP) activity was based on the method of Williamson (1972). ALP activity was measured spectrophotometrically by monitoring the concentration of phenol formed when ALP reacts with disodium phenyl phosphate at 680 nm. The activity of serum lactate dehydrogenase (LDH) was determined by the method of Zimmerman and Weinstein (1956). Reduced glutathione (GSH) level was determined at 412 nm using the method described by Jollow *et al.*, (1974). Testicular lipid peroxidation levels were assayed by the reaction between 2-thiobarbituric acid (TBA) and malondialdehyde (MDA), an end product of lipid peroxides as described by Buege and Aust (1978). Superoxide dismutase (SOD) activity was measured by the nitro blue tetrazolium (NBT) reduction method of McCord and Fridovich (1969). Catalase (CAT) activity was assayed spectrophotometrically by measuring the rate of decomposition of hydrogen peroxide at 240 nm as described by Aebi (1974).

**Sperm analysis.** Sperm motility was assessed by methods described by Zemjanis (1970) and Rezvanfar *et al.*, (2008). Epididymal sperm count was determined by the method described by Pant and Srivastava (2003). Total sperm abnormalities (TSA)

assay was determined according to the method described by Wells and Awa (1970).

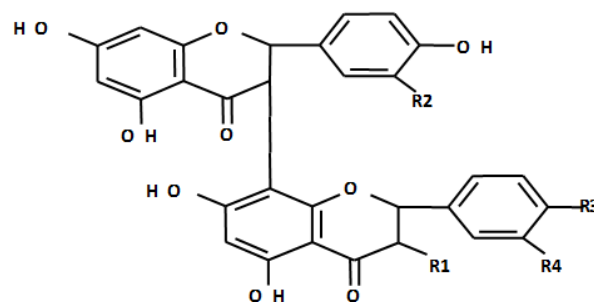
**Histopathology of tissues.** Testes were fixed in Bouin's solution and dehydrated in 95% ethanol and then cleared in xylene before embedded in paraffin. Micro sections (about 4 μm) were prepared and stained with haematoxylin and eosin (H&E) dye, and were examined under a light microscope by a Histopathologist who was ignorant of the treatment groups.

**Statistical analysis.** All values were expressed as the mean ± S.D. of seven animals per group. Data were analyzed using one-way ANOVA followed by the *post-hoc* Duncan multiple range test for analysis of biochemical data using SPSS (10.0). Values were considered statistically significant at  $p < 0.05$ .

**RESULTS**

In table 1, administration of ethanol for 21 consecutive days did not affect the body weight-gain of the rats. However, ethanol-intoxication caused significant ( $p < 0.05$ ) decrease in relative weight of testis of treated rats when compared to the control. The result presented in table 2 shows significant ( $p < 0.05$ ) decrease in the levels of testicular protein, reduced glutathione (GSH), sperm motility and count of ethanol-treated rats relative to controls. Precisely, ethanol administration decreased the levels of testicular protein, GSH, sperm motility and count by 54%, 69%, 21% and 38%, respectively. However, supplementation with kolaviron (KV) restored the relative testicular weight, protein content and sperm parameters towards normalcy. There were no significant ( $p > 0.05$ ) differences in the total sperm

abnormalities (TSA), live/ dead ratio of spermatozoa and, serum alkaline phosphatase and lactate dehydrogenase activities of the ethanol-treated rats relative to controls (Table 2 and figure 2). Figure 3 depicts that ethanol-intoxication caused marked elevation of testicular lipid peroxidation (LPO) as assessed by the accumulation of malondialdehyde (MDA) in the testis of the rats. Precisely, MDA level was elevated by 121% in ethanol-treated rats relative to controls. The enhanced MDA level was significantly ( $p < 0.05$ ) ameliorated in rats co-treated with KV. Ethanol administration caused a marked and significant decrease ( $p < 0.05$ ) in the levels of testicular superoxide dismutase (SOD) and catalase (CAT) by 56% and 38%, respectively when



	R1	R2	R3	R4
GB1	OH	H	OH	H
GB2	OH	H	OH	OH
Kolavlanone	OH	H	OMe	OH

**Figure 1.** Structure of Kolaviron

**Table 1.** Effect of kolaviron, biflavonoid from *Garcinia kola* seeds, on the body weight and relative weight of testis of rats treated with ethanol for 21 consecutive days

Grouping	Initial Body wt (g)	Final Body wt (g)	Weight gain (g)	Testicular wt (g)	Relative testicular wt
Control	178.2±7.3	207.4±5.3	29.2±3.5	2.9±0.2	1.4±0.05
ETOH	180.3±9.5	210.1±6.5	29.8±3.9	2.1±0.3	1.0±0.06*
ETOH + KV	174.0±8.0	202.7±5.3	28.7±3.9	3.0±0.2	1.5±0.08
KV	183.0±5.6	210.5±3.7	27.5±4.1	2.9±0.1	1.4±0.06

Values are the means ± S.D. of seven rats in each group. \* Significantly different from the control ( $p < 0.05$ )

ETOH= Ethanol, KV= Kolaviron

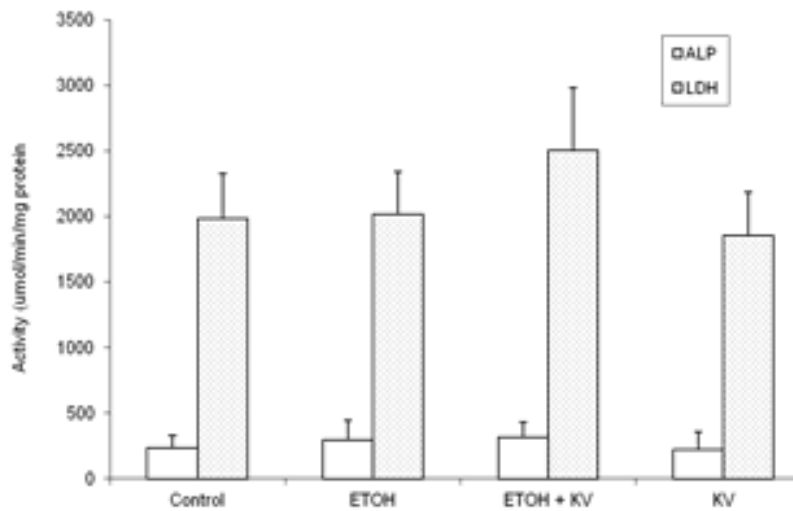
**Table 2.** Effect of kolaviron, a biflavonoid from *Garcinia kola* seeds, on testicular protein contents, glutathione (GSH) and seminal parameters of Wistar rats treated with ethanol for 21 consecutive days.

Variables	Control	ETOH	ETOH+KV	KV
TPC (mg/ g tissue)	0.28 ± 0.05	0.13 ± 0.03*	0.24 ± 0.03**	0.33 ± 0.05**
Sperm motility (%)	93.7 ± 6.09	74.0 ± 5.48*	88.6 ± 3.17**	91.4 ± 5.02**
Sperm count (x10 <sup>6</sup> )	135.4 ± 10.1	83.5 ± 7.18*	107.3 ± 8.35**	125.0 ± 6.27**
TSA (%)	2.50 ± 0.49	3.01 ± 0.57	2.71 ± 0.65	2.05 ± 0.67
Live-dead ratio (%)	95.1 ± 8.42	96.5 ± 8.35	93.4 ± 6.06	93.7 ± 7.82
GSH (μg/ml)	0.35 ± 0.08	0.11 ± 0.06*	0.28 ± 0.03**	0.31 ± 0.05**

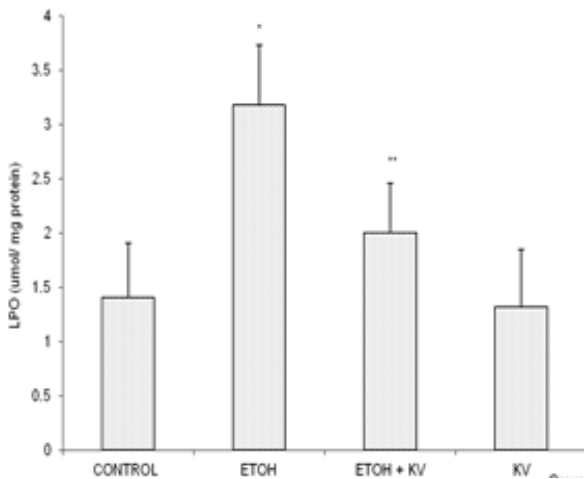
Values are the means ± S.D. of seven rats in each group. \* Significantly different from the control ( $p < 0.05$ )

\*\* Significantly different from ETOH ( $p < 0.05$ ) ETOH= Ethanol, KV= Kolaviron, TSA= Total Sperm Abnormalities,

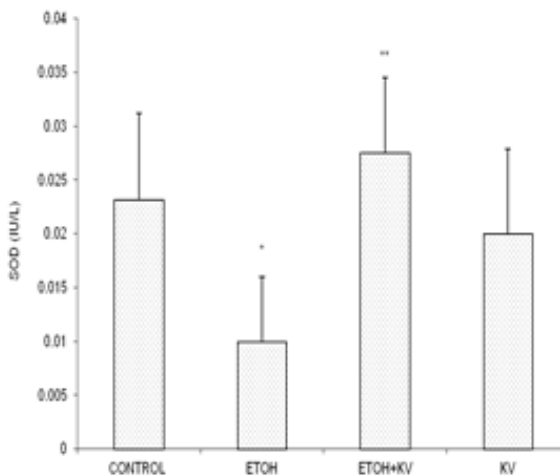
TPC= Testicular protein contents



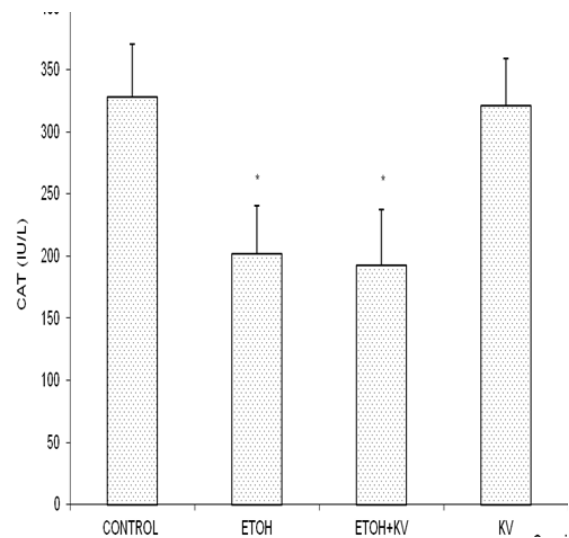
**Figure 2.** Effect of kolaviron on the activities of serum alkaline phosphatase (ALP) and Lactate Dehydrogenase (LDH) in rats following 21 days treatment with 45% ethanol.



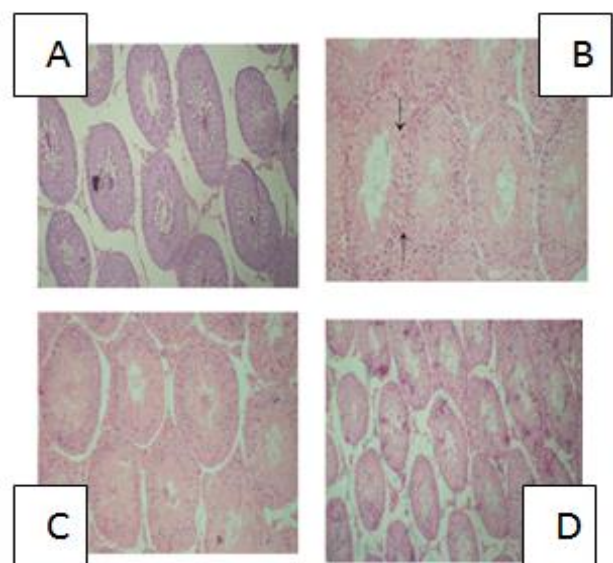
**Figure 3.** Effect of kolaviron on the levels of testicular Lipid Peroxidation (LPO) in rats following 21 days treatment with 45% ethanol. \* Significantly different from control ( $P < 0.05$ ), \*\* Significantly different from ETOH group ( $P < 0.05$ )



**Figure 4.** Effect of kolaviron on the activities of testicular SOD rats following 21 days treatment with 45% ethanol. \* Significantly different from control ( $P < 0.05$ ), \*\* Significantly different from ETOH group ( $P < 0.05$ )



**Figure 5.** Effect of kolaviron on the activities of testicular catalase in rats following 21 days treatment with 45% ethanol. \* Significantly different from control ( $P < 0.05$ )



**Figure 6.** Representative photomicrograph of testicular slides from control (A), Ethanol (B), Ethanol+KV (C) and KV-treated (D) rats, showing normal architecture (A), major distortion with slight necrosis(B), normal architecture with no lesion (C and D) X100 (H&E)



compared to controls. However, co-treatment with KV restored the ethanol-mediated decrease in the level of SOD to value that was statistically similar to controls (Figures 4 and 5). In figure 6, the histopathological observations in slides from ethanol-treated rats include distortion of architecture of testis, extensive necrosis and degeneration of seminiferous tubules and defoliation of spermatocytes. These observations were significantly attenuated in slides obtained from [Ethanol + KV] rats. The results of the histopathology were corroborated by biochemical changes in testis of the rats.

## DISCUSSION

The major findings of this study are that chronic ethanol-intoxication affected the spermatozoa of the rats adversely thereby resulting in low sperm count and marked reduction in sperm progressive motility. Furthermore, ethanol administration enhanced testicular lipid peroxidation and consequently decreased the enzymatic and non-enzymatic antioxidant indices in the animal. In addition, histopathological findings confirmed ethanol toxicity in the animals as shown by extensive necrosis, degeneration of seminiferous tubules and defoliation of spermatocytes in the slides. Importantly, kolaviron (KV) supplementation completely ameliorated the toxic assault imposed by ethanol in the animals.

Consequences of chronic alcohol ingestion may include gynecomastia, impotence, testicular atrophy, and loss of libido, as previously reported (Boyden and Pamerter, 1983; Buffum, 1983). Ethanol consumption also produces a significant decrease in the percentage of motility, concentration (Maneesh *et al.*, 2006) and normal morphology in human and animal spermatozoa (Nagy *et al.*, 1986). Martinez *et al.*, (2009) reported histological abnormalities in testicular tissue of alcoholic animals. These included intense intercellular spaces, irregular diameter of the seminiferous tubules, and high amount of necrotic cells in the lumen compared with controls. In addition, they showed that the epididymal sperm motility is decreased in ethanol treated rats. All the aforementioned observations were confirmed in the present study.

Peroxidation of polyunsaturated lipids in testis may produce structural alterations of biological membranes as well as lead to changes in membrane stability and function (Aitken *et al.*, 1989). Moreover, lipid peroxidation is believed to be responsible, at least in part, for hepatocellular damage due to drugs or alcohol intake (Adaramoye *et al.*, 2009). The possibility that chronic alcohol intake may cause testicular lipid peroxidation has been reported experimentally (Kasdallah-Grissa *et al.*, 2006) and was confirmed in this study. Thus, alcohol is an

established testicular toxin and its chronic use may lead to both reproductive and endocrine failure. Because testicular mitochondrial membranes are rich in polyunsaturated lipids, which exist in close proximity to peroxidation catalysts such as heme proteins and non-heme iron, they are a prime substrate for putative peroxidation injury. Moreover, studies by Jones and Mann (1977) have shown that the process of peroxidation of spermatazoa is accompanied by alterations in the spermatazoal structural membranes which include losses of phospholipids and spermatazoal motility. The increased formation of lipid peroxides and associated reactive oxygen species in testis of these animals adversely affected antioxidant parameters. Free radical scavenging enzymes such as SOD, CAT and glutathione peroxidase (GPx) are the first line of defence against oxidative injury. SOD scavenges superoxide ions and catalase converts H<sub>2</sub>O<sub>2</sub> to water. In this study, decreased levels of CAT and SOD as well GSH in alcohol treated rats were observed. The decreased SOD activity could be due to the oxidative inactivation of the enzyme as a result of excessive reactive oxygen species generated, while the depletion of GSH may be linked to its over utilization in detoxification process (Pigeolot *et al.*, 1990). GSH is a major non-protein thiol and plays a central role in coordinating the antioxidant defence process. It is involved in the maintenance of normal cell structure and function through its redox and detoxification reactions (Gueeri, 1995). GSH in association with GST, GPx and other antioxidant enzymes metabolizes and detoxifies toxic metabolites to less harmful agents before excretion and thereby protecting mammalian cells against oxidative damage. In the present study, we found that supplementation with KV significantly decreased the testicular lipid peroxidation and caused marked elevation of SOD, CAT and GSH. Furthermore, administration of KV to ethanol-treated rats improved the histomorphology of the testis. The histological alterations in testis of the treated rats were corroborated by changes in biochemical indices. The observed ameliorative effect of KV in this study may be due to its antioxidant properties (Adaramoye *et al.*, 2005), which may be involved in the scavenging of radical species generated by ethanol. From these findings, it can be inferred that KV positively modulates the antioxidant status and regenerates the testis of ethanol-treated rats to near normal.

In conclusion, supplementation of KV exerts a significant ameliorative effect against ethanol-induced testicular damage in the rats. The effect of KV may be attributed in part to its strong antioxidant effects *in vivo*. Since kolaviron is a biflavonoid complex consisting of GB1, GB2 and Kolaflavanone

in ratio 1:2:1, therefore further work is warranted to ascertain which of the fraction(s) (GB1, GB2 or Kolaflavanone) is/are responsible for the observed effect.

#### Acknowledgements

This study was partly supported by Senate Research Grant of University of Ibadan (SRG/COM/2010/7<sup>A</sup>) given to OAA. The authors thankfully acknowledge the technical assistance of Mr. Omoko Ejoro of the Department of Veterinary Reproduction, University of Ibadan, Nigeria.

#### REFERENCES

- Adaramoye, O.A., Farombi, E.O., Adeyemi, E.O. and Emerole, G.O. (2005). Inhibition of human low-density lipoprotein oxidation by flavonoids of *Garcinia kola* seeds. *Pak. J. Med. Sci.* 21: 331–339.
- Adaramoye, O.A. and Adeyemi, E.O. (2006a). Hepatoprotection of D-galactosamine-induced toxicity in mice by purified fractions from *Garcinia kola* seed. *Basic Clin. Pharmacol. Toxicol.* 98: 135–141.
- Adaramoye, O.A. and Adeyemi, E.O. (2006b). Hypoglycaemic and hypolipidaemic effects of fractions from kolaviron, a biflavonoid complex from *Garcinia Kola* in streptozotocin-induced diabetes mellitus rats. *J. Pharm. Pharmacol.* 18: 121–128.
- Adaramoye, O.A., Awogbindin, I. and Okusaga, J.O. (2009). Effect of kolaviron, a biflavonoid complex from *Garcinia kola* seeds, on ethanol-induced oxidative stress in liver of adult wistar rats. *J Med Food* 12: 584-590.
- Adaramoye, O.A., Adedara, I.A. and Farombi, E.O. (2010). Possible ameliorative effects of kolaviron against reproductive toxicity in sub-lethally whole body gamma-irradiated rats. *Exp. Toxicol. Pathol.* doi:10.1016/j.etp.2010.10.002
- Aebi H. (1974). Methods of Enzymatic Analysis: Catalase estimation. In: Bergmeyer HV, ed. New York: Verlag Chemic, 673-84.
- Aitken, R.J., Clarkson, J.S. and Fishel, S. (1989). Generation of reactive oxygen species, lipid peroxidation, and human sperm function. *Biol. Reprod.* 41: 183-197.
- Boyden, T. W., and Pamerter, R. W. (1983). Effects of ethanol on the male hypothalamic-pituitary-gonadal axis. *Endocr. Rev.* 4: 389–395.
- Buge, J.A. and Aust, S.D. (1978). Microsomal lipid peroxidation. *Methods In Enzymol.* 30: 302-310.
- Buffum, J. C. (1983). Pharmacosexology update: heroin and sexual function. *J. Psychoactive Drugs.* 15: 317–318.
- Fadem, B. H. (1993). Effects of postnatal exposure to alcohol on reproductive physiology and sexually dimorphic behavior in a marsupial, the gray short-tailed opossum (*Monodelphis domestica*). *Alcohol. Clin. Exp. Res.* 17: 870–876.
- Farghali, H., Williams, D.S., Gavalier, J. and Van Thiel, D.H. (1991). Effect of short-term ethanol feeding on rat testes as assessed by <sup>31</sup>P NMR spectroscopy, <sup>1</sup>H NMR imaging, and biochemical methods. *Alcohol Clin. Exp. Res.* 15:1018-1023.
- Gueeri, H. (1995). Influence on prolonged ethanol intake on the level and turnover of alcohol and aldehyde dehydrogenase and glutathione. *Adv. Exp. Med. Biol.* 23:12–14.
- Iwu, M.M., Igboko, O.A., Onwuchekwa, U. and Okunji, C.O. (1987). Evaluation of the anti-hepatotoxicity of the biflavonoids of *Garcinia kola* seeds. *J. Ethnopharmacol.* 21: 127–138.
- Iwu, M.M., Igboko, O.A., Okunji, C.O. and Tempesta, M.S. (1990). Anti-diabetic and aldose reductase activities of biflavanones of *Garcinia kola*. *J. Pharm. Pharmacol.* 42: 290–292.
- Jollow, D.J., Mitchell, J.R., Zampaglione, N. and Gillette, J.R. (1974). Bromobenzene induced liver necrosis: protective role of glutathione and evidence for 3,4 bromobenzene oxide as the hepatotoxic metabolite. *Pharmacol.* 11: 151-169.
- Jones, R. and Mann, T. (1977). Damage to ram spermatozoa by peroxidation of endogenous phospholipids. *J. Reprod. Fertil.* 50: 261-266.
- Kasdallah-Grissa, A., Mornagui, B., Aouani, E., Hammami, M., Gharbi, N., Kamoun, A. and El-Fazaa, S. (2006). Protective effect of resveratrol on ethanol-induced lipid peroxidation in rats. *Alcohol Alcohol.* 41: 236-239.
- Lans, C., Georges, K. and Brown, G. (2007). Non-experimental validation of ethno-veterinary plants and indigenous knowledge used for backyard pigs and chickens in Trinidad and Tobago. *Trop. Anim. Health Prod.* 39:375–385.
- Lee, C.K., Park, K.K., Lim, S.S., Park, J.H. and Chung, W.Y. (2007). Effects of the licorice extract against tumor growth and cisplatin-induced toxicity in a mouse xenograft model of colon cancer. *Biol. Pharm. Bull.* 30:2191–2195.
- Lowry, O.H., Rosebrough, N.J., Farr, A.L. and Randall, R.J. (1951). Protein measurement with the Folin phenol reagent. *J. Biol. Chem.* 193: 265–275.
- Maneesh, M., Dutta, S., Chakrabarti, A. and Vasudevan, D.M. (2006). Alcohol abuse duration-dependent decrease in plasma testosterone and antioxidants in males. *Indian J. Physiol. Pharmacol.* 50: 291–296.
- Martinez, M., Macera, S., de Assis, G.F., Pinheiro, P.F.F., Almeida, C.C.D., Tirapelli, L.F., Martins, A., Mello-Júnior, W., Padovani, C.R. and Martinez, F.E. (2009). Structural evaluation of the

- effects of chronic ethanol ingestion on the testis of *Calomys callosus*. Tissue and Cell. 41: 199–205
- McCord, J.M. and Fridovich, I. (1969). Superoxide dismutase, an enzymatic function for erythrocyte superoxide. J. Biol. Chem. 244: 6049-6055.
- Nagy, F., Pendergrass, P. B., Bowen, D. C., and Yeager, J. C. A. (1986). Comparative study of cytological and physiological parameters of semen obtained from alcoholics and non-alcoholics. Alcohol Alcohol. 21: 17–23.
- Pant, N. and Srivastava, S.P. (2003). Testicular and spermatotoxic effects of quinalphos in rats. J. Appl. Toxicol. 23: 271–274.
- Pigeolet, E., Corbisier, P., Houbion, A., Lambert, D., Michiels, C. and Raes, M. (1990). Glutathione peroxidase, superoxide dismutase and catalase inactivation by peroxide and oxygen derived radicals. Mech. Ageing Dev. 51: 283–297.
- Rezvanfar, M., Sadrkhanlou, R., Ahmadi, A., Shojaei-Sadee, H., Rezvanfar, M., Mohammadirad, A., Salehnia, A. and Abdollahi, M. (2008). Protection of cyclophosphamide-induced toxicity in reproductive tract histology, sperm characteristics, and DNA damage by an herbal source; evidence for role of free-radical toxic stress. Hum. Exp. Toxicol. 27: 901-910.
- Rosenblum, E.R., Gavaler, J.S. and Van Thiel, D.H. (1985). Lipid peroxidation: A mechanism for ethanol-associated testicular injury in rats. Endocrinology 116:311-318.
- Van Thiel, D.H., Gavaler, J.S., Eagon, P.K., Chiao, Y-B., Cobb, C.F. and Lester, R. (1980). Alcohol and sexual function. Pharmacol. Biochem. Behav. (Suppl) 13:125-129
- Wells, M.E. and Awa, O.A. (1970). New technique for assessing acrosomal characteristics of spermatozoa. J. Dairy Sci. 53: 227-232.
- Williamson, T. (1972). A comparison between the phosphatase and phenyl phosphate methods of alkaline phosphatase assay. Med. Lab. Technol. 29: 182–187.
- World Health Organization (1999). WHO Laboratory Manual for the Examination of Human Semen and Sperm-Cervical Mucus Interaction. Cambridge: Cambridge University Press.
- Zemjanis, R. (1970). Collection and evaluation of semen. In: Diagnostic and Therapeutic Technique in animal reproduction, 2<sup>nd</sup> edn In: Baltimore MD, ed. William and Wilkins company, 139-153.
- Zhu, Q.L., Gavaler, J.S. and Van Thiel, D.H. (1997). Ethanol effects on rat Sertoli cell functions: *in vitro* and *in vivo*. Alcohol Clin. Exp. Res. 21: 1409-1417.
- Zhu, Q., Meisinger, J., Emanuele, N.V., Emanuele, M.A., LaPaglia, N. and Van Thiel, D.H. (2000). Ethanol Exposure Enhances Apoptosis Within the Testes. Alcohol Clin. Exp. Res. 24: 1550-1556.
- Zimmerman, H.J. and Weinstein, B.S. (1965). Lactic dehydrogenase activity in human serum. J. Lab. & Clin. Med. 48: 607-609.