

Clinicopathological observations in experimental Peste Des Petit Ruminants virus and *Mannheimia Haemolytica* A:2 co-infection in goats

*Emikpe B.O and Akpavie S.O

Department of Veterinary Pathology, University of Ibadan, Ibadan, Nigeria

Summary: The experiment describes for the first time the clinicopathological features of the co-infection of Peste des petit Ruminants (PPR) virus and *Mannheimia haemolytica*, in goats. Twenty clinically healthy goats, six months of age were used. 15 goats were infected by intratracheal inoculation of 1ml of pure cultured $10^{6.5}$ TCID₅₀ PPR virus grown in Baby hamster kidney cell lines, and a week later, 1ml of pure culture (10^9 CFU) of *Mannheimia haemolytica* (MH)A2 to study its clinico-pathological features and five goats served as controls. The clinical signs were observed and two goats were euthanized at predetermined intervals for gross examinations, bacteriological, virological and histopathological investigations on tissues collected using standard techniques. The clinical signs were severe and the order of manifestation was anorexia, pyrexia, dyspnea, oculo-nasal discharge, recumbency and death. The lesions observed were severe fibrinous bronchointerstitial pneumonia and pleurisy with thickened alveolar septa, edema and neutrophilic infiltrations of the interstitium with giant cells. There was also marked erosive stomatitis and acute enteritis. The average percentage lung consolidation for the infection was 7.01% and the right lung was more affected ($p < 0.05$) while the overall mortality was 33.3%. MHA:2 and PPR virus were re-isolated from the lungs. The clinicopathological features observed showed that goats were susceptible to co-infection of PPR and Mannheimiosis which was severe and fatal. The data should help veterinarians and other medical experts to recognize cases of bacterial complicated viral infection and be informed of the approach to the treatment of such conditions.

Keywords: Pneumonia, West African Dwarf goats, Lung morphometry, Infection.

©Physiological Society of Nigeria

*Address for correspondence: banabis2001@yahoo.com; bo.emikpe@mail.ui.edu.ng Fax: + 234-28103043; Tel. (cell.): +234 80 6648 60 80; +601116689556

Manuscript Accepted: June, 2012

INTRODUCTION

The African small ruminant population is about 205 million sheep and 174 million goats representing approximately 17% and 31% of the world total, respectively (FAO 1990). In the last two decades, there has been a steady growth in goat production than sheep in most sub-Saharan countries (Ademosun, 1985).

In Nigeria with about 34.5 million goats and 22.1 million sheep, goats provide 30-36% of the total meat consumption annually and about 12.7% of the total agricultural gross domestic product (Ademosun, 1985). The major limitation to their production is the high incidence of infectious diseases with pneumonia being an important respiratory disorder in sub-Saharan Africa. Of these, Peste des Petit Ruminant Virus (PPRV) and *Mannheimia haemolytica* (MH) are the common causes of viral and bacterial

pneumonia in goats in the humid zone of Nigeria (Obi 1984a,b).

There were various reports on the patterns and types of respiratory pathology in small ruminants (Ikede, 1977; 1978, Ahmadu, 1996a,b) and the bacterial agents associated with the respiratory tract infection (Ojo and Obi, 1996; Raji *et al.*, 1999). The most significant bacteria associated with respiratory tract in goats include *Mannheimia haemolytica*, *Pasteurella multocida* and *Staphylococcus aureus* (Ikede, 1977). The role of the organism in the severity of some other viral infections of the respiratory tract (Brogden *et al.*, 1998) has been well established for Para influenza virus 3 infection (Fulton *et al.*, 2000), respiratory syncytial virus infection (Sharma and Woldehiwet, 1991), adenovirus infection (Davies *et al.*, 1982) and Bovine viral diarrhea (Ganheim *et al.* 2003) while the association of MH in most PPR outbreaks appears not

to have received sufficient attention (Emikpe, 2009, Emikpe *et al.*, 2010).

It is a known fact that most viral infections of epithelial cells of the respiratory tract, increase the adherence of *Mannhenina hemolytica*, *Pasteurella multocida* by expression of cell surface antigens associated with binding of potentially pathogenic bacteria and the bacterial adhesion to mucosal surfaces plays a major role in colonization and disease production. Other factors such as transportation, overcrowding, housing neonates and weaned animals together and other stressful conditions predispose animals to MH infection (Brogden *et al.*, 1998). MH being one of the resident nasal bacterial flora of goats (Emikpe *et al.*, 2009a) coupled with the devastating and endemic nature of PPR infection especially in goats (Emikpe and Akpavie 2010b), there had been frequent association of PPRV and *Mannheimia haemolytica*, in the pneumonia of small ruminants observed on the field, which made it necessary to study the sequence of the clinicopathological changes associated with experimental co-infection of PPRV and MH with a view of understanding the pathology of the co-infection in goat and the probable role of *Mannheimia haemolytica* in the pneumonic pathology associated with PPR as earlier speculated (Emikpe and Akpavie 2011).

MATERIALS AND METHODS

The study was carried out in small ruminant pens of the Veterinary Pathology Department, in the experimental animal unit of the Faculty of Veterinary Medicine, University of Ibadan.

Animals

Twenty clinically healthy West Africa Dwarf goats (WAD) obtained from a recognised breeding farm, six months of age, of average weight of 6kg were used for the experiment. There were equal number of males and females and were divided into two well partitioned pens. Group A had 15 goats (male:8, female:7) while 5 goats (male:2, female:3) served as control. They were conditioned for 14 days before the intervention and vital signs (rectal temperature, pulse and respiratory rates) were monitored daily to observe whether they remained afebrile and free of any clinical signs of diseases. Wheat bran and water were provided *ad libitum* daily. The nasal swabs of the animals were negative for *Mannheimia haemolytica* by cultural isolation prior to inoculation. The animals were also confirmed seronegative by Agar gel precipitation technique for antibody to peste des petit ruminants virus (PPRV) prior to inoculation. Adequate measures were taken to minimize pain or discomfort.

Inoculations and sample collection

The preparation of PPRV and MH inoculums was as described by Emikpe *et al.*, (2009b) and Emikpe and Akpavie (2010) respectively. Fifteen goats were infected intratracheally with 1ml of the pure culture of PPR virus grown in Baby hamster kidney cell line (BHK) with a titre of $10^{6.5}$ TCID₅₀ and a week later, 1ml of pure culture (10^9 CFU) of a 4 hour log phase culture of *Mannheimia haemolytica*A2 in brain in fusion broth while five uninfected control goats were inoculated intratracheally as earlier described by Emikpe and Akpavie (2011). The goats were then closely monitored for clinical signs. The animals that died and those that were euthanized at predetermined periods were necropsied. The goats were euthanised using intravenous injection of 90mg/kg of 6% Phentobarbitone sodium. The animals that died were necropsied but two animals were euthanised at predetermined days 1, 2, 3, 15, 26, 33, 48 and 55 days pi while two died on day 3, 15 and one on day 1pi of MH administration.

Samples from the oral mucosa, lungs, liver, spleen, mesenteric lymph nodes and intestine were collected in 10% buffered formalin, routinely processed and stained with haematoxylin and eosin for histological examination at x 40 of the light microscope. For the lung pathology, the degree of consolidation or pneumonia as a percentage of the total lung volume, was estimated as described by Odugbo *et al.*, (2004) while the histopathological changes were scored as described by Kumaret *al.*, (2004).

Microbiology

For virus isolation, a 10% suspension of homogenized tissue in F-13 medium without serum was centrifuged 3000rpm for 15minutes and the supernatant collected. The supernatant were inoculated into Vero and BHK cell lines and maintained in F-12 MEM supplemented with 5% fetal bovine serum. The cultures were incubated at 37⁰C and daily examined for appearance of cytopathic effect as earlier described by Emikpe *et al.*, (2009b).

For bacteriology, lung samples from the consolidated portions were collected from dead animals in brain heart infusion broths and were incubated for 24 hours at 37⁰C before being brought out for sub-culturing into the agar. Each goat had two bacterial culture plates (Blood Agar and MacConkey Agar). The characterization and identification of the isolates were carried out using standard methods as previously described by Quinn *et al.*, (1994).

Statistical Analysis

Data were expressed as mean \pm standard error of the mean (mean \pm SEM). Student T test was used to test for significant differences in the side of lung affected. Values of P < 0.05 were considered significant.

RESULTS

Clinical Features

There was gradual weight loss in all of the animals with a greater loss in the last two weeks of the experiment (Fig. 1). The infected goats also had slightly elevated temperature than the control with pyrexia of 40.4°C on day 12 pi (Fig. 2) while the respiratory rates were consistently higher in infected goats than control with tachypnoea between day 9 and 22 pi however, pi and the rest days pi were apparently similar in both the infected and control goats (Fig. 3).

Tables 1 showed the severity and timing of the clinical features in the course of the experiment, with severe clinical signs after the infection with MH. At 2 days pi the animals had serous nasal and lacrimal discharges with some, coughing after external tracheal irritations. The oral lesion was observed at 4 dpi. The lesions were erosion and scabs commonly observed in the inner aspect of the lips in five of the animals. These lesions were more pronounced at 10 dpi. The discharges observed progressed to mucoid and mucopurulent from 6dpi. Cough persisted throughout the course of the experiment with increased rate from 11 and 12 days pi. Diarrhoea and pneumonic stance characterized by arching of the back, was first noticed on day 8 pi and death was noticed two days after. All the animals that died in the course of the co infection died within 10 and 12 dpi. Scabs were noticed in all the animals at the commissures from 13 dpi while diarrhea which was later projectile persisted till 37 dpi. Marked emaciation was noticed on 28 dpi and this was very severe especially between 51 and 55dpi with less obvious clinical features during this period. Five goats died in all especially two weeks after infection with MH giving a mortality of 33%.

Microbiology

PPR virus was re-isolated from the homogenized tissue using both Vero and BHK cell lines with characteristic appearance of cytopathic effect as earlier described by Emikpe *et al.*, (2009b). MH was

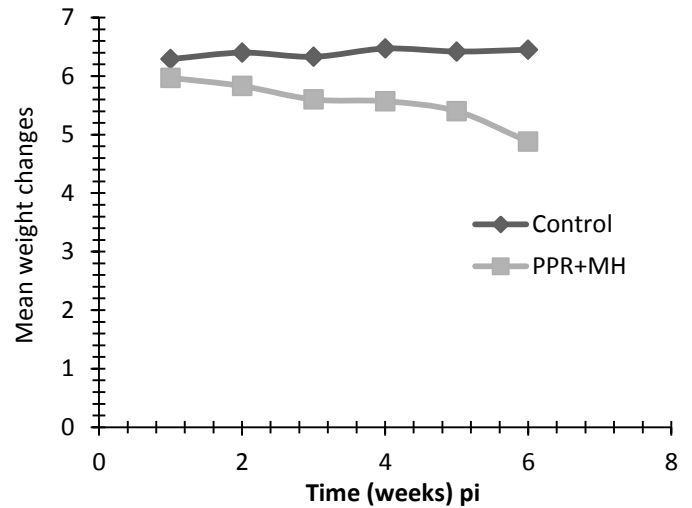


Fig 1: Weekly mean weights of goats infected with PPRV and MH

Table 1. Time of Occurrence of the Clinical Features in PPRV + MH Infection in West African Dwarf goats

Clinical features	Time of occurrence in days
Dullness and withdrawn	2-5
Pyrexia	5-6
Rough hair coat	2-7
Serous nasal discharge	2-8
Mucoid ocular discharge	6-44
Sneezing	2-10
Cough (occasional)	5-14
Cough paroxysmal	15-39
Change in faecal consistency	2-6
Diarrhoea	8-36
Oral lesion	4-9, 26-36
Oral lesion (Marked)	10-25
Oral scab	13-16
Death	-1, 12 and 15

also re-isolated from the consolidated portions of the lung samples collected from dead animals using standard methods as previously described by Quinn *et al.*, (1994).

Pathology:

The animals as at day 2 pi, were moderately emaciated with prominent ribs and pelvis. The mucosa of the lower lip had erosions of varying sizes ranging between 2-3mm in diameter while those of the nasal turbinate were hyperemic. The respiratory airway contained moderate amount of frothy extending from the trachea to the bronchioles. There was pulmonary congestion and oedema with focal

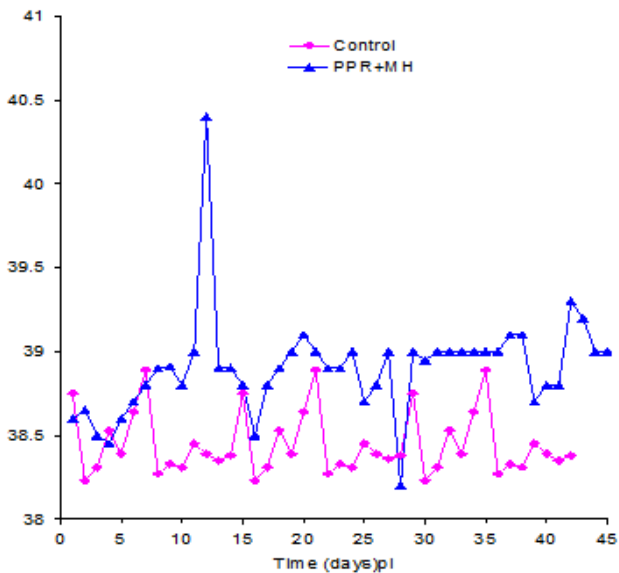


Fig 2: Temperatures of goats infected with PPRV and MH

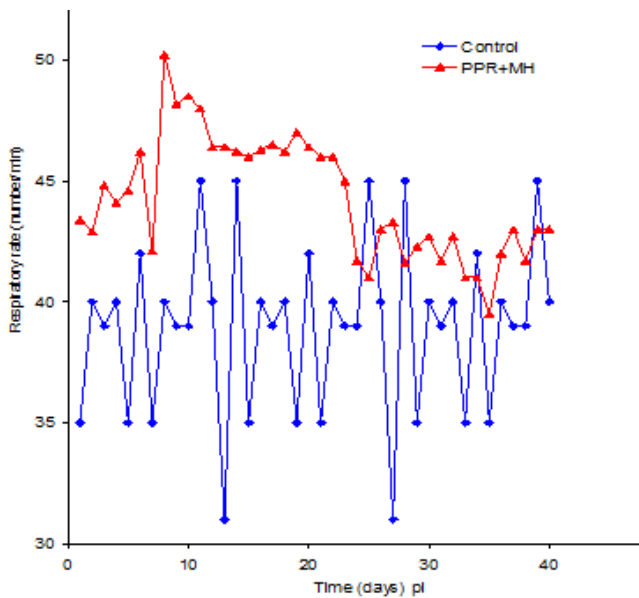


Fig 3: Respiratory rates of goats infected with PPRV and MH

consolidation of the anterior ventral portion of the cranial lobe on right lungs which showed prominent interlobular septae. The intestinal mucosa was markedly hyperemic with linear hemorrhages. On the day 3 pi, the euthanised animals showed more extensive labial erosions affecting the upper lips and the anterior aspect of the hard palate. There were scabs in the commissures. The turbinates were hyperemic while airways contained moderate amount of froth. There was also extensive consolidation affecting the whole cranial lobe, 85% of the middle lobe sparing the dorsal aspect, and the anterior portion of the caudal lobe of the right lung (Fig.4) in the two animals euthanized. In addition, one of the

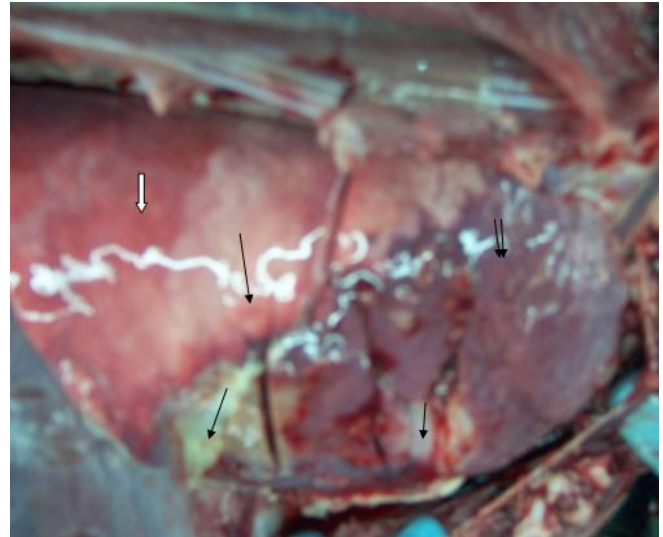


Fig 4: The lung of a goat infected with PPRV and MH showing marked hyperemia, consolidation and fibrinous deposits on the right cranial, middle and anterior ventral portion of the caudal lobe.

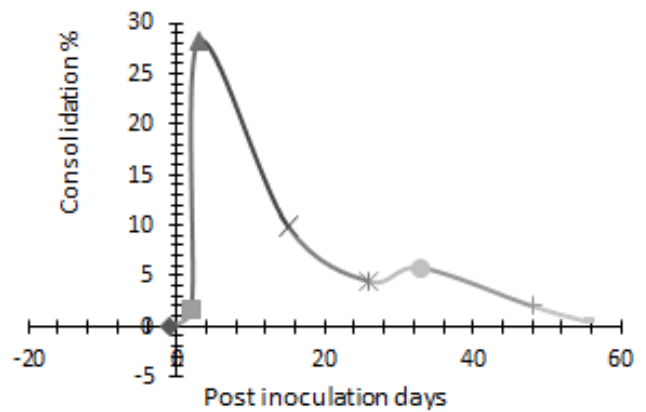


Fig 5: Pulmonary consolidation curve in experimental PPRV and MH infection in West African Dwarf goats

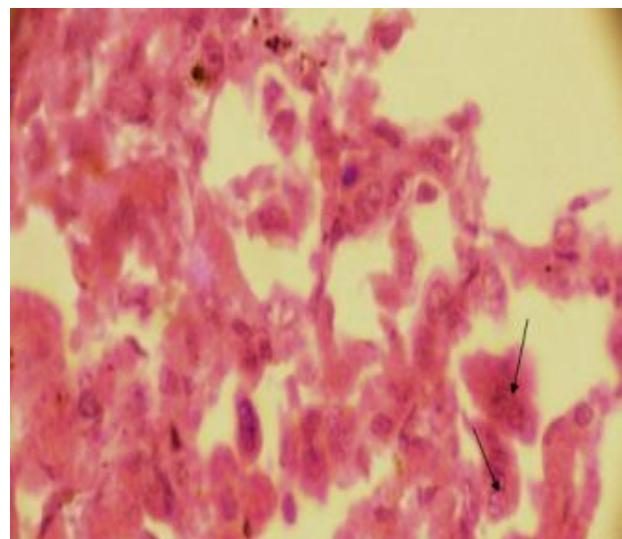


Fig 6: Photomicrograph of the lungs of a goat infected with PPRV and MH showing giant cells (arrow) H&E X 400

animals also had 75% of the cranial lobe of the left lung consolidated. At day 15 pi, the oral lesions were more severe. The respiratory lesions were similar in distribution and severity as those described at day 3 pi. The liver had diffuse areas of necrosis and the spleen was markedly enlarged. At day 26 pi, the oral erosions were extensive affecting the rostral aspect of the hard palate with a rim of hyperemia. About 25% of the cranial lobes of both lungs and the middle lobe of the right lung were consolidated especially at the ventral portions. The cranial, middle and anterior aspect of the caudal lobes of the right lung were attached to the rib cage by fibrin. The intestinal mucosa was hyperemic and showed linear congestion. At day 33 pi, although the lesions followed similar distributions as those seen on day 26 pi, the consolidation and adhesion to the rib cage with fibrin were more extensive. The consolidation affected between 30-40% of the cranial, middle and anterior aspect of the caudal lobes of the right lung tissue.

At day 48 pi, there were erosions of varying sizes 5mm-20mm in diameter on the mucous membrane of the hard palate and the lateral aspect of the cheeks and the tonsils were inflamed. The upper respiratory tract lesions were characterized by severe hyperemia with frothy exudate in the trachea-bronchial airway,

hyperemia and patchy consolidation of the cranial lobe, and middle lobe of the right lung. The left cranial lobe was 5% consolidated. The rest of the lungs were congested and oedematous with prominent interlobular septae. At day 55 pi, the lesions observed were similar to those of day 48 pi with erosions observed more on the tongue and the caudal aspect of the palate. The erosions were extensive and of varying sizes and between 2-5 mm in diameter.

Lung Consolidation

Fig. 5 shows the percentage pulmonary consolidation in experimental PPRV and MH infection. The lung consolidation curve revealed a significant peak on 3 days pi with a second but much lower peak on day 33pi. The average mortality rate was 33.33%; which was observed within 2 weeks of infection. This corresponded to the period of marked lung consolidation and MH bacterial count. The average consolidation for the experimental PPRV infection was 7.01%. Table 2 showed that more of the consolidation was observed in the right lung (5.21%) than in the left lung (1.8%) with the cranial and middle lobes of both lungs being more affected.

Table 2: Percentage pulmonary consolidation in experimental PPRV and MH infection in West African Dwarf goats

Serial numbers	Tag numbers	Post inoculation days	Left cranial	Left Pos cranial	Left caudal	Accessory	Right cranial	Right posterior cranial	Right middle	Right caudal	Total	Average
	%		5%	6%	32%	4%	6%	5%	7%	35%		
1.	290	-1	-	-	-	-	-	-	-	-	-	0
2.	753	2	-	-	-	-	1.6	-	-	-	1.6	1.7
3.	790	2	-	-	-	-	1.8	-	-	-	1.8	
4.	AK	3	3.85	4.5	6.4		5.7	4.75	5.95	7.0	38.15	28.23
5.	AD	3	-	-	-	-	5.4	4.5	4.9	3.5	18.3	
6.	AA	15	-	-	-	-	6	5	3.5	5.25	19.75	9.9
7.	291	15	-	-	-	-	-	-	-	-	-	
8.	757	26	0.75	0.9	-	-	1.8	1.25	1.05	-	5.75	4.45
9.	AL	26	0.5	0.6	-	-	0.6	0.75	0.7	-	3.15	
10	754	33	1.5	3.0	3.2	-	-	-	-	-	7.7	5.8
11	760	33	1.25	-	-	-	1.2	0.75	0.7	-	3.9	
12	292	48	0.25	-	-	-	1.2	0.75	1.75	-	3.95	2.0
13	295	48	-	-	-	-	-	-	-	-	-	
14	AO	55	-	-	-	-	0.6	0.25	-	-	0.85	0.55
15	AM	55	0.25	-	-	-	-	-	-	-	0.25	
	Total		8.35	9.0	9.6		25.9	18.0	18.55	15.75	105.15	7.01

LEFT LUNG AVERAGE 1.8%

RIGHT LUNG AVERAGE 5.21%

Histopathology

Between 3dpi and 15dpi, there was marked suppurative broncho-interstitial pneumonia characterized by tissue necrosis, and mucopurulent exudates in tissues and bronchioles. The pleura and the interlobular septae were thickened with fibrin deposit and neutrophilic infiltration. Giant cells were seen in the alveoli (Fig.6). There was villous atrophy and matting and submucosal necrosis while the lamina propria of the intestine was infiltrated by lymphocytes and syncytial cells. There was severe splenic depletion. Between 26dpi and 55dpi, there was pulmonary congestion and oedema with mild broncho-interstitial lympho-neutrophilic infiltration. There was also hyperplasia of the bronchial associated lymphoid tissue. The intestinal and splenic lesions were also severe.

DISCUSSION

This study showed for the first time the clinicopathological features of the coinfection of serotype 2 MH with a lineage 1 variant of PPRV. The time occurrence of the clinical features of PPRV with MH infection in this study revealed oral lesion, mortality, and diarrhoea in the first fifteen days. These observations were different from those of Couacy-Hymann *et al.* (2007b) who infected their animals with PPRV lineage 1 alone and did not report diarrhoea, oral lesions and mortality in the two weeks of their study. The clinical features in this study occurred much earlier when compared with that of PPR virus infection (Emikpe and Akpavie 2011) with the oral lesion being observed 4 days pi as against 16 days pi, diarrhoea on 8 days pi as against 21 days pi and mortality between 6- 12 days pi as against 42-44 days (Emikpe and Akpavie 2011).

The time occurrence of some of the clinical features in this investigation was similar to the sequence of events with lineage 2 and 4 of PPRV alone (Couacy-Hymann *et al.* 2007b) which possibly explain the accentuation of virulence of the PPRV used by MH giving a mean survival time of 10 days. This further corroborated the fact that the mortality associated with PPRV infection with the Nigerian isolate, MH as observed in the respiratory tract (Emikpe and Akpavie 2011).

The accentuation of virulence with severe clinical signs and lesions as observed in this study was similar to the observation of Couacy-Hymann *et al.*, (2007) with reactivation of heartwater disease in course of experimental PPR virus infection in goats.

The outstanding pathology in this co-infection was found in the lungs as the peak consolidation was in 3 days pi with marked fibrin deposits on the pleura and

this corresponded with 10 days post inoculation with PPRV which is a period of marked immunosuppression associated with PPRV (Rajak *et al.*, 2005).

The peak consolidation observed in this study occurred after bacterial challenge and may be associated with virulence of the bacteria strain used as earlier described by some workers (Odugbo *et al.*, 2004 a,b) and the immunosuppression associated with reduced efficiency of the alveolar macrophages in the bacterial clearance (Rajak *et al.*, 2005) which allow for the maximum invasion of the bacterial agent.

The consolidation observed had marked fibrin exudation associated with leukotoxin produced by MH which enhances neutrophil mediated damage of endothelial cells, pulmonary vascular thrombosis and fibrin exudation (Maheswaran *et al.*, 1993). The pattern of pneumonia was broncho-interstitial in nature and more of the lobules and lobes were involved. These observations were similar to that reported by Grubor *et al.* (2004) in single MH infection except for the presence of lymphocytes and giant cells which could be attributable to the viral involvement. The first peak of pneumonia recorded corresponded with the logarithmic increase in the nasal bacterial count (Emikpe and Akpavie 2010c) which is a reflection of an increase in bacterial colonization of the airways as a result of reduced mucociliary clearance and alveolar macrophage phagocytosis as a result of the damage caused by the virus especially during the first two weeks. The second peak of the lung consolidation observed in this study was lower than the first; this may be associated with resistant pattern exhibited by the survivors with patchy or focal consolidation and the pattern of cellular infiltration was interstitial in nature as earlier described Emikpe and Akpavie (2010a).

The average lung consolidation due to experimental PPRV and MH infection was 7.01% with the average mortality rate of 33.33% which occurred in the first two weeks pi, the period that also corresponds with the phase of more pneumonic lesions. This further buttressed the fact that the fatality of Nigerian strain of PPRV may be due to secondary bacterial complication (Emikpe and Akpavie, 2011). The weight loss observed in the course of this investigation revealed a relationship between pulmonary tissue damage and weight loss as earlier observed in pigs (Ostanello *et al.* 2007).

In conclusion, this study showed that the association of the two agents results into very fulminating disease with severe pulmonary, oral and enteric lesions and the reason behind these severe lesions may not be unconnected with the immunosuppressive effect of PPR virus and the bacterial complications, however the specific

bacterium/bacteria involved in the severe oral and enteric lesions observed needed to be further elucidated.

Acknowledgments.

The efforts of the staff of histopathology unit of Department of Veterinary Pathology, University of Ibadan especially Ibekwe C. Mpama, Ambrose Nwagbara and Augustine Joseph who prepared the slides are appreciated.

REFERENCES

Ademosun AA. (1985). Contributions of research to small ruminants production in Nigeria.in Adu IF, Osinowo, OA Taiwo BBA Alhassan WS Eds Small ruminant production in Nigeria held in Zaria Nigeria 6-10th October NAPRI Shikapp 18-34

Ahmadu B (1996a). Fatal diseases of goats diagnosed at necropsy in Zaria-Nigeria. *Bulletin of Animal Health and Production in Africa.* 44 115-116.

Ahmadu B. (1996b) Incidence of caprine pneumonia observed at post mortem in samaru Zaria-Nigeria.*Bulletin of Animal Health and Production in Africa.* 44 123-124.

Brogden KA, Lehmkuhi HD and Cutlip RC. (1998). *Pasteurella haemolytica* complicated respiratory infections in sheep and goats. *Veterinary Research*, May – Aug. 29(3-4): 233 – 54.

Couacy-Hymann E, Bodjo C, Danho T, Libeau G and Diallo A. (2007b). Evaluation of the virulence of some strains of peste des petits ruminants virus PPRV in experimental infected West African dwarf goats. *The Veterinary Journal* 173, 178-183

Davies DH, Herceg M, Jones BAH. and Thurley D.C. (1981a).The pathogenesis of sequential infection with Parainfluenza virus type 3 and *Pasteurella haemolytica* in sheep. *Veterinary Microbiology* 6 173-182

Davies DH., Herceg M and Thurley DC. (1982). Experimental infection of lambs with an Adenovirus followed by *Pasteurella haemolytica*. *Veterinary Microbiology* 7: 369-381

Emikpe BO (2009).The role of *Mannheimia haemolytica* (MH) in the pathology of experimental *Peste Des Petits Ruminants Virus* (PPRV) infection in West African Dwarf goats. PhD thesis University of Ibadan

Emikpe BO, Oyero OG and Akpavie SO (2009a). The Isolation and antibiogram of aerobic bacterial nasal flora of apparently healthy West African Dwarf Goats. *Revue d'Elevage et de Medecine Veterinaire des Pays Tropicaux* 62: (1):17-21

Emikpe BO, Oyero OG and Akpavie SO (2009b). Comparative susceptibility of baby hamster kidney and Vero cell line to *Peste des petits*

ruminants Virus (PPRV). *Bulletin of Animal Production and Health in Africa* 57 (3): 245-250

Emikpe BO and Akpavie SO (2010a). The pattern of distribution of pneumonia in experimental *Peste des petits ruminants Virus* and/or *Mannheimia haemolytica* infection in West African Dwarf goats. *International Journal of Morphology* 28(2): 563-568

Emikpe BO and Akpavie SO (2010b). The prevalence of *Peste des petits ruminants virus* antibodies in goats from selected rural and urban communities in Ibadan Nigeria. *Bulletin of Animal Production and Health in Africa* 58 (2):147-153

Emikpe BO and Akpavie SO (2010c). The nasal bacterial flora changes in experimental *Peste des petits ruminants virus* and its coinfection with *Mannheimia haemolytica* in goats. *Bulletin of Animal Production and Health in Africa* 58 4: 296 – 302

Emikpe BO, Sabri YM, Akpavie SO, Zamri Saad M (2010). Experimental infection of *Peste des petits ruminants virus* and *Mannheimia haemolytica* A2 in goats: Immuno-localisation of *Mannheimia haemolytica* antigens (DOI: 10.1007/s11259-010-9425-y) *Veterinary Research Communications* 34 (7): 569-578

Emikpe BO and Akpavie SO (2011). The clinicopathologic effects of *Peste des petits ruminants virus* in experimentally infected West African dwarf goats. I *Small ruminant Research* 95 (2, 3): 168-173 doi:10.1016/j.smallrumres.2010.09.009

Food and Agriculture Organization of the United Nations (FAO) (1990). Production Yearbook. Vol. 44. FAO, Rome. 283 pp.

Fulton RW, Purdy CW, Confer AW, Saliki JT, Loan RW, Briggs RE, Burge LJ (2000a). Bovine viral diarrhoea viral infections in feeder calves with respiratory disease: interactions with *Pasteurella* spp., parainfluenza-3 virus, and bovine respiratory syncytial virus. *Canadian Journal of Veterinary Research* 64:151-159

Ganheim C, Hulten C, Carlsson U, Kindahl H, Niskanen R, Waller KP. (2003). The acute phase response in calves experimentally infected with bovine viral diarrhoea virus and/or *Mannheimia haemolytica*. *Journal of Veterinary Medicine B;* 50(4):183–90.

Grubor, B., Gallupa, J M, Ramí-rez-Romero, R., Bailey, T B. Crouchd, E C. Brogdene, K, Ackermann, MR. (2004).Surfactant protein D expression in normal and pneumonic ovine lung. *Veterinary Immunology and Immunopathology* 101 235–242

Ikede, BO. (1977). The Pattern of respiratory lesions in goats and sheep in Nigeria. 1. Lesions in

- goats. *Bulletin of Animal health and production in Africa*. 25: 49–59.
- Ikede, BO. (1978). The Pattern of Respiratory Lesions of Goats and Sheep in Nigeria Part II – Lesions in Sheep. *Bulletin of Animal Health and Production in Africa* 26: 2, 172 – 185.
- Kumar P, Tripathi BN, Sharma AK, Kumar R, Sreenivasa BP, Singh RP, Dhar P, Bandyopadhyay SK, (2004) Pathological and immunohistochemical study of experimental *Peste Des Petits Ruminants* virus infection in goats. *Journal Veterinary Medicine B*. 51, 153-159
- Maheswaran, SK., Kannan, MS, Weiss, DJ, Reddy, KR, Townsend, EL, Yoo, HS, Lee, BW and Whiteley LO. (1993). Enhancement of neutrophil-mediated injury to bovine pulmonary endothelial cells by *Pasteurella haemolytica* leukotoxin. *Infection and Immunity* 61: 2618 – 2625.
- Obi TU. (1984a). Clinical and epidemiological studies on PPR in sheep and goats in Southern Nigeria. Ph.D Thesis, University of Ibadan.
- Obi TU. (1984b). Respiratory viral infections in goats in Nigeria with emphasis on peste des Petits Ruminants Les maladies de la chevre, Niort (France), 9-11 october INRA publication.
- Odugbo MO, Odama LE, Umoh JU and Lombin LH. (2004a). The comparative pathogenicity of strains of eight serovars and untypeable strains of *Mannheimia haemolytica* in experimental pneumonia of sheep. *Veterinary Research* 35: 661-669
- Odugbo MO, Okpara JO, Abechi SA and Kumbish PR. (2004b). An outbreak of pneumonic pasteurellosis in sheep due to *Mannheimia (Pasteurella) haemolytica* serotype 7. *The Veterinary Journal* 167: 214-215
- Odugbo MO, Odama LE, Umoh JU and Makinde AA. (2003) Serotypes of *Pasteurella haemolytica* from pneumonic lungs of sheep in Northern Nigeria. *Small Ruminant Research* 48:239-243
- Ojo MO, Obi TU. (1996). Respiratory diseases of goats. *Tropical Veterinarian* 14: 85-99
- Ostanello F, Dottori M, Gusmara C, Leotti G and Sala V (2007) Pneumonia Disease Assessment using a Slaughterhouse Lung-Scoring Method. *Journal Veterinary Medicine Series A* 54, 70–75
- Quinn PJ, Carter ME, Markey B and Carter GR. (1994). Bacterial pathogens: microscopy, culture and identification in Clinical Veterinary Microbiology. Wolfe publishing London 21-60
- Rajak KK., Sreenivasa, BP, Hosamani M, Singh RP, Singh SK, Singh RK. and Bandyopadhyay SK. 2005: Experimental studies on immunosuppressive effects of peste des petits ruminants (PPR) virus in goats. *Comparative Immunology, Microbiology and Infectious Diseases*. 28, 287–296.
- Raji MA, Rodgers D, Natala AJ and Halle PD. (1999). A survey of the aerobic bacterial agents associated with ovine pneumonia in Zaria Kaduna state. *Nigerian Veterinary Journal* 20 1 75-81
- Sharma R. and Woldehiwet Z. (1990). Increase susceptibility to *Pasteurella haemolytica* in lambs infected with Bovine respiratory syncytial virus. *Journal of Comparative Pathology* 103: 411-420